UNIVERSIDADE DE SÃO PAULO
FACULDADE DE ODONTOLOGIA DE BAURU

GABRIELA MANAMI NATSUMEDA

Dentoskeletal and tegumental changes in individuals with normal occlusion after a 40-year follow-up

Alterações dentoesqueléticas e tegumentares em indivíduos com oclusão normal após 40 anos de acompanhamento

BAURU
2018

GABRIELA MANAMI NATSUMEDA

Dentoskeletal and tegumental changes in individuals with normal occlusion after a 40-year follow-up

Alterações dentoesqueléticas e tegumentares em indivíduos com oclusão normal após 40 anos de acompanhamento

Dissertação constituída por artigo apresentada a Faculdade de Odontologia de Bauru da Universidade de São Paulo para obtenção do título de Mestre em Ciências no Programa de Ciências Odontológicas Aplicadas, na área de concentração Ortodontia.

Orientadora: Profª. Drª. Daniela Gamba Garib Carreira

BAURU

2018

Natsumeda, Gabriela Manami

Dentoskeletal and tegumental changes in individuals with normal occlusion after a 40-year follow-up / Gabriela Manami Natsumeda – Bauru, 2018.

70p. : il. ; 31cm.

Dissertação de Mestrado – Faculdade de Odontologia de Bauru. Universidade de São Paulo

Orientadora: Profª. Drª. Daniela Gamba Garib Carreira

Comitê de Ética da FOB-USP
Protocolo nº: **71634917.5.0000.5417**
Data: 23 de Outubro de 2018

FOLHA DE APROVAÇÃO

DEDICATÓRIA

Dedico este trabalho com todo amor e gratidão aos meus amados avós, ***Toshihide, Massako, Hiroshi e Tsuneko****, que são meus maiores exemplos de determinação, sabedoria e humildade. Minha eterna admiração.*

AGRADECIMENTOS

Agradeço à Deus...

...o grandioso "kamisama", pela saúde, pela minha família, por todas as oportunidades concedidas, por iluminar meu caminho e minha mente, pela paciência nos momentos difíceis e pelas pessoas incríveis que cruzaram meu caminho.

Agradeço especialmente:

*Aos meus pais, **Takako e Mauro**:*

Vocês sempre, e digo SEMPRE mesmo, me incentivaram a estudar e correr atrás dos meus sonhos, me apoiando e não medindo esforços. Tiveram que "tirar os filhotes debaixo das asas" para nos proporcionar a melhor formação e oportunidade de estudar nos melhores colégios. Obrigada por serem quem são, por serem pais maravilhosos e por nos amar incondicionalmente!

***Mãe**, não preciso nem dizer o quanto a senhora é inspiração para mim. Me ensinou a ter força e perseverança, a ser grata e ver o lado positivo de tudo, mesmo quando as coisas estão difíceis. Me ensinou a humildade, generosidade e empatia. A senhora é o meu maior exemplo de como ser uma mulher guerreira e extremamente forte, sem perder sua delicadeza. Sou eternamente grata por tudo que me proporcionou!*

***Pai**, meu herói! Obrigada por toda preocupação, carinho, incentivo e força. Sempre com muita sabedoria, soube acalmar meus momentos de desespero e tristeza. O senhor sempre me incentiva ter muita dedicação e determinação em tudo o que faço, com seus ensinamentos, por exemplo, de como devemos por em prática o "CHA: conhecimento, habilidade e atitude" para alcançar sucesso. Não tenho palavras para expressar minha gratidão!*

*Aos meus irmãos, **Bruno e Akira**, muito obrigada por todo amor, carinho e cumplicidade. Obrigada por toda força, conselhos e momentos. Sem vocês seria tudo mais difícil. Sei que posso contar sempre com vocês, independente da dificuldade.*

*À **Família Okada e Natsumeda**, obrigada pela paciência e apoio em todos esses anos fora de casa e longe de todos. Meu agradecimento em especial à **Batian Massako, Keiko Batian, Tio Massuo, Tia Terumi e Mhai**, que me acolheram em Bauru e não mediram esforços para me ajudar e me sentir em casa. Obrigada **Tia Terumi** por sempre tratar eu e Tika como verdadeiras filhas, minha gratidão será eterna.*

*À minha roomate, **Tika**. Sei que conviver comigo não é fácil, por sermos tao diferentes. Mas nosso sonho de morar juntas se tornou realidade e eu não tenho como te agradecer pela paciência e amizade nesses 7 anos de convivência. Tenho muita admiração pela pessoa incrível que você é!*

*Ao meu amado **Lucas Cambiaghi**. Obrigada por todos os momentos ao seu lado, por toda paciência e companheirismo. Obrigada por sempre me incentivar e apoiar. Obrigada por ser meu ombro amigo e meu chão quando as coisas estão difíceis. Obrigada principalmente pelo seu amor!*

Obrigada por tudo família!
Amo muito vocês!

Agradeço, com muito carinho e admiração,

*À minha orientadora, **Drª Daniela Garib.***

Obrigada por confiar e dividir comigo este projeto tão especial! Obrigada pelos ensinamentos, orientação e paciência.

Sou fã da sua serenidade e da maneira como ensina a Ortodontia. A senhora encanta qualquer um com sua didática, clareza e maestria.

Serei eternamente grata por ter tido a honra de ser sua orientada, e me sinto muito privilegiada por tantos conhecimentos adquiridos!

Muito obrigada por tudo, Professora!

Agradeço...

*À **Faculdade de Odontologia de Bauru – Universidade de São Paulo** por me acolher desde 2012 e por todo conhecimento, experiência e recordações.*

*À **FAPESP, número de processo 2017/11215-9**, pela concessão da bolsa de estudos.*

*Ao respeitado **Professor Guilherme Janson**, pela dedicação, paciência e preocupação com a minha formação e aprendizado. Obrigada por me ensinar a ser uma profissional crítica, responsável e organizada. Obrigada por compartilhar conosco tantos conhecimentos.*

*Aos Professores: **Dr. José Fernando Castanha Henriques, Dr. Arnaldo Pinzan, Dr. Marcos Roberto de Freitas e Dr. Renato Rodrigues de Almeida**, por todos os ensinamentos e orientações.*

*Ao **Professor José Roberto Pereira Lauris**, pela paciência e apoio em cada reunião, para que eu conseguisse realizar a estatística desse trabalho. Muito obrigada!*

*Aos **funcionários do departamento**, por toda ajuda, dedicação e paciência. **Cléo**, obrigada por sempre estar presente, me ajudando sem medir esforços nas dificuldades da clínica! **Verinha**, obrigada pela paciência sempre que corri até você quando precisava de alguma*

coisa ou para tirar alguma dúvida! ***Sérgio****, obrigada por todos os conhecimentos e dicas clínicas que compartilhou comigo!* ***Wagner****, obrigada pela amizade e boas conversas!* ***Bonné****, obrigada por sempre estar disposto a ajudar com qualquer problema sem medir esforços.*

À minha ***banca examinadora*** *da dissertação do Mestrado, por aceitarem o convite de participação e pelas contribuições para aprimorar este trabalho, através de preciosas críticas e sugestões.*

Aos meus Professores do Curso de Especialização da PROFIS – USP, ***Professor Leopoldino Capelozza Filho, Professor José Capelozza, Professor Guilherme Capelozza e Professor Fábio Guedes****. Muito obrigada por me ensinarem Ortodontia de forma tão apaixonante! Obrigada por toda paciência e conhecimentos transmitidos.*

Aos amigos do Doutorado, ***Áron, Camila, Carol, Diego, Déborah, Fabíola, Felícia, Lorena, Ludmilla, Paula, Raquel e Wilana****, pela boa convivência e pela troca de conhecimentos. Agradeço em especial à* ***Camila e Felícia****, que não mediram esforços para me socorrer, me acalmar e torcer por mim e para a pesquisa dar certo. Obrigada pela amizade, pelas orientações e conselhos! Agradeço também, ao* ***Áron****, orientador oficial de toda a turma do Mestrado 2017! Não tenho palavras pra agradecer sua paciência e dedicação com a nossa turma. Você realmente foi essencial para o sucesso de todos nós!*

À minha querida turma do Mestrado...

Cinthya, Cristina, Danelin, Jéssica, José, Marcelo, Maria Cláudia, Maria Pia, Olga, Rodrigo e Silvio.

Que turma incrível, sério! Com certeza foi muito mais fácil enfrentar a rotina pesada e as dificuldades com vocês por perto. Foi um enorme prazer conviver com vocês nesses dois anos, e serei eternamente grata pela amizade, risadas, apoio, respeito e companheirismo.

***Cin**, obrigada pelas risadas, pelos momentos de descontração e bom humor, nossa musa fitness e blogueirinha! **Cris**, obrigada por sempre me acalmar e dizer palavras de conforto. **Danelinda**, obrigada pela amizade e conversas gostosas, principalmente durante as monitorias! **JessiMaluca**, obrigada por ser boba comigo, pelas risadas e pelas brincadeiras idiotas! **Cheo**, obrigada por ser tão amigo e companheiro, principalmente nos treinos da academia! **Marcelo**, obrigada por me dar a oportunidade de te conhecer melhor e pela amizade que criamos nesses 2 anos! **Maquinha**, minha dupla, obrigada pela parceria de sempre, pelas risadas e pelo apoio, você com certeza foi minha mãezona nesse mestrado! **Piazinha**, sua alegria e bom humor sempre me fizeram ficar feliz e mais leve, muito obrigada pelas boas risadas e por me ensinar espanhol! **Olguita**, muito obrigada por sempre me acalmar e pela paciência que teve comigo cada vez que te mandava mensagem desesperada com alguma coisa! **Silvineo**, monstrão! Muito obrigada pela paciência, pelas boas risadas e por sempre descontrair o ambiente com seu jeito leve de viver.*

*E finalmente, agradeço especialmente ao meu parceiro e irmão, **Rodrigo**. Não tenho palavras pra te agradecer. Você me acalmou nos meus momentos de maior desespero, de maior desanimo e celebrou comigo cada conquista e alegria. Se tornou realmente um irmão, alguém que eu realmente posso contar. Muito obrigada, de coração, por toda paciência que teve comigo (tenho certeza que foi muita), companheirismo e amizade!*

A todos aqueles que de alguma maneira contribuiram para a realização desta etapa e sonho...

MUITO OBRIGADA!

"Dificuldades preparam
pessoas comuns para destinos extraordinários."

C. S. Lewis

ABSTRACT

ABSTRACT

DENTOSKELETAL AND TEGUMENTAL CHANGES IN INDIVIDUALS WITH NORMAL OCCLUSION AFTER A 40-YEAR FOLLOW-UP

Introduction: Craniofacial growth and development is a continuous process that determines maturational changes throughout life. **Objectives:** The aim of this study was to evaluate cephalometric changes in individuals with normal occlusion from 17 years of age to the seventh decade of life. **Methods:** The sample comprised lateral cephalograms of 21 subjects with normal occlusion (11 males, 10 females), taken at 17 (T1) and 61 years of age (T2), which were digitized and measured using Dolphin Imaging 11.0 software. Anteroposterior and vertical maxillomandibular relationship, dentoalveolar and tegumental changes were analyzed. The interphase comparison was performed using paired t tests. Sexual dimorphism was evaluated using t tests. **Results:** A significant anterior displacement of the maxilla and mandible was observed between T1 and T2 time points. An increase of the ramus height, a counterclockwise rotation of the occlusal, palatal and mandibular planes, and a decrease of the upper facial height were observed during maturational process. Maxillary first molars tipped mesially and extruded. Soft tissue changes with aging were a decrease of the nasolabial angle, upper and lower lip retrusion and an increase of the soft-tissue chin thickness. A decrease of the maxillary incisor exposure and upper lip thickness was also observed. Sexual dimorphisms in the mandibular anteroposterior displacement and rotation were found. In males, a protrusion and a counterclockwise rotation of the mandible was found with a decrease in the overjet. In females, a mandibular clockwise rotation and a backward displacement of the chin were noted. A greater retrusion of the upper and lower lips and a greater increase of the soft chin thickness were observed in males. **Conclusion:** Aging changes were more intense in the soft tissue compared to the skeletal and dentoalveolar structures. An expressive sexual dimorphism for craniofacial changes was observed during the maturational process.

Key words: Normal occlusion, cephalograms, adults, maturation, aging.

RESUMO

RESUMO

ALTERAÇÕES DENTOESQUELÉTICAS E TEGUMENTARES EM INDIVÍDUOS COM OCLUSÃO NORMAL APÓS 40 ANOS DE ACOMPANHAMENTO

Introdução: O crescimento e desenvolvimento craniofacial é um processo continuo que determina alterações maturacionais durante toda a vida. **Objetivos:** O objetivo deste estudo foi avaliar alterações cefalométricas em individuos com oclusão normal dos 17 anos de idade até a sétima década de vida. **Materiais e métodos:** A amostra foi composta por telerradiografias de 21 individuos com oclusão normal (11 homens, 10 mulheres), tomadas aos 17 (T1) e 61 anos de idade (T2), que foram digitalizadas e medidas usando o software Dolphin Imaging 11.0. Alterações das relações anteroposterior, vertical, dentoalveolar e tegumentares foram analisadas. A comparação interfase foi feita usando o teste t pareado. O dimorfismo sexual foi avaliado usando o teste t. **Resultados:** Um significante deslocamento anterior da maxila e mandibula foi observado. Um aumento da altura do ramo, uma rotação anti-horária dos planos oclusal, palatino e mandibular, e uma redução da altura facial superior foram observadas durante o processo maturacional. Os primeiros molares superiores mesializaram e extruíram. Alterações tegumentares com o envelhecimento foram a redução do ângulo nasolabial, retrusão dos lábios superior e inferior e um aumento da espessura do mento. Uma diminuição da exposição dos incisivos superiores e da espessura do lábio superior foi observada. Dimorfismo sexual no deslocamento anteroposterior e rotação mandibular foi encontrada. Nos homens, uma protrusão e rotação anti-horária da mandibula foi observada com uma redução do overjet. Nas mulheres, rotação horária mandibular e deslocamento para trás do mento foi notado. Uma maior retrusão dos lábios superior e inferior e maior aumento da espessura do mento mole foi observada nos homens. **Conclusões:** As alterações com o envelhecimento foram mais intensas nos tecidos moles comparadas às estruturas dentoesqueléticas. Um expressivo dimorfismo sexual para as alterações craniofaciais foi observado durante o processo de maturacional.

Palavras-chave: Oclusão normal, telerradiografias, adultos, maturação, envelhecimento.

LIST OF ILUSTATIONS

Figure 1 - A-B: Lateral cephalograms of a man at T1 (17 years) and T2 (61 years); C-D: Lateral cephalograms of a woman at T1 (17 years) and T2 (61 years 37

Figure 2 - Superimposition of average of all subjects' profiles from T1 to T2 (red line, T1, black line, T2) 38

Figure 3 - Superimposition of average male profiles from T1 to T2 (red line, T1, black line, T2) 39

Figure 4 - Superimposition of average female profiles from T1 to T2 (red line, T1, black line, T2) 40

LIST OF TABLES

Table I - Sample age 41

Table II - Skeletal, dental, soft tissue profile cephalometric variables 42

Table III - Error study (Intraclass correlation coefficients - ICC) 43

Table IV - Interphase comparisons (paired t tests) 44

Table V - Males and females changes and comparisons (t tests).....45

LIST OF ABBREVIATIONS AND ACRONYMS

T1	Timing 1
T2	Timing 2
SD	Standard deviation
ICC	Intraclass Correlation Coefficients
Mx1	Maxillary central incisors
Mx6	Maxillary first molars
Md1	Mandibular central incisors
Md6	Mandibular first molars

TABLE OF CONTENTS

1 INTRODUCTION 21

2 ARTICLE 25

3 DISCUSSION 49

4 CONCLUSSION 53

REFERENCES 57

APPENDIX 63

ANNEXES 67

1 INTRODUCTION

1 INTRODUCTION

The normal occlusion plays an important goal in orthodontics, once the occlusion evaluation is fundamental to stablish success at the end of the treatment. Dental arches and teeth positioning suffer changes due to the maturation process, since the individual is alive, teeth will change position respecting a compensatory mechanism that aims to maintain the structural balance of the face and dentition (BEHRENTS, 1985; BISHARA; TREDER; JAKOBSEN, 1994; TIBANA; PALAGI; MIGUEL, 2004). The knowledge of the normal changes that occur in the craniofacial complex with aging have total importance for the professional predict what will happen in the long term, considering that the life expectancy in the last century and the number of adults who seek orthodontic treatment remarkably increased. Growth until the first two decades of life is well documented (RIOLO, 1974; SINCLAIR; LITTLE, 1985; RICHARDSON; MOYERS, 1992) and some other studies extended the assessment to the mid adulthood (BISHARA; TREDER; JAKOBSEN, 1994; WEST; MCNAMARA, 1999; PECORA; BACCETTI; MCNAMARA, 2008). However, few studies evaluated the maturational changes in the late adulthood (MASSARO et al., 2018; MIRANDA et al., 2018).

The knowledge of the normal occlusion characteristics recognized by Andrews (ANDREWS, 1972) is an important reference in Orthodontics and over the years, many studies in the literature reported changes in the craniofacial complex with aging (BJORK, 1955; KENDRICK; RISINGER, 1967; SINCLAIR; LITTLE, 1985; BEHRENTS, 1986; BISHARA; TREDER; JAKOBSEN, 1994; WEST; MCNAMARA, 1999; PECORA; BACCETTI; MCNAMARA, 2008; MASSARO et al., 2018; MIRANDA et al., 2018). Many longitudinal cephalometric comparisons, from adolescence to adulthood were evaluated, in treated and nontreated individuals (ISRAEL, 1973; SARNAS; SOLOW, 1980; BEHRENTS, 1985; BISHARA; TREDER; JAKOBSEN, 1994; FORMBY; NANDA; CURRIER, 1994; WEST; MCNAMARA, 1999; PECORA; BACCETTI; MCNAMARA, 2008).

The results of these long-term longitudinal cephalometric studies showed that craniofacial growth is a continuous process throughout life (BJORK, 1951, 1955, 1963; KENDRICK; RISINGER, 1967; ISRAEL, 1973; BEHRENTS, 1985; BISHARA;

TREDER; JAKOBSEN, 1994; WEST; MCNAMARA, 1999; PECORA; BACCETTI; MCNAMARA, 2008) and did not corroborate the hypothesis that growth stops soon after puberty. Changes in the dentoskeletal and tegumental structures was reported until the sixth decade of life (WEST; MCNAMARA, 1999; PECORA; BACCETTI; MCNAMARA, 2008).

In one of the first attempts to examine craniofacial growth into early adulthood, with lateral cephalograms of 12 to 20 years old boys, results showed that growth continued up through age 22 (BJORK, 1951, 1955; BJORK; SKIELLER, 1977). From 21 to 26 years, an increase in the vertical dimensions, specially in total anterior facial height was noted with no sexual dimorphism (SARNAS; SOLOW, 1980). A longitudinal cephalometric study with individuals between 25 to 35 years found an increase in lower anterior facial height, anterior movement of the nose apex, retrusion of the lips (FORSBERG, 1979). Behrents, (BEHRENTS, 1985) conducted the most detailed investigation into the changes with aging in the craniofacial complex. The sample was composed by individuals between 25 and 83 years. It was observed a general stability of the pterygomaxillary fissure. The maxilla moved forward in concordance with the nasion. The total mandibular length increased with aging, and the gonial angle became more acute, especially in men. In males, the chin moved forward and downward, while in females, there was only a downward movement. There were several changes in the soft tissues, like the pogonion, that became more prominent with aging, especially in men. Extending the evaluation until the fifth and sixth decade of life (WEST; MCNAMARA, 1999; PECORA; BACCETTI; MCNAMARA, 2008), it was observed a different pattern of mandibular changes for each sex. Men showed an anterior rotation of the mandible, while women had a posterior rotation. Changes in the soft tissues were the most remarkable and included significant thinning of the upper lip, drooping of the nasal tip and columella and more acute nasolabial angle.

Although there are many longitudinal cephalometric changes in the craniofacial complex, there is no study in the literature that evaluates the aging process until the seventh decade of life, especially in individuals with normal occlusion. Thus, the aim of the present study was to assess dentoskeletal and tegumental changes in individuals with normal occlusion, from 17 to 61 years of age, a 43-year follow-up study.

2 ARTICLE

2 ARTICLE

The article presented in this Dissertation was written according to the American Journal of Orthodontics and Dentofacial Orthopedics instructions and guidelines for article submission.

DENTOSKELETAL AND TEGUMENTAL CHANGES IN INDIVIDUALS WITH NORMAL OCCLUSION AFTER A 40-YEAR FOLLOW-UP

ABSTRACT

Introduction: Craniofacial growth and development is a continuous process that determines maturational changes throughout life. **Objectives:** The aim of this study was to evaluate cephalometric changes in individuals with normal occlusion from 17 years of age to the seventh decade of life. **Methods:** The sample comprised lateral cephalograms of 21 subjects with normal occlusion (11 males, 10 females), taken at 17 (T1) and 61 years of age (T2), which were digitized and measured using Dolphin Imaging 11.0 software. Anteroposterior and vertical maxillomandibular relationship, dentoalveolar and tegumental changes were analyzed. The interphase comparison was performed using paired t tests. Sexual dimorphism was evaluated using t tests. **Results:** A significant anterior displacement of the maxilla and mandible was observed between T1 and T2 time points. An increase of the ramus height, a counterclockwise rotation of the occlusal, palatal and mandibular planes, and a decrease of the upper facial height were observed during maturational process. Maxillary first molars tipped mesially and extruded. Soft tissue changes with aging were a decrease of the nasolabial angle, upper and lower lip retrusion and an increase of the soft-tissue chin thickness. A decrease of the maxillary incisor exposure and upper lip thickness was also observed. Sexual dimorphisms in the mandibular anteroposterior displacement and rotation were found. In males, a protrusion and a counterclockwise rotation of the mandible was found with a decrease in the overjet. In females, a mandibular clockwise rotation and a backward displacement of the chin were noted. A greater retrusion of the upper and lower lips and a greater increase of the soft chin thickness were observed in males. **Conclusion:** Aging changes were more intense in the soft tissue compared to the skeletal and dentoalveolar structures. An expressive sexual dimorphism for craniofacial changes was observed during the maturational process.

Key words: Normal occlusion, cephalograms, adults, maturation, aging.

INTRODUCTION

Life expectancy remarkably increased in the last century.[1] Craniofacial growth and development is a continuous process and maturational changes can occur during aging.[2,3] The number of adults who seek orthodontic treatment for functional or esthetic improvement has increased and understanding the natural changes that occur throughout life in the craniofacial complex is extremely important. Most previous longitudinal studies evaluated changes in the first two decades of life.[4-9] Growth was thought to stop soon after puberty.[10] However, previous studies revealed that growth continued during adulthood.[2,3,10-21]

The first studies on craniofacial growth after adolescence have evaluated males from 12 to 22 years of age showing that growth continued until adulthood.[13-16] An increase in all anteroposterior dimensions of the skull over a one-year period was found in adult males.[20] From 35 to 54 years of age, women showed a slight increase in several craniofacial dimensions, including skull thickness, cranial base length and upper anterior facial height.[19] Behrents showed that craniofacial growth is a continuous process during human aging.[2] In his detailed study in a nontreated sample from 25 to 83 years of age, men showed a forward and downward mandibular displacement while women showed a backward mandibular rotation. The soft pogonion became more prominent specially in men. The soft tissue glabella continued to move forward and there was retrusion of the upper lip. After 40 years of age, only mild changes were observed until the eighth decade of life. The facial profile straightened with age only in males.[17] A previous maturational study until the fifth decade of life showed that men presented an anterior rotation of the mandible while women showed a posterior mandibular rotation.[21] A study with untreated subjects from 17 to 57 years of age reported that changes in the soft tissue were more evident than dentoskeletal changes with aging, including a flattening and elongation of the upper lip, and a drooping of the nasal tip and columella.[10]

Only one previous cephalometric study evaluated aging in normal occlusion subjects showing that the anteroposterior and vertical dimensions increased from 25 and 46 years of age.[3] No cephalometric study has evaluated individuals with normal occlusion up to the seventh decade of life. Therefore, the objective of this study was to evaluate the dentoskeletal and soft tissue changes in individuals with normal occlusion from 17 to 61 years of age.

MATERIAL AND METHODS

This observational and longitudinal study was approved by the Ethics in Research Committee of Bauru Dental School, University of São Paulo, Brazil (Process #71634917.5.0000.5417). The sample size calculation was based on preliminary statistics including the first 5 subjects of the sample. For a standard deviation of 1.57mm for the variable A-Nperp and a minimal interphase difference of 1mm to be detected, a sample of 21 subjects was required to provide statistical power of 80% with an α of 5%.

The initial sample comprised 82 white-Brazilian individuals with normal occlusion obtained between 1970 to 1974 from the files of the Department of Orthodontics from Bauru Dental School, University of São Paulo. All subjects had (1) clinically acceptable occlusion in the complete permanent dentition, (2) dental and skeletal Class I relationships, (3) absence of crossbites, (4) normal overjet and overbite, (5) maximum 2mm of incisor crowding and (6) no previous orthodontic treatment. Lateral cephalograms taken at 17 years of age was used (T1). From 2015 to 2016, the sample was recalled and lateral cephalograms were obtained at a mean age of 61 years (T2). The exclusion criteria for T2 records were history of orthodontic treatment between T1 and T2 and complete tooth loss in the posterior region of the dental arches. The final sample comprised 21 subjects (11 males, 10 females) described at Table I.

All the lateral cephalograms were scanned using ScanMaker i800 scanner (Microtek, Hsinchu, Taiwan) and analyzed using Dolphin Imaging 11.0 software (Dolphin Imaging and Management Solutions, Chatsworth, Calif., USA). Magnifications factors were corrected and 37 variables were measured (Table II).

For the error study, 50% of the sample was randomly re-measured by the same examiner (G.M.N.) after a minimum 30-day interval. The intraexaminer reliability was assessed using intraclass correlation coefficients (ICCs).[22]

Statistical analyses

Mean and standard deviation were calculated for all measurements at T1 and T2. Kolmogorov-Smirnov tests showed normal distribution for all variables. Interphase changes from T1 to T2 were evaluated using paired *t* tests. Sexual differences were investigated using *t* tests. The significance level considered was 5%. The statistical

analyses were performed using Statistica© software (Statistica for Windows version 7.0, StatSoft Inc., Tulsa, USA).

RESULTS

Table III shows the error study results. All variables had good to excellent intraexaminer agreement with intraclass correlation coefficients varying from 0.75 to 0.98.

Table IV shows interphase changes for the complete sample. From 17 to 61 years of age, there was a maxillary and mandibular anterior displacement and a significant increase of the ramus height. The occlusal, palatal and mandibular planes rotated counterclockwise and a decrease of the upper facial height was observed. Maxillary molars extruded and angulated toward mesial. Significant changes were observed in the soft tissue including a retrusion of the upper and lower lips and a decrease of the nasolabial angle. The thickness of the upper lip decreased, while the thickness of the soft chin significantly increased. The exposition of maxillary incisor by the upper lip decreased with aging.

Differences were found between sexes. In males, a protrusion and counterclockwise rotation of the mandible were observed. A greater increase of the ramus height and a decrease in the overjet were also found in males. In females, a backward displacement of the chin and a mandibular clockwise rotation were noted. Additionally, a greater retrusion of the upper and lower lips and a greater thickness increase of the soft chin were observed in males.

DISCUSSION

This is the first cephalometric study evaluating aging until the seventh decade of life in normal occlusion subjects. Previous studies on maturational changes of craniofacial complex were conducted in untreated individuals.[3,10,12,17,21,23,24] One of the limitations of performing longitudinal studies is the difficulty in collecting data, which restricts the sample size.[10,21,25,26] From the original normal occlusion sample of 82 individuals, 36 were not found, 8 have died, 3 have lost all teeth, 8 have not accept to participate and other 6 individuals have not met the inclusion criteria. In this study, changes in the craniofacial complex were evaluated over 43 years, from early adulthood to the seventh decade of life. The results showed several changes in the skeletal and tegumental tissues with aging (Figs. 2 to 4), confirming that craniofacial growth continued into adulthood as previously reported.[2] The most relevant findings

were that soft tissue changes were more expressive than dentoskeletal changes confirming previous studies performed in untreated individuals.[2,10,17,21]

A slight maxillary and mandibular anterior displacement was observed during the 43-year follow-up with no changes in the maxillomandibular relationships (Table IV). Mandibular ramus height showed a significant increase of 1.91mm from T1 to T2. These results corroborate previous longitudinal studies on craniofacial growth.[3,10,17,21,23,27] The anterior movement of the maxilla could be explained by a maxillary bodily displacement as a whole,[27] considering the maxillary length was stable. The increase of the mandibular protrusion was probably related to the increase of ramus height and the counterclockwise rotation of the mandible.[5,9,23] Additionally, bone apposition on the anterior surface of symphysis might has occurred[23] (Table IV).

Occlusal, palatal and mandibular planes showed a counterclockwise rotation from 17 to 61 years of age, corroborating previous studies.[2,9,10,21] A slight decrease of upper facial height was observed probably in consequence to the upward rotation of the palatal plane. This finding disagrees with previous studies showing an increase of upper facial height with aging.[3,10,21] Differences in sample age, ethnical background and occlusion features might explain these divergences.

Dentoalveolar changes occurred only in the maxillary first molars that tipped mesially and extruded (Table IV). The increase of the maxillary molar angulation can be explained by the mesial shift of the posterior teeth throughout life[2,28,29] and the mesiodistal tooth size reduction during aging.[25] The increase of the maxillary molar extrusion supports the observation that the maxillary teeth continue to erupt over time during adulthood.[9,21] Dental relationships remained stable during aging, agreeing with previous studies until 40 and 50 years of age.[10,21]

Over the 40-year follow-up, changes of facial soft tissue were more expressive than dentoskeletal alterations. The upper and lower lips became more retruded, specially the upper lip (Table IV, Fig. 3). Considering that no significant changes were observed for maxillary and mandibular incisor protrusion with aging, lip retrusion is probably most related to the decrease of lip thickness. Similar findings were reported in previous studies in untreated subjects.[10,17,23] The reduction of the upper lip thickness observed in our study might be related to the natural aging process of the skin which becomes less consistent and inelastic over time.[2,10,17,30] In addition, the maxillary incisor exposure decreased probably due to both upper lip vertical changes and the occurrence of an incisal edge wear in the central incisors.[25] The 3.89mm reduction in

the maxillary incisor exposure over a 40-year follow-up indicate that a rate of approximately 1mm/decade is lost in the maxillary incisor display at rest, agreeing with previous study that related a gradual decrease of maxillary incisor exposition with age.[31-33]

Changes were also observed on the perioral structures. The nasolabial angle decreased approximately 6º even in front of an upper lip retrusion, indicating that a downward movement of the nose columella has occurred with aging. A previous study measured the vertical development of columella relative to the Frankfurt plane showing an increase of 3.8mm from 17 to 57 years of age.[10] Other studies also reported similar findings of downward movement of the nose with advancing age.[2,17,21,24,34] The soft-tissue chin became thicker and slightly more protruded with aging (Table IV, Figure 3). This finding agrees with previous studies that showed an increase in the region of the soft-tissue chin.[2,10] Both the nose and soft-tissue chin changes should increase the perception of lip bi-retrusion with aging.

Some differences between sexes were noted over the 40-year follow-up. Males presented a protrusion and a counterclockwise rotation of the mandible. In contrast, females showed a retrusion and a clockwise rotation of the mandible (Table V; Figs. 4 and 5). Our results agree with previous studies in untreated subjects.[2,10,21] Pecora et al also showed sexual mandibular growth differences from 17 to 47 years of age.[10] Both sexes showed an increase in the mandibular ramus height (Co-Go) from T1 to T2, but men showed a greater increase than women (3.37mm and 0.31mm, respectively). These findings corroborate with other studies.[2,3,21] The greater increase in the ramus height in men could be associated with the counterclockwise rotation of the mandible.[23] Furthermore, several men had not completed their circumpubertal active growth at T1. Considering the cervical vertebral maturation,[35] seven out of 11 males subjects were at CS5 and three were still at CS4 at 17 years of age. On the contrary, 6 out of 10 females subjects showed stage CS6 at T1. These differences in skeletal maturation between the sexes at T1 could explain the greater changes noted in men from 17 to 61 years of age (Table V, Fig. 4).

The overjet changes were also different between sexes. Men showed a 1.10mm reduction of the overjet, while women showed no change. This result is possibly associated with the anterior rotation of the mandible observed in men. These results are in agreement with a previous study in subjects with normal occlusion that also reported a decrease in the overjet in some males.[26] Previous studies showed no

significant longitudinal changes for the overjet in nontreated subjects.[10,21] These differences might be related to the presence of malocclusion in the sample. Men showed a greater retrusion of the upper and lower lips than women. These findings corroborate previous studies.[2,3,21,36] The soft-tissue chin thickness increased more in men than women in a 3:1 ratio. These results support previous studies showing similar findings.[2,10,30,32]

In summary, this study provided further evidence that craniofacial complex continues to change from early adulthood to the seventh decade of life. Several changes in the dentoskeletal and tegumental tissues might be expected with aging in subjects with normal occlusion. As clinical considerations, orthodontists should be very careful when indicating procedures that reduces lip protrusion and decreases maxillary incisor display once these procedures might accelerate facial aging.

CONCLUSION

From 17 to 61 years of age, the changes in the facial soft tissue were more remarkable than dentoskeletal changes. An anterior displacement of both the maxilla and mandible was observed. There was an increase of the ramus height, a counterclockwise rotation of the occlusal, palatal and mandibular planes and a decrease of the upper facial height. Maxillary first molars tipped mesially and extruded. A closure of the nasolabial angle, a retrusion of the upper and lower lips related to soft tissue thickness decrease, an increase of the soft-tissue chin and a reduction of the maxillary incisor exposition were observed. Significant sexual differences were noted during the aging process.

ACKNOWLEDGMENT

We thank the Coordination for the Improvement of Higher Education Personnel (CAPES – Finance Code 001) and São Paulo Research Foundation (FAPESP – Process number 2017/11215-9) for their financial support.

REFERENCES

1. World Health Organization. World Health Statistics. [Database on the Internet]. www.who.int/gho; (30 November 2018, date last accessed).

2. Behrents RG. A treatise on the continuum of growth in the aging craniofacial skeleton. Ann Arbor: Center of Human Growth and Development, University of Michigan;1984.

3. Bishara SE, Treder JE, Jakobsen JR. Facial and dental changes in adulthood. Am J Orthod Dentofacial Orthop 1994;106:175-186.

4. Broadbent Jr B, Golden WH, Brown RG. Bolton Standards Of Dentofacial Development Growth. Plastic and Reconstructive Surgery 1977;59:115.

5. Riolo ML. An atlas of craniofacial growth: cephalometric standards from the University School Growth Study, the University of Michigan. Center for Human Growth and Development, University of Michigan; 1974.

6. Richardson ER, Moyers RE. Atlas of craniofacial growth in Americans of African descent. Univ of Michigan Center for; 1992.

7. Stahl de Castrillon F, Baccetti T, Franchi L, Grabowski R, Klink-Heckmann U, McNamara JA. Lateral cephalometric standards of Germans with normal occlusion from 6 to 17 years of age. J Orofac Orthop 2013;74:236-256.

8. Bae EJ, Kwon HJ, Kwon OW. Changes in longitudinal craniofacial growth in subjects with normal occlusions using the Ricketts analysis. Korean J Orthod 2014;44:77-87.

9. Sinclair PM, Little RM. Dentofacial maturation of untreated normals. Am J Orthod 1985;88:146-156.

10. Pecora NG, Baccetti T, McNamara JA, Jr. The aging craniofacial complex: a longitudinal cephalometric study from late adolescence to late adulthood. Am J Orthod Dentofacial Orthop 2008;134:496-505.

11. Andrews LF. The six keys to normal occlusion. Am J Orthod 1972;62:296-309.

12. Bishara SE. Facial and dental changes in adolescents and their clinical implications. Angle Orthod 2000;70:471-483.

13. Bjork A. The face in profile: an anthropological x-ray investigation on Swedish children and conscripts. Am. J. Orthod. 1948;34:691-699.

14. Bjork A. The significance of growth changes in facial pattern and their relationship to changes in occlusion. Dent Rec (London) 1951;71:197-208.

15. Bjork A. Facial growth in man, studied with the aid of metallic implants. Acta Odontol Scand 1955;13:9-34.

16. Bjork A. Variations in the growth pattern of the human mandible: longitudinal radiographic study by the implant method. J Dent Res 1963;42(1)Pt 2:400-411.

17. Formby WA, Nanda RS, Currier GF. Longitudinal changes in the adult facial profile. Am J Orthod Dentofacial Orthop 1994;105:464-476.

18. Forsberg CM, Odenrick L. Changes in the relationship between the lips and the aesthetic line from eight years of age to adulthood. Eur J Orthod 1979;1:265-270.

19. Israel H. Age factor and the pattern of change in craniofacial structures. Am J Phys Anthropol 1973;39:111-128.

20. Kendrick GS, Risinger HL. Changes in the anteroposterior dimensions of the human male skull during the third and fourth decade of life. Anat Rec 1967;159:77-81.

21. West KS, McNamara JA, Jr. Changes in the craniofacial complex from adolescence to midadulthood: a cephalometric study. Am J Orthod Dentofacial Orthop 1999;115:521-532.

22. Shrout PE, Fleiss JL. Intraclass correlations: uses in assessing rater reliability. Psychol Bull 1979;86:420-428.

23. Behrents RG. Growth in the aging craniofacial skeleton. Center for Human Growth and Development, University of Michigan; 1985.

24. Forsberg CM. Facial morphology and ageing: a longitudinal cephalometric investigation of young adults. Eur J Orthod 1979;1:15-23.

25. Massaro C, Miranda F, Janson G, Rodrigues de Almeida R, Pinzan A, Martins DR et al. Maturational changes of the normal occlusion: A 40-year follow-up. Am J Orthod Dentofacial Orthop 2018;154:188-200.

26. Miranda F, Massaro C, Janson G, de Freitas MR, Henriques JFC, Lauris JRP et al. Aging of the normal occlusion. Eur J Orthod 2018.

27. Bjork A, Skieller V. Growth of the maxilla in three dimensions as revealed radiographically by the implant method. Br J Orthod 1977;4:53-64.

28. Bishara SE, Treder JE, Damon P, Olsen M. Changes in the dental arches and dentition between 25 and 45 years of age. Angle Orthod 1996;66:417-422.

29. Tibana RH, Palagi LM, Miguel JA. Changes in dental arch measurements of young adults with normal occlusion--a longitudinal study. Angle Orthod 2004;74:618-623.

30. Nanda RS, Meng H, Kapila S, Goorhuis J. Growth changes in the soft tissue facial profile. Angle Orthod 1990;60:177-190.

31. Dong JK, Jin TH, Cho HW, Oh SC. The esthetics of the smile: a review of some recent studies. Int J Prosthodont 1999;12:9-19.

32. Vahdettin L, Altug Z. Longitudinal soft-tissue profile changes in adolescent Class I subjects. J Orofac Orthop 2012;73:440-453.

33. Van der Geld P, Oosterveld P, Kuijpers-Jagtman AM. Age-related changes of the dental aesthetic zone at rest and during spontaneous smiling and speech. Eur J Orthod 2008;30:366-373.

34. Subtelny J. A longitudinal study of soft tissue facial structures and their profile characteristics, defined in relation to underlying skeletal structures. American Journal of Orthodontics 1959;45:481-507.

35. Baccetti T, Franchi L, McNamara JA, Jr. An improved version of the cervical vertebral maturation (CVM) method for the assessment of mandibular growth. Angle Orthod 2002;72:316-323.

36. Zylinski CG, Nanda RS, Kapila S. Analysis of soft tissue facial profile in white males. Am J Orthod Dentofacial Orthop 1992;101:514-518.

FIGURE LEGENDS

Figure 1 – A-B: Lateral cephalograms of a man at T1 (17 years) and T2 (61 years). C-D: Lateral cephalograms of a woman at T1 (17 years) and T2 (61 years).

Figure 2 – Superimposition of average sample tracing from T1 to T2 (red line, T1, black line, T2).

Figure 4 – Superimposition of average male tracing from T1 to T2 (red line, T1, black line, T2).

Figure 5 – Superimposition of average female tracing from T1 to T2 (red line, T1, black line, T2).

FIGURES

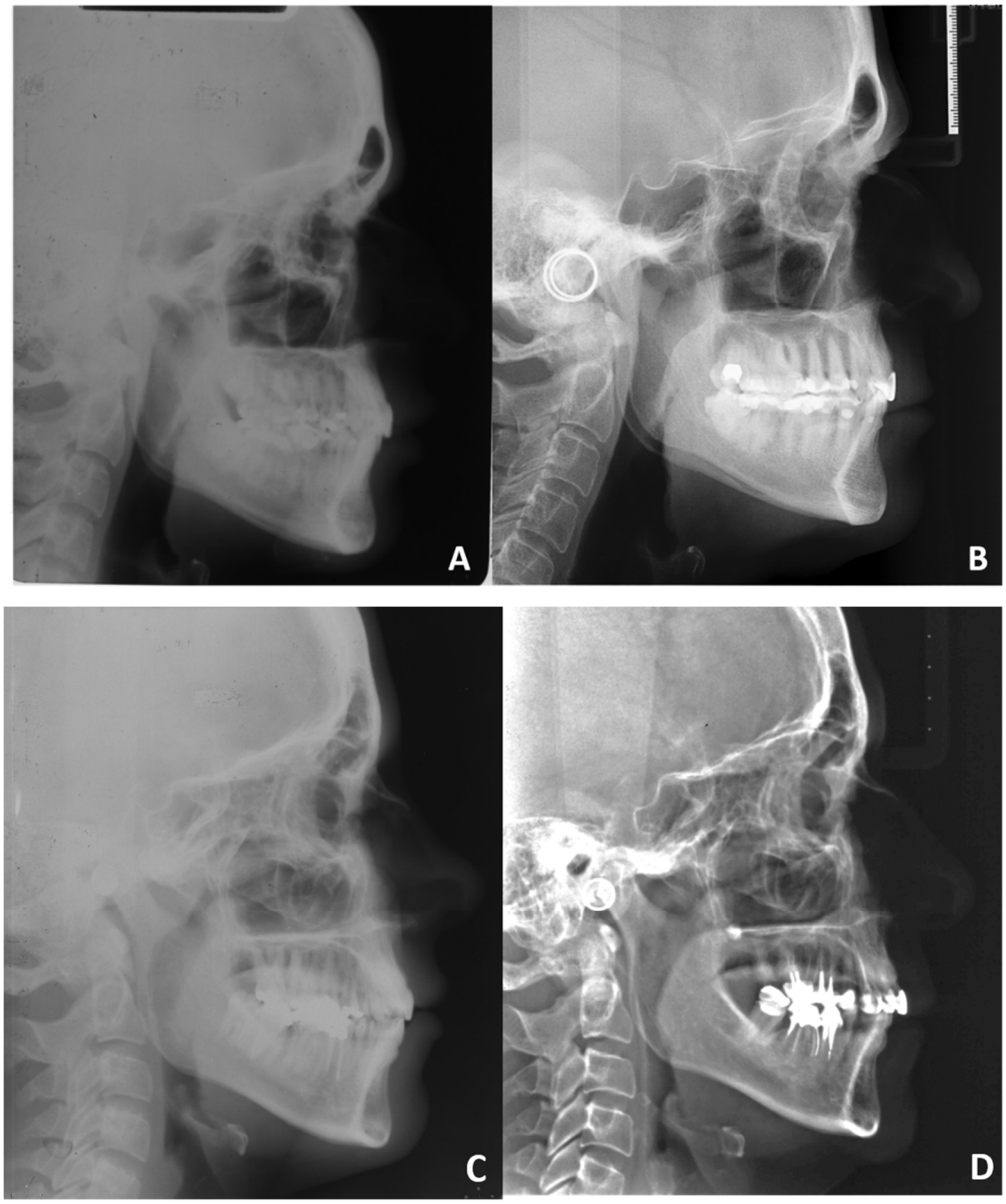

Figure 1

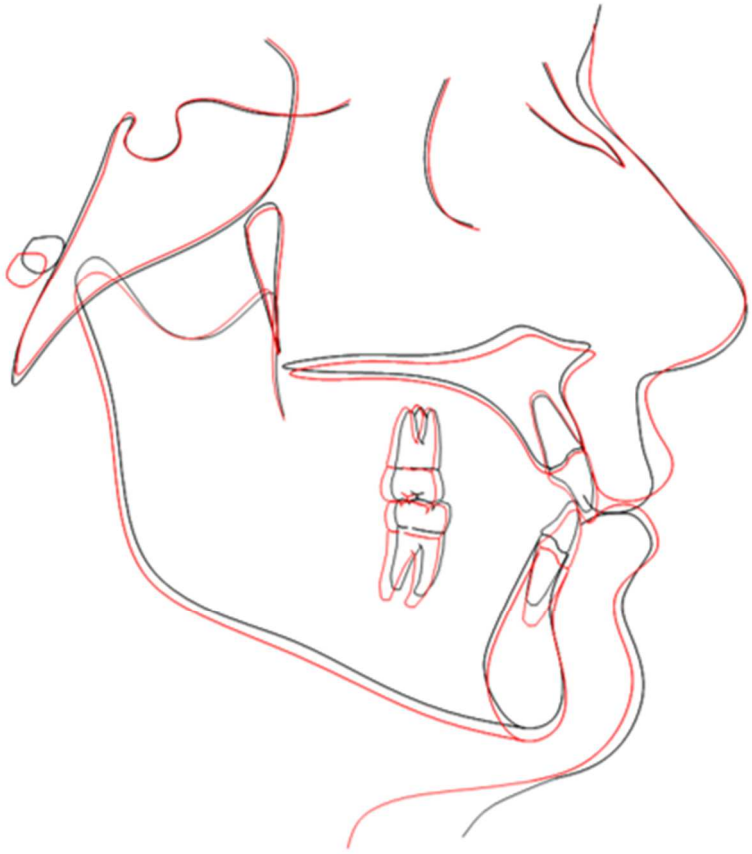

Figure 2

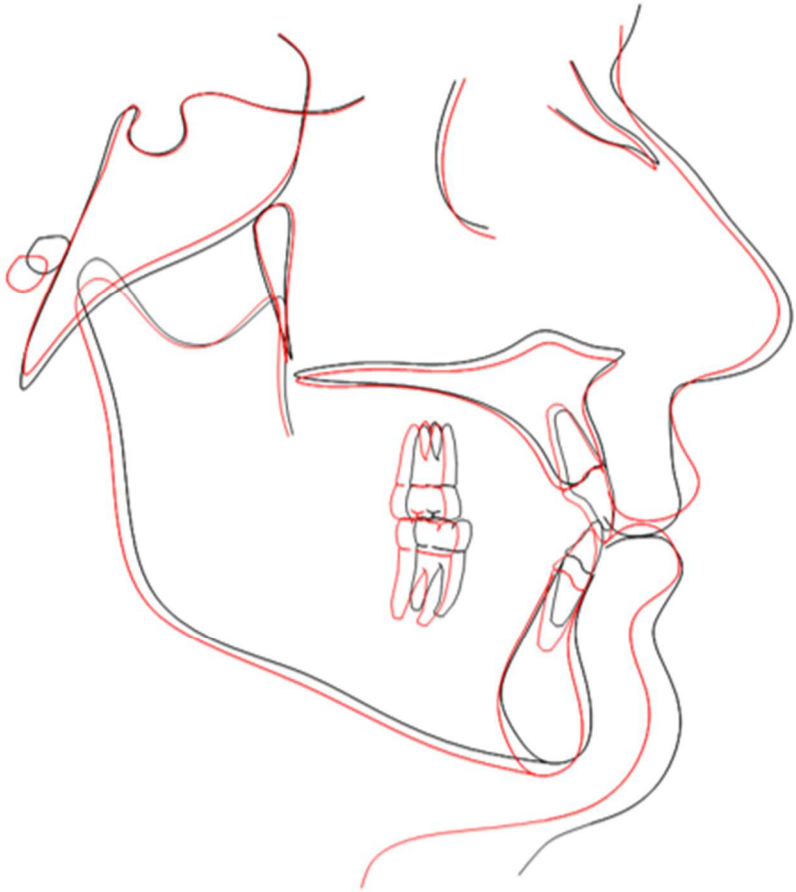

Figure 3

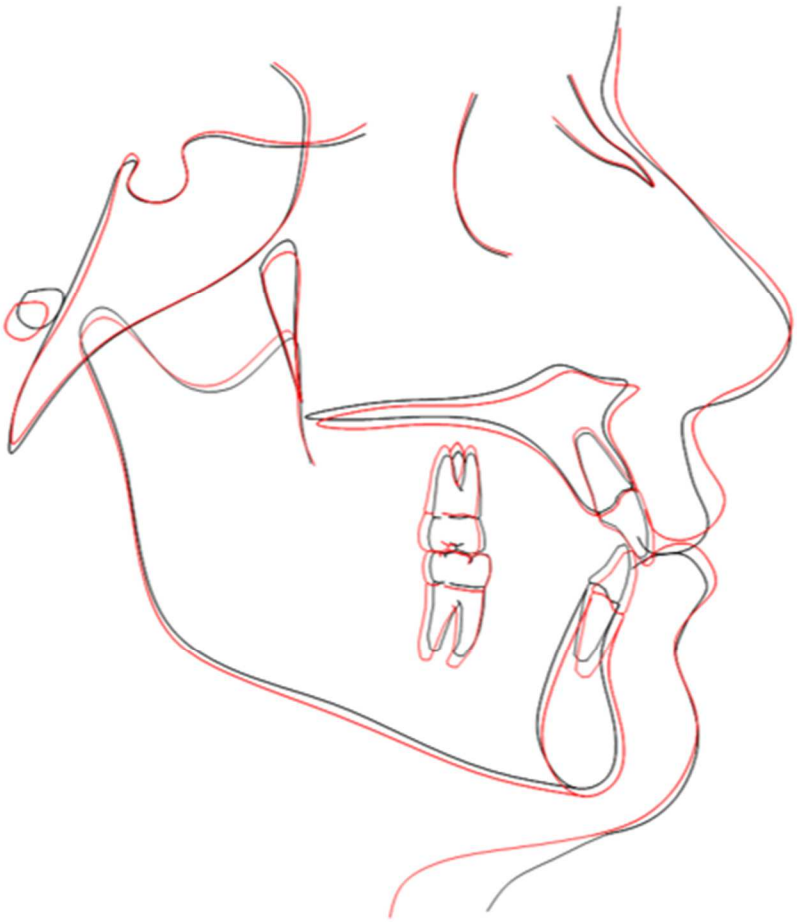

Figure 4

Table I – Sample age.

Time	Mean age (Males)		Mean age (Females)		Mean age (total)	
	Mean	**SD**	**Mean**	**SD**	**Mean**	**SD**
T1	17.90	0.91	17.29	0.91	17.61	0.96
T2	61.52	1.59	61.13	1.61	61.34	1.57

Table II - Skeletal, dental, soft tissue profile cephalometric variables.

Variables	Definition
Maxillary Skeletal Component	
SNA (º)	SN to NA angle
CoA (mm)	Condylion to A-point distance
A-NPerp (mm)	A point to nasion-perpendicular
Mandibular Skeletal Component	
SNB (º)	SN to NB angle
Co-Gn (mm)	Condylion to Gnathion distance
P-Nperp (mm)	Point P relative to the perpendicular passing through N
Co-Go (mm)	Condylion to gonion distance
Maxillomandibular relatioship	
ANB (º)	NA to NB angle
mx/md dif (mm)	difference between mandibular and maxillary length
Vertical Component	
OP.FH (º)	Oclusal plane to Frankfurt plane angle
PP.FH (º)	Palatal plane to Frankfurt plane angle
FMA (º)	Frankfurt mandibular plane
SNGoGn (º)	SN to GoGn angle
UFH (mm)	Distance between N and ANS points
LAFH (mm)	Distance bewteen ANS and Me points
Maxillary dentoalveolar component	
Mx1.NA (º)	Maxillary incisor long axis to Na angle
Mx1-NA (mm)	Distance between anterior point of crown of maxillary incisor and NA line
Mx1-PP (mm)	Distance between maxillary incisal edge and palatal plane
Mx6.SN (º)	Angle formed by the long axis of maxillary first molar and SN plane
Mx6-PP (mm)	Mean perpendicular distance between mesial and distal cusp of maxillary first molar and palatal plane
Mandibular dentoalveolar component	
Md1.NB (º)	Mandibular incisor long axis to NB angle
Md1-NB (mm)	Distance between most anterior point of crown of mandibular incisor and NB line
IMPA (º)	Incisor mandibular plane angle
Md1-MP (mm)	Distance between mandibular incisal edge and mandibular plane
Md6.MP (º)	Angle formed by the long axis of mandibular first molar and MP
Md6-MP (mm)	Distance between occlusal point of mandibular first molar and mandibular plane
Dental relationship	
Overjet (mm)	Distance bewteen incisal edge of maxillary and mandibular central incisor, parallel to occlusal plane
Overbite (mm)	Distance between incisal edge of maxillary and mandibular central incisor, perpendicular to occlusal plane
Mx1.Md1 (º)	Angle between the long axis of Mx1 and Md1
Soft Tissue Profile	
Nasolabial Angle (º)	Angle formed between the nose and upper lip
UL cant (º)	Upper lip inclination
UL-E plane (mm)	Distance between upper lip to E plane
LL-E plane (mm)	Distance between lower lip to E plane
UL thickness (mm)	Distance between UL to Mx1
LL thickness (mm)	Distance between LL to Md1
Chin thickness (mm)	Distance between Pog to Pog’
Mx1 exposure (mm)	Mx1 exposure with lips at rest

Table III - Error study (Intraclass correlation coefficients - ICC).

Variables	Measurement 1		Measurement 2		Difference		ICC
	Mean	SD	Mean	SD	Mean	SD	
Maxillary Skeletal Component							
SNA (º)	84.26	3.12	84.44	3.24	0.17	1.01	0.94
CoA (mm)	86.19	5.68	86.75	5.16	0.56	1.41	0.96
A-Nperp (mm)	1.95	2.88	2.45	2.92	0.47	0.97	0.93
Mandibular Skeletal Component							
SNB (º)	80.97	2.54	81.01	2.44	0.04	0.46	0.98
Co-Gn (mm)	118.67	6.84	117.92	7.41	-0.74	1.60	0.96
P-Nperp (mm)	-0.63	3.72	-0.23	3.62	0.40	1.98	0.84
Co-Go (mm)	63.18	4.85	62.38	6.01	-0.80	2.58	0.87
Maxillomandibular relationship							
ANB (º)	3.28	1.52	3.45	1.83	0.16	0.72	0.90
mx/md dif. (mm)	27.53	3.30	26.61	3.26	-0.92	1.99	0.78
Vertical Component							
OP.FH (º)	7.08	3.86	6.72	4.14	-0.36	2.57	0.79
PP.FH (º)	-0.52	2.33	-1.15	2.00	-0.62	1.39	0.76
FMA (º)	23.28	3.04	22.97	3.51	-0.31	0.83	0.96
SNGoGn (º)	28.02	4.23	28.35	4.02	0.32	1.17	0.95
UFH (mm)	51.52	2.44	51.55	3.00	0.02	1.29	0.88
LAFH (mm)	68.15	4.93	67.46	5.18	-0.69	2.39	0.87
Maxillary dentoalveolar component							
Mx1.NA (º)	17.54	5.82	16.59	6.51	-0.95	2.13	0.92
Mx1-NA (mm)	2.43	1.84	2.23	2.10	-0.20	0.92	0.88
Mx1-PP (mm)	29.30	2.37	28.83	1.99	-0.46	1.42	0.77
Mx6.SN (º)	77.45	4.17	78.37	3.57	0.91	2.46	0.77
Mx6-PP (mm)	21.04	2.30	20.33	2.54	-0.70	1.27	0.82
Mandibular dentoalveolar component							
Md1.NB (º)	22.78	3.58	23.29	3.14	0.50	2.08	0.79
Md1-NB (mm)	4.26	1.13	4.41	1.22	0.15	0.36	0.94
IMPA (º)	90.55	3.83	91.40	3.20	0.86	2.17	0.78
Md1-MP (mm)	39.75	2.87	39.58	3.09	-0.17	1.50	0.87
Md6.MP (º)	83.77	5.19	83.42	4.40	-0.35	3.06	0.79
Md6-MP (mm)	33.20	2.90	32.81	3.38	-0.38	1.73	0.84
Dental Relationship							
Overjet (mm)	2.95	0.43	2.86	0.43	-0.08	0.29	0.75
Overbite (mm)	2.42	1.13	2.40	1.22	-0.02	0.34	0.95
Mx1.Md1 (º)	138.23	7.34	138.53	7.45	0.30	4.11	0.84
Soft tissue profile							
Nasolabial Angle (º)	108.93	9.73	109.30	9.75	0.37	4.04	0.97
UL cant (º)	4.72	5.01	4.80	5.62	0.07	2.40	0.89
UL-Eplane (mm)	-5.48	2.33	-5.30	2.56	0.17	0.56	0.97
LL-Eplane (mm)	-3.76	2.16	-3.65	2.46	0.11	0.54	0.97
UL thickness (mm)	12.09	2.56	11.93	2.38	0.15	0.76	0.95
LL thickness (mm)	12.37	1.63	12.19	1.68	-0.18	0.79	0.87
Chin thickness (mm)	13.30	2.28	12.92	2.32	-0.37	1.51	0.77
Mx1 exposure (mm)	1.85	2.62	1.82	2.44	-0.02	0.82	0.94

Table IV - Interphase comparisons (paired t tests).

Variables	T1		T2		T2-T1		*p*
	Mean	SD	Mean	SD	Mean	SD	
Maxillary Skeletal Component							
SNA (º)	82.52	3.73	82.90	3.95	0.38	1.47	0.244
CoA (mm)	86.56	5.06	87.29	5.29	0.45	2.34	0.168
A-Nperp (mm)	0.16	3.26	1.57	2.62	1.41	1.79	**0.001***
Mandibular Skeletal Component							
SNB (º)	80.17	2.97	80.34	3.40	0.17	1.47	0.598
Co-Gn (mm)	120.22	7.06	120.56	7.64	0.34	2.39	0.521
P-Nperp (mm)	-2.20	3.70	0.24	3.80	2.44	4.20	**0.014***
Co-Go (mm)	63.32	5.03	65.23	6.20	1.91	3.24	**0.013***
Maxillomandibular relationship							
ANB (º)	2.34	2.04	2.56	2.48	0.21	1.36	0.472
mx/md dif. (mm)	28.70	4.09	28.70	3.90	0.13	1.61	0.697
Vertical Component							
OP.FH (º)	7.15	2.27	3.41	4.69	-3.73	4.81	**0.007***
PP.FH (º)	-0.70	2.11	-1.71	2.92	-0.93	2.05	**0.049***
FMA (º)	24.37	3.02	22.04	3.94	-2.32	3.06	**0.002***
SNGoGn (º)	28.64	3.31	28.08	4.61	-0.56	2.47	0.309
UFH (mm)	52.20	2.32	51.18	2.63	-1.01	1.09	**<0.001***
LAFH (mm)	69.26	6.11	68.45	6.03	-0.80	2.38	0.136
Maxillary dentoalveolar component							
Mx1.NA (º)	19.59	5.08	19.97	9.38	0.38	6.96	0.802
Mx1-NA (mm)	3.64	1.78	3.43	2.63	-0.20	1.83	0.611
Mx1-PP (mm)	29.41	3.20	28.64	4.01	-0.76	1.85	0.072
Mx6.SN (º)	74.06	3.62	77.97	4.53	3.90	4.55	**0.003***
Mx6-PP (mm)	20.26	2.79	22.36	2.91	2.10	1.90	**<0.001***
Mandibular dentoalveolar component							
Md1.NB (º)	23.20	5.01	24.50	5.27	1.29	4.56	0.209
Md1-NB (mm)	4.39	1.69	4.73	2.10	0.34	1.11	0.173
IMPA (º)	89.10	5.84	91.23	6.82	2.12	5.16	0.073
Md1-MP (mm)	40.12	3.12	39.17	4.37	-0.95	2.63	0.111
Md6.MP (º)	82.24	4.39	82.21	6.34	-0.03	7.59	0.983
Md6-MP (mm)	32.97	3.09	32.01	3.91	-0.95	2.59	0.125
Dental Relationship							
Overjet (mm)	2.61	0.91	2.36	1.41	-0.25	0.95	0.304
Overbite (mm)	1.99	1.26	1.78	1.20	-0.21	1.18	0.484
Mx1.Md1 (º)	134.84	6.80	132.98	11.21	-1.86	8.72	0.338
Soft tissue profile							
Nasolabial Angle (º)	109.45	8.66	103.70	10.97	-5.74	10.92	**0.025***
UL cant (º)	5.71	6.63	4.71	7.75	-1.00	7.87	0.567
UL-Eplane (mm)	-4.05	1.92	-7.53	3.16	-3.47	2.22	**<0.001***
LL-Eplane (mm)	-2.61	1.76	-5.04	2.70	-2.43	1.65	**<0.001***
UL thickness (mm)	13.95	1.87	10.76	1.84	-3.18	1.77	**<0.001***
LL thickness (mm)	12.47	1.93	13.12	2.55	0.64	1.90	0.134
Chin thickness (mm)	12.15	1.71	14.55	2.28	2.40	1.82	**<0.001***
Mx1 exposure (mm)	3.27	1.28	-0.62	1.98	-3.89	1.94	**<0.001***

*Statistically significant at $p < 0.05$

Table V – Males and females changes and comparisons (t tests).

Variables	Male (n=11)		Female (n=10)		p
	Mean	SD	Mean	SD	
Maxillary Skeletal Component					
SNA (º)	0.92	1.18	-0.21	1.59	0.076
CoA (mm)	1.51	2.40	1.13	0.51	0.634
A-Nperp (mm)	1.49	2.36	1.31	0.97	0.817
Mandibular Skeletal Component					
SNB (º)	0.94	1.18	-0.68	1.30	**0.007***
Co-Gn (mm)	1.43	2.20	0.46	1.06	0.223
P-Nperp (mm)	3.14	4.92	0.79	3.32	0.436
Co-Go (mm)	3.37	3.22	0.31	2.51	**0.026***
Maxillomandibular relationship					
ANB (º)	0.00	1.00	0.47	1.70	0.437
mx/md dif. (mm)	0.54	1.90	-0.30	1.15	0.239
Vertical Component					
OP.FH (º)	-5.17	5.11	-3.96	4.70	0.588
PP.FH (º)	-0.48	2.36	-1.44	1.62	0.297
FMA (º)	-3.28	3.08	-1.28	2.82	0.138
SNGoGn (º)	-1.97	1.91	0.99	2.08	**0.003***
UFH (mm)	-0.97	0.95	-1.05	1.28	0.867
LAFH (mm)	-1.44	2.19	-0.11	2.50	0.210
Maxillary dentoalveolar component					
Mx1.NA (º)	0.82	5.98	-0.10	8.21	0.769
Mx1-NA (mm)	-0.31	1.76	-0.08	2.00	0.782
Mx1-PP (mm)	-1.40	1.74	-0.07	1.80	0.101
Mx6.SN (º)	-5.82	2.85	3.64	4.99	0.344
Mx6-PP (mm)	-0.95	8.99	2.08	1.76	0.335
Mandibular dentoalveolar component					
Md1.NB (º)	2.32	5.47	0.15	2.90	0.268
Md1-NB (mm)	0.43	1.39	0.24	0.75	0.713
IMPA (º)	3.89	5.68	0.19	3.91	0.101
Md1-MP (mm)	-0.71	1.59	-1.22	3.53	0.663
Md6.MP (º)	1.28	8.53	-1.50	6.59	0.441
Md6-MP (mm)	-0.38	1.36	-1.59	3.49	0.327
Dental Relationship					
Overjet (mm)	-1.10	1.10	0.18	0.83	**0.015***
Overbite (mm)	-0.65	0.99	-0.01	1.38	0.296
Mx1.Md1 (º)	-3.10	9.12	-0.51	8.51	0.510
Soft tissue profile					
Nasolabial Angle (º)	-2.72	8.66	-9.07	12.58	0.190
UL cant (º)	-4.02	6.98	2.33	7.74	0.062
UL-Eplane (mm)	-5.06	1.70	-1.73	1.13	**<0.001***
LL-Eplane (mm)	-3.26	1.79	-1.52	0.84	**0.011***
UL thickness (mm)	-3.71	1.78	-2.60	1.65	0.156
LL thickness (mm)	0.88	2.19	0.38	1.60	0.559
Chin thickness (mm)	3.51	1.28	1.18	1.99	**0.001***
Mx1 exposure (mm)	-4.42	1.45	-3.31	2.30	0.199

*Statistically significant at $p < 0.05$.

3 DISCUSSION

3 DISCUSSION

The present study aimed to evaluate the dentoskeletal and tegumental changes in individuals with normal natural occlusion, from the early permanent dentition (T1) to their seventh decade of life (T2). All individuals had lateral cephalograms obtained at 17 and 61 years of age. Longitudinal follow-ups of cephalometric studies are well documented in the literature, providing evidence about craniofacial growth and development (FORSBERG, 1979; BEHRENTS, 1985; SINCLAIR; LITTLE, 1985; BISHARA; TREDER; JAKOBSEN, 1994; FORMBY; NANDA; CURRIER, 1994; WEST; MCNAMARA, 1999; PECORA; BACCETTI; MCNAMARA, 2008). However, collecting longitudinal data is a difficulty of this type of study.

Important changes were observed from 17 to 61 years of age. Like was already reported by Behrents and other studies, the craniofacial complex continues to change even in adulthood (BEHRENTS, 1985; BISHARA; TREDER; JAKOBSEN, 1994). Our results showed that several variables were influenced by the aging process, but the most remarkable changes were noted in the soft tissues. Overall, there was maxillary and symphysis anterior displacement, increase of the ramus height, counterclockwise rotation of the occlusal, palatal and mandibular planes, decrease of the upper facial height and maxillary first molar mesial angulation and extrusion. Soft tissue changes were decrease of the nasolabial angle, retrusion of the lips and flattening of the upper lip, increase of the soft-tissue chin thickness and reduction of the maxillary incisor exposition. Sexual dimorphism was also observed in several variables. The mandibular growth pattern was different for both sexes. Men presented an anterior displacement and rotation of the mandible, with greater increase of the ramus height and reduction of the overjet. On the other hand, women showed a posterior mandibular movement and rotation. Lips retrusion and increased soft-tissue chin thickness were also greater in men.

The clinical applications based on these results are extremely important, since knowledge of the normal changes that occur in the craniofacial complex with aging, specially dentoalveolar and tegumental changes, will serve as a guide to the clinical procedures in the orthodontic treatment, avoiding early aging of the face. Lips retrusion and flattening are reported in previous studies (BEHRENTS, 1985; ZYLINSKI; NANDA;

KAPILA, 1992; BISHARA; TREDER; JAKOBSEN, 1994; FORMBY; NANDA; CURRIER, 1994; WEST; MCNAMARA, 1999; PECORA; BACCETTI; MCNAMARA, 2008). The implication is that orthodontic treatment at earlier ages should not result in an overly straight soft tissue profile and overly retrusive lips, since the expected changes in the relative positions of the lips, nose and chin may exaggerate these characteristics (BISHARA; TREDER; JAKOBSEN, 1994). A large exposure of the maxillary incisors during adolescence should not be a concern during treatment, since the reduction of the maxillary incisor exposition is part of the natural process of aging (BEHRENTS, 1985; FORMBY; NANDA; CURRIER, 1994; DONG et al., 1999; VAN DER GELD; OOSTERVELD; KUIJPERS-JAGTMAN, 2008; VAHDETTIN; ALTUG, 2012).

FINAL CONSIDERATIONS

It is very important to understand what naturally occurs with the craniofacial complex with age, since the aging process might change the skeletal, dentoalveolar and soft tissue structures. This longitudinal study with individuals with normal occlusion showed that significant changes occurred from 17 to the seventh decade of life, and the most remarkable change was noted in the soft tissues.

4 CONCLUSIONS

4 CONCLUSIONS

From 17 to 61 years of age, the changes in the facial soft tissue were more remarkable than dentoskeletal changes. An anterior displacement of both the maxilla and mandible was observed. There was an increase of the ramus height, a counterclockwise rotation of the occlusal, palatal and mandibular planes and a decrease of the upper facial height. Maxillary first molars tipped mesially and extruded. A closure of the nasolabial angle, a retrusion of the upper and lower lips related to soft tissue thickness decrease, an increase of the soft-tissue chin and a reduction of the maxillary incisor exposition were observed. Significant sexual differences were noted during the aging process.

REFERENCES

REFERENCES

Andrews LF. The six keys to normal occlusion. Am J Orthod. 1972 Sep;62(3):296-309.

Behrents RG. A treatise on the continuum of growth in the aging craniofacial skeleton. Ann Arbor: University of Michigan Center of Human Growth and Development; 1984.

Behrents RG. Growth in the aging craniofacial skeleton: Center for Human Growth and Development, University of Michigan; 1985.

Bishara SE, Treder JE, Jakobsen JR. Facial and dental changes in adulthood. Am J Orthod Dentofacial Orthop. 1994 Aug;106(2):175-86.

Bjork A. The significance of growth changes in facial pattern and their relationship to changes in occlusion. Dent Rec (London). 1951 Nov;71(10):197-208.

Bjork A. Facial growth in man, studied with the aid of metallic implants. Acta Odontol Scand. 1955 Jun;13(1):9-34.

Bjork A. Variations in the growth pattern of the human mandible: longitudinal radiographic study by the implant method. J Dent Res. 1963 Jan-Feb;42(1)Pt 2(400-11.

Bjork A, Skieller V. Growth of the maxilla in three dimensions as revealed radiographically by the implant method. Br J Orthod. 1977 Apr;4(2):53-64.

Dong JK, Jin TH, Cho HW, Oh SC. The esthetics of the smile: a review of some recent studies. Int J Prosthodont. 1999 Jan-Feb;12(1):9-19.

Formby WA, Nanda RS, Currier GF. Longitudinal changes in the adult facial profile. Am J Orthod Dentofacial Orthop. 1994 May;105(5):464-76.

Forsberg CM. Facial morphology and ageing: a longitudinal cephalometric investigation of young adults. Eur J Orthod. 1979 1(1):15-23.

Israel H. Age factor and the pattern of change in craniofacial structures. Am J Phys Anthropol. 1973 Jul;39(1):111-28.

Kendrick GS, Risinger HL. Changes in the anteroposterior dimensions of the human male skull during the third and fourth decade of life. Anat Rec. 1967 Sep;159(1):77-81.

Massaro C, Miranda F, Janson G, Rodrigues de Almeida R, Pinzan A, Martins DR, et al. Maturational changes of the normal occlusion: A 40-year follow-up. Am J Orthod Dentofacial Orthop. 2018 Aug;154(2):188-200.

Miranda F, Massaro C, Janson G, de Freitas MR, Henriques JFC, Lauris JRP, et al. Aging of the normal occlusion. Eur J Orthod. 2018 Jun 20.

Pecora NG, Baccetti T, McNamara JA, Jr. The aging craniofacial complex: a longitudinal cephalometric study from late adolescence to late adulthood. Am J Orthod Dentofacial Orthop. 2008 Oct;134(4):496-505.

Richardson ER, Moyers RE. Atlas of craniofacial growth in Americans of African descent: Univ of Michigan Center for; 1992.

Riolo ML. An atlas of craniofacial growth: cephalometric standards from the University School Growth Study, the University of Michigan: Center for Human Growth and Development, University of Michigan; 1974.

Sarnas KV, Solow B. Early adult changes in the skeletal and soft-tissue profile. Eur J Orthod. 1980 2(1):1-12.

Sinclair PM, Little RM. Dentofacial maturation of untreated normals. Am J Orthod. 1985 Aug;88(2):146-56.

Tibana RH, Palagi LM, Miguel JA. Changes in dental arch measurements of young adults with normal occlusion--a longitudinal study. Angle Orthod. 2004 Oct;74(5):618-23.

Vahdettin L, Altug Z. Longitudinal soft-tissue profile changes in adolescent Class I subjects. J Orofac Orthop. 2012 Dec;73(6):440-53.

Van der Geld P, Oosterveld P, Kuijpers-Jagtman AM. Age-related changes of the dental aesthetic zone at rest and during spontaneous smiling and speech. Eur J Orthod. 2008 Aug;30(4):366-73.

West KS, McNamara JA, Jr. Changes in the craniofacial complex from adolescence to midadulthood: a cephalometric study. Am J Orthod Dentofacial Orthop. 1999 May;115(5):521-32.

Zylinski CG, Nanda RS, Kapila S. Analysis of soft tissue facial profile in white males. Am J Orthod Dentofacial Orthop. 1992 Jun;101(6):514-8.

APPENDIX

APPENDIX A - DECLARATION OF EXCLUSIVE USE OF THE ARTICLE IN DISSERTATION/THESIS

We hereby declare that we are aware of the article "Dentoskeletal and tegumental changes in individuals with normal occlusion after a 40-year follow-up" will be included in Dissertation of the student Gabriela Manami Natsumeda and may not be used in other works of Graduate Programs at the Bauru School of Dentistry, University of São Paulo.

Bauru, December 5nd, 2018.

Gabriela Manami Natsumeda
Author

Gabriela Manami Natsumeda
Signature

Daniela Gamba Garib Carreira
Author

Signature

ANNEXES

ANNEX A – Ethics Committee approval, protocol number 71634917.5.0000.5417

USP - FACULDADE DE ODONTOLOGIA DE BAURU DA USP

PARECER CONSUBSTANCIADO DO CEP

DADOS DA EMENDA

Título da Pesquisa: Alterações dentoesqueléticas e faciais em pacientes com oclusão normal após 40 anos de acompanhamento

Pesquisador: Gabriela Manami Natsumeda

Área Temática:

Versão: 2

CAAE: 71634917.5.0000.5417

Instituição Proponente: Universidade de Sao Paulo

Patrocinador Principal: Financiamento Próprio

DADOS DO PARECER

Número do Parecer: 2.976.830

Apresentação do Projeto:

Trata-se de emenda com alteração de título do projeto de pesquisa, inclusão de mais um paciente, com alteração da metodologia reduzindo um tempo de avaliação de imagem radiográfica de banco de imagens da área de ortodontia.

O objetivo desde trabalho será comparar cefalometricamente as alterações dentoesqueléticas e faciais que ocorrem ao longo de 40 anos, em

pacientes com oclusão normal. A amostra obtida será composta por 21 pacientes brasileiros leucodermas com oclusão normal, dentadura

permanente completa, Classe I bilateral de Angle, sem apinhamento e perfil agradável, pertencentes à amostra do Arquivo de Ortodontia da

Faculdade de Odontologia de Bauru, USP. Serão avaliadas telerradiografias tomadas em dois diferentes tempos: T1 (iniciais, aos 17 anos) e T2

(finais, aos 61 anos). As telerradiografias serão digitalizadas e por meio do software Dolphin, serão realizadas 39 medidas cefalométricas. Serão

realizadas sobreposições cefalométricas para avaliação das alterações dentoesqueléticas e faciais. As diferenças interfases serão calculadas pelo

teste t dependente. O nível de significância adotado será de 5%.

Endereço: DOUTOR OCTAVIO PINHEIRO BRISOLLA 75 QUADRA 9
Bairro: VILA NOVA CIDADE UNIVERSITARIA **CEP:** 17.012-901
UF: SP **Município:** BAURU
Telefone: (14)3235-8356 **Fax:** (14)3235-8356 **E-mail:** cep@fob.usp.br

ANNEX A – Ethics Committee approval, protocol number 71634917.5.0000.5417

USP - FACULDADE DE ODONTOLOGIA DE BAURU DA USP

Continuação do Parecer: 2.976.830

Objetivo da Pesquisa:

O presente estudo tem por objetivo avaliar as alterações dentoesqueléticas e faciais de indivíduos com oclusão normal dos 17 aos 61 anos de idade.

Avaliação dos Riscos e Benefícios:

Riscos:

Baixo risco ou risco nulo.

Benefícios:

Os resultados deste estudo contribuirão para elucidar de maneira mais clara e completa, as alterações dentárias, ósseas e tegumentares a longo

prazo em oclusões funcionalmente normais, servindo como referência para as mudanças que podem ocorrer no complexo craniofacial ao longo dos anos, podendo influenciar no planejamento e metas terapêuticas dos tratamentos ortodônticos em pacientes adultos.

Comentários e Considerações sobre a Pesquisa:

Trata-se de emenda com alteração de título do projeto de pesquisa, inclusão de mais um paciente, com alteração da metodologia reduzindo um tempo de avaliação de imagem radiográfica de banco de imagens da área de ortodontia.

Considerações sobre os Termos de apresentação obrigatória:

A emenda, folha de rosto, projeto e dados na plataforma brasil foram inseridos de acordo com a modificação.

Os pesquisadores informam que a pesquisa tem risco baixo ou nulo, mas não citam quais, e reafirmamos que não existe risco nulo.

Recomendações:

Solicito ao pesquisador que insira a seguinte informação nos riscos da PB:

Os riscos desta pesquisa são a perda de sigilo dos dados dos pacientes, extravio de informações digitais de imagens radiográficas dos pacientes.De acordo com a RESOLUÇÃO Nº 466, DE 12 DE DEZEMBRO DE 2012 do MS, Item II.22

Conclusões ou Pendências e Lista de Inadequações:

Inseridos os riscos de acordo com a sugestão não há impedimento para aprovação da emenda do projeto de pesquisa.

Considerações Finais a critério do CEP:

A emenda apresentada pelo(a) pesquisador(a) foi considerada APROVADA na reunião ordinária do CEP de 10/10/2018, com base nas normas éticas da Resolução CNS 466/12. Ao término da

Endereço: DOUTOR OCTAVIO PINHEIRO BRISOLLA 75 QUADRA 9
Bairro: VILA NOVA CIDADE UNIVERSITARIA **CEP:** 17.012-901
UF: SP **Município:** BAURU
Telefone: (14)3235-8356 **Fax:** (14)3235-8356 **E-mail:** cep@fob.usp.br

ANNEX A – Ethics Committee approval, protocol number 71634917.5.0000.5417

USP - FACULDADE DE ODONTOLOGIA DE BAURU DA USP

Continuação do Parecer: 2.976.830

pesquisa o CEP-FOB/USP exige a apresentação de relatório final. Os relatórios parciais deverão estar de acordo com o cronograma e/ou parecer emitido pelo CEP. Alterações na metodologia, título, inclusão ou exclusão de autores, cronograma e quaisquer outras mudanças que sejam significativas deverão ser previamente comunicadas a este CEP sob risco de não aprovação do relatório final. Quando da apresentação deste, deverão ser incluídos todos os TCLEs e/ou termos de doação assinados e rubricados, se pertinentes.

Este parecer foi elaborado baseado nos documentos abaixo relacionados:

Tipo Documento	Arquivo	Postagem	Autor	Situação
Informações Básicas do Projeto	PB_INFORMAÇÕES_BÁSICAS_1221837_E1.pdf	19/09/2018 17:00:23		Aceito
Outros	carta_encaminhamento.pdf	19/09/2018 16:52:42	Gabriela Manami Natsumeda	Aceito
Projeto Detalhado / Brochura Investigador	Projeto_Atualizado_Gabriela_Natsumeda.pdf	19/09/2018 16:50:31	Gabriela Manami Natsumeda	Aceito
Folha de Rosto	nova_folha_de_rosto.pdf	19/09/2018 16:50:10	Gabriela Manami Natsumeda	Aceito
Declaração de Pesquisadores	declaracao_de_compromisso.pdf	20/07/2017 09:50:07	Gabriela Manami Natsumeda	Aceito
TCLE / Termos de Assentimento / Justificativa de Ausência	Dispensa_TCLE.pdf	20/07/2017 09:49:32	Gabriela Manami Natsumeda	Aceito

Situação do Parecer:
Aprovado

Necessita Apreciação da CONEP:
Não

BAURU, 23 de Outubro de 2018

Assinado por:
Ana Lúcia Pompéia Fraga de Almeida
(Coordenador(a))

Endereço: DOUTOR OCTAVIO PINHEIRO BRISOLLA 75 QUADRA 9
Bairro: VILA NOVA CIDADE UNIVERSITARIA **CEP:** 17.012-901
UF: SP **Município:** BAURU
Telefone: (14)3235-8356 **Fax:** (14)3235-8356 **E-mail:** cep@fob.usp.br

ANNEX B – Patients informed consent exoneration.

Universidade de São Paulo
Faculdade de Odontologia de Bauru

Departamento de Odontopediatria, Ortodontia e
Saúde Coletiva

Bauru, 07 de Julho de 2017.

Dispensa de Termo de Consentimento Livre Esclarecido e Termo de Assentimento

Como parte da documentação solicitada pelo Comitê de Ética em Pesquisa para a avaliação de projetos de pesquisas envolvendo seres humanos, encaminho justificativa para a dispensa de TCLE e Termo de Assentimento no Projeto de Pesquisa ***"Alterações cefalométricas dentoesqueléticas e tegumentares em pacientes com oclusão normal após 40 anos de acompanhamento"*** tendo como Responsável Principal Gabriela Manami Natsumeda, sob orientação da Profa. Dra. Daniela Gamba Garib Carreira.

A pesquisa prevê dispensa de TCLE e Termo de Assentimento, por não ser uma pesquisa que requer participação direta dos indivíduos. Nela se utilizarão dados secundários do arquivo do departamento de Ortodontia, no caso, telerradiografias de indivíduos com oclusão normal que já possuem TCLE assinados autorizando a utilização da documentação para pesquisas.

Atenciosamente,

Gabriela M. Natsumeda

Gabriela Manami Natsumeda
Responsável Principal

Profa. Dra. Daniela Gamba Garib Carreira
Orientadora

Al. Dr. Octávio Pinheiro Brisolla, 9-75 – Bauru-SP – CEP 17012-901 – C.P. 73
e-mail: veragato@fob.usp.br – Fone/FAX (014) 3235-8369
http://www.fob.usp.br