SABRINA HITOMI UYEKITA

Desenvolvimento das glândulas salivares menores: relação morfológica paralela entre a expressão das isoformas de TGF-β e marcadores citoesqueletais da maturação glandular

Dissertação apresentada à Faculdade de Medicina da Universidade de São Paulo para obtenção do título de Mestre em Ciências

Área de Concentração: Dermatologia
Orientadora: Profa. Dra. Silvia Vanessa Lourenço

São Paulo

2009

Dados Internacionais de Catalogação na Publicação (CIP)

Preparada pela Biblioteca da
Faculdade de Medicina da Universidade de São Paulo

Uyekita, Sabrina Hitomi
Desenvolvimento das glândulas salivares menores : relação morfológica paralela entre a expressão das isoformas de TGF-β e marcadores citoesqueletais da maturação glandular / Sabrina Hitomi Uyekita. -- São Paulo, 2009.
Dissertação(mestrado)--Faculdade de Medicina da Universidade de São Paulo. Departamento de Dermatologia.
Área de concentração: Dermatologia.
Orientadora: Silvia Vanessa Lourenço.

Descritores: 1.Fator transformador de crescimento beta 2.Glândulas salivares/crescimento & desenvolvimento 3.Imunoistoquímica 4.Imunofluorescência

USP/FM/SBD-463/09

SABRINA HITOMI UYEKITA

Desenvolvimento das glândulas salivares menores: relação morfológica paralela entre a expressão das isoformas de TGF-β e marcadores citoesqueletais da maturação glandular

Dissertação apresentada à Faculdade de Medicina da Universidade de São Paulo para obtenção do título de Mestre em Ciências

Área de Concentração: Dermatologia
Orientadora: Prof[a]. Dr[a]. Silvia Vanessa Lourenço

São Paulo

2009

DEDICATÓRIA

Dedico este trabalho aos meus pais **Takeshi** e **Marta** e aos meus irmãos **Mika**, **Priscila** e **Hitoshi** pelo amor, apoio e compreensão em todos os momentos.

Ao **Jorge** e **Ruth** por me acolherem e incentivarem sempre.

Ao **Jorginho** pelo amor, companheirismo e estímulo nos momentos mais difíceis. **Você ilumina minha vida**.

"Acredito na eterna importância do lar
como instituição fundamental da sociedade.
Acredito nas possibilidades incomensuráveis de cada menino ou menina.
Acredito na imaginação, confiança, esperanças e ideais
que há no coração de todas as crianças.
Acredito na beleza da natureza, da arte, dos livros e da amizade.
Acredito na satisfação do dever cumprido.
Acredito nas pequenas alegrias domésticas da vida de todos os dias."

Ozora Davis (1866-1931)

AGRADECIMENTO ESPECIAL

À minha orientadora querida **Profa. Dra. Silvia Vanessa Lourenço**, pela amizade, cumplicidade, incentivo, confiança e principalmente carinho durante todos estes anos de convívio.

"O valor das coisas não está no tempo em que elas duram, mas na intensidade com que acontecem. Por isso existem momentos inesquecíveis, coisas inexplicáveis e pessoas incomparáveis."

Fernando Pessoa

AGRADECIMENTOS

À minha estimada colega de pós-graduação **Dirce Mary Correia Lima** pela amizade, estímulo e presteza em todos os momentos que compartilhamos no laboratório.

Aos meus amigos e companheiros de pesquisa **Ricardo Hsieh** e **Fábio Rodrigues Gonçalves de Carvalho** pela amizade e solidariedade nos momentos difíceis.

Ao colega de laboratório **Leonardo Kamibeppu** pela agilidade e dedicação na confecção das lâminas para este estudo.

Ao **Prof. Dr. Antonio Sesso** pela gentileza em ceder o microscópio para a aquisição das imagens para este trabalho.

"Só existem dois dias no ano que nada pode ser feito. Um se chama ontem e o outro se chama amanhã, portanto, hoje é o dia certo para amar, acreditar, fazer e principalmente viver."

Dalai Lama

“O objetivo sempre nos escapa. Quanto maior o progresso, maior o reconhecimento de nossa insignificância. A satisfação está no esforço, não no prêmio. O esforço total é a vitória total.”

Mohandas K. Gandhi

Esta dissertação está de acordo com as seguintes normas, em vigor no momento desta publicação:

Referências: adaptado de *International Committee of Medical Journals Editors* (Vancouver)

Universidade de São Paulo. Faculdade de Medicina. Serviço de Biblioteca e Documentação. *Guia de apresentação de dissertações, teses e monografias*. Elaborado por Anneliese Carneiro da Cunha, Maria Julia de A. L. Freddi, Maria F. Crestana, Marinalva de Souza, Suely Campos Cardoso, Valéria Vilhena. 2a ed. São Paulo: Serviço de Biblioteca e Documentação; 2005.

Abreviaturas dos títulos dos periódicos de acordo com *List of Journals Indexed in Index Medicus*.

SUMÁRIO

LISTA DE ABREVIATURAS E SÍMBOLOS

ºC	graus Celsius
β	beta
µm	Micrômetros
AMH	Hormônio anti-muleriano
BMP	*Bone morphogenetic protein*
BSA	Soro-albumina bovina
CA	Califórnia
CK	Citoqueratina
CK LMW	Citoqueratina de baixo peso molecular
Co-SMAD	*Common-partner* SMAD
DAB 3,3	Diamino-Benzidine
DNA	Ácido desoxirribonucléico
EGF	Fator de crescimento epitelial
FCS	Soro fetal bovino
FGF	Fator de crescimento fibroblástico
g	Grama
kDa	Quilodalton
NH2	Grupo amina
PAS	*Periodic Acid Schiff*
PBS	*Phosphate Buffer Saline*
pH	Potencial hidrogeniônico

RNAm	Ácido Ribonucléico mensageiro
R-SMAD	*Receptor-activared* SMAD
SMA	Actina de músculo liso
SMAD	*Small Mother Against Decapentaplegic*
TGF	*Transforming Growth Factor*
™	*Trade Mark*
Tris-HCl	Tampão de fosfato salino
U.S.A	Estados Unidos da América

LISTA DE FIGURAS

LISTA DE TABELAS

Uyekita SH. Desenvolvimento das glândulas salivares menores: relação morfológica paralela entre a expressão das isoformas de TGF-β e marcadores citoesqueletais da maturação glandular [dissertação]. São Paulo: Faculdade de Medicina, Universidade de São Paulo; 2009. 66p.

RESUMO

A morfogênese das glândulas salivares envolve eventos complexos e coordenados, dependentes da interação epitélio-mesênquima e do micro-ambiente. Fatores de crescimento coordenam vários desses processos biológicos e o fator transformador de crescimento-beta (TGF-β) mostra-se relevante. Utilizando imunoistoquímica e imunofluorescência, a distribuição do TGF-β1, 2 e 3 foi mapeada e sua expressão comparada com a expressão de marcadores de maturação em glândulas salivares humanas obtidas de fetos que tinham entre 4ª e 24ª semanas de vida intra-uterina. O TGF-β1 foi detectado durante a fase pseudoglandular no mesênquima. Nas outras etapas da diferenciação glandular esse fator foi expresso no citoplasma das células acinares até a glândula salivar adulta. O TGF-β2 foi detectado desde o estágio de botão inicial da glândula salivar. Sua expressão foi observada nas células ductais e sua presença aumentada ao longo da diferenciação glandular. O TGF-β3 foi visto durante a fase pseudoglandular das glândulas salivares, inicialmente fraco nas células ductais e foi o único detectado em células mioepiteliais. A troca de subunidades de TGF-β durante a maturação das glândulas salivares sugere mudanças estimuladas durante os complexos estágios de desenvolvimento dessas glândulas. O presente

estudo reafirma essa evidência, e mostra que as subunidades do TGF-β são fatores importantes durante a diferenciação de glândulas salivares.

Descritores: 1. Fator transformador de crescimento beta 2.Glândulas salivares / crescimento & desenvolvimento 3.Imunoistoquímica 4. Imunofluorescência.

Uyekita SH. Developing human minor salivary glands: morphological parallel relation between the expression of TGF-beta isoforms and cytoskeletal markers of glandular maturation [dissertation]. São Paulo: Faculdade de Medicina, Universidade de São Paulo; 2009. 66p.

SUMMARY

Morphogenesis of salivary glands involves complex coordinated events. Synchronization between cell proliferation, polarization and differentiation, which are dependent on epithelial–mesenchymal interactions and on the microenvironment, is a requirement. Growth factors mediate many of these orchestrated biological processes and transforming growth factor-beta (TGF-β) appears to be relevant. Using immunohistochemistry and immunofluorescence, we have mapped the distribution of TGF-β 1, 2 and 3 and compared it with the expression of maturation markers in human salivary glands obtained from fetuses ranging from weeks 4 to 24 of gestation. TGF-β 1 first appeared during pseudoglandular stage in the surrounding mesenchyme and, in the more differentiated stages, was expressed in the cytoplasm of acinar cells throughout the adult gland. The TGF-β 2 was detected since the bud initial stage of the salivary gland. Its expression was observed in ductal cells and increased along gland differentiation. The TGF-β 3 was detected from the pseudoglandular stage of the salivary gland, being weakly expressed on ductal cells, and it was the only factor detected on myoepithelial cells. The data suggest that TGF-β have a role to play in salivary gland development and differentiation.

Descriptors: 1.Transforming growth factor beta 2.Salivary glans / growth & development 3. Immunohistochemistry 4. Immunofluorescence.

1 INTRODUÇÃO

1. INTRODUÇÃO

Durante as últimas décadas, aspectos da biologia básica vêm assumindo importância no estudo das condições fisiológicas, patológicas e do desenvolvimento de diversos tecidos e órgãos. Com relação às glândulas salivares, a busca de critérios diagnósticos mais aprimorados e da compreensão de sua histogênese tem sido objetivo de numerosos estudos. Além disso, diversas teorias foram propostas a respeito da gênese dos tumores que acometem as glândulas salivares, correlacionando a diferenciação das células neoplásicas com o desenvolvimento do segmento glandular de sua provável origem (Eversole, 1971; Regezi; Batsakis, 1977; Batsakis, 1980; Attie; Sciubba, 1981; Batsakis *et al*., 1989; Dardick *et al*., 1990). Entretanto, são raros os trabalhos que analisam o desenvolvimento e a diferenciação das glândulas salivares humanas, estabelecendo uma relação morfológica e funcional com as neoplasias (Gustafsson *et al*., 1988).

A imunoistoquímica, técnica que permite a identificação de antígenos nos tecidos através da utilização de anticorpos específicos, vem sendo utilizada exaustivamente na pesquisa, visando à busca de marcadores protéicos peculiares a cada tecido. Estas pesquisas têm auxiliado sobremaneira o reconhecimento de diversas doenças, representando um avanço no diagnóstico histopatológico (Mcnicol; Richmond, 1998).

No âmbito das glândulas salivares, vários anticorpos específicos têm se mostrado ferramentas úteis para o estudo da diversidade celular e

estágios de diferenciação dos processos neoplásicos, muitas vezes definindo critérios de diagnóstico (Araújo *et al*., 1987; Araújo *et al*., 1988; Carvalho *et al*., 1990; Araújo *et al*., 1991 a, b; Carvalho *et al*., 1993; Freitas; Araújo; Araújo, 1993; Sousa, 1994; Sousa; Araújo, 1994; Crivelini; Araújo, 1995; Loyola *et al*., 1995; Souza *et al*., 1995; Araújo; Sousa, 1996; Loyola; Araújo, 1996; Crivelini; Souza; Araújo, 1997; Figueiredo; Sousa; Araújo, 1997; Jaeger *et al*., 1997; Araújo *et al*., 1999; Araújo *et al*., 2000; Loducca *et al*., 2000).

Nosso estudo, dessa forma, pretende avaliar morfologicamente a participação de fatores de crescimento e comparar sua expressão com marcadores da diferenciação durante os processos de morfogênese das glândulas salivares humanas.

2 REVISÃO DA LITERATURA

2. REVISÃO DA LITERATURA

2.1 O desenvolvimento glandular

As glândulas salivares iniciam seu desenvolvimento a partir de botões epiteliais que se originam do epitélio bucal na vida fetal precoce.

O primórdio da glândula parótida humana aparece entre a 4ª e 6ª semana de vida intra-uterina nas dobras laterais do *estomodeo* (cavidade oral primitiva). A glândula submandibular origina-se do soalho bucal durante a 6ª semana e a sublingual se forma lateralmente ao primórdio da submandibular entre a 7ª e 8ª semana de vida intra-uterina. Todas as glândulas salivares menores formam-se mais tardiamente a partir do epitélio de revestimento de áreas específicas da cavidade bucal (Hand, 1980; Tonge; Luke, 1984; Dale, 1994; Ellis; Auclair, 1996).

Entende-se por processo de morfogênese das glândulas salivares as etapas que levam ao arranjo lobulado, característico desse tecido, enquanto que a diferenciação compreende os processos de amplificação da síntese e armazenamento dos grânulos de secreção. A combinação desses dois processos é denominada de citodiferenciação. Estudos sugerem que os processos de morfogênese e de citodiferenciação das glândulas salivares estão parcialmente ligados, mas são reguladas por processos distintos, sendo que a expressão total de um dos dois processos é modulada ou controlada pela matriz extracelular e por outros fatores (Cutler, 1990).

Segundo Tucker, em revisão de 2007, o desenvolvimento das glândulas salivares pode ser dividido em cinco estágios.

O primeiro estágio **(pré-botão)** envolve a indução da proliferação do epitélio de superfície pelo mesênquima adjacente resultando no espessamento e formação dos botões epiteliais. O botão em crescimento é separado do mesênquima condensado pela lâmina basal secretada pelo próprio epitélio (Bernfield; Banderjee; Cohen, 1972; Hand, 1980; Hiatt; Sauk, 1991; Klein, 1994; Ellis; Auclair, 1996; Tucker, 2007).

O segundo estágio (**botão inicial**) é representado pela formação e crescimento dos cordões epiteliais principais. Nesse estágio observam-se a proliferação das células dos botões formando cordões celulares sólidos, constituídos por duas camadas de células, associados à condensação e proliferação do mesênquima adjacente. Ultra-estruturalmente, as células indiferenciadas que compõem os cordões são caracterizadas como células cubóides irregulares, contendo numerosos ribossomos livres, nucléolos proeminentes, complexo de Golgi e retículo endoplasmático rugoso pouco desenvolvido (Bernifield; Banderjee; Cohen, 1972; Hand, 1980; Cutler, 1990; Hiatt; Sauk, 1991; Klein, 1994; Ellis; Auclair, 1996; Tucker, 2007). Adi e Chisholm em 1994, observaram que as células epiteliais que compõem os cordões sólidos de glândulas submandibulares humanas exibem material PAS (*Periodic Acid Schiff*) positivo no seu interior, indicando já nessa fase precoce a produção de mucina.

O terceiro estágio (**pseudo-glandular**) corresponde à ramificação da porção terminal dos cordões epiteliais e à continuação da diferenciação

glandular. Neste, os cordões epiteliais proliferam rapidamente e ramificam-se em bulbos terminais que são compostos por 10 a 12 células (Tucker, 2007).

O quarto estágio (**canalicular**) corresponde às repetidas ramificações dos cordões epiteliais nas porções terminais formando os lóbulos compostos por um sistema de bulbos ramificados como uma árvore (processo de arborificação). Nesse estágio a cápsula da glândula começa a se formar a partir do mesênquima e circunscreve o parênquima glandular (Bernfield; Banderjee; Cohen, 1972, Hand, 1980; Cutler, 1990; Hiatt; Sauk, 1991; Klein, 1994; Ellis; Auclair, 1996). Ainda nesse estágio ocorre a canalização dos cordões epiteliais com a formação de um orifício criando um tubo ou ducto.

Estudos experimentais indicam duas teorias a respeito do mecanismo de canalização: (1) graus diferentes de proliferação entre camadas externas e internas dos cordões epiteliais, (2) secreção do fluído pelas células ductais, o que aumenta a pressão hidrostática e produz um lúmen junto ao cordão. Tanto a ramificação das estruturas ductais quanto o crescimento dos septos de tecido conjuntivo continuam neste estágio do desenvolvimento (Hand, 1980; Hiatt; Sauk, 1991; Klein, 1994; Ellis; Auclair, 1996; Tucker, 2007).

A citodiferenciação dos tipos celulares específicos das glândulas salivares parece ser iniciada após as características de arborificação estarem estabelecidas, e corresponde ao quinto estágio (**botão terminal**) (Cutler, 1990; Tucker, 2007). Esse estágio representa a diferenciação morfológica das glândulas salivares em desenvolvimento. Durante esse

período a atividade mitótica ao invés de ocorrer em todo o cordão epitelial, irá ocorrer apenas na porção terminal do bulbo, aonde as células irão se diferenciar em células dos túbulos terminais e pró-acinares. Com a formação dos lúmens nos bulbos terminais, ocorrem fissuras nas células circunjacentes fazendo com que cada bulbo terminal fique dividido em várias subunidades constituídas por duas camadas de células circundando um lúmen e que são chamadas de túbulos terminais. Nesta fase as unidades da porção terminal luminal estão pouco diferenciadas para serem chamadas de ácinos e são conhecidas como sacos terminais. Acredita-se que as células externas originem as células mioepiteliais e basais enquanto que as células internas sofrem diferenciação para acinares e luminais (Klein, 1994; Ellis; Auclair, 1996).

As células mioepiteliais provavelmente são originadas das células epiteliais externas localizadas nos túbulos terminais e desenvolvem-se concomitantemente com a citodiferenciação das células acinares. A diferenciação das células mioepiteliais está caracterizada pela agregação de microfilamentos e demonstração imunoistoquímica da actina, miosina e filamentos intermediários de pré-queratina (Yaku, 1983; Klein, 1994).

A maturação das células acinares ocorre em estágios específicos classificados de acordo com a morfologia dos grânulos de secreção e das organelas celulares, sendo diferente entre os ácinos mucosos e serosos. O primeiro sinal de diferenciação dos sacos terminais em ácinos está relacionado com o aumento da dilatação das cisternas do retículo endoplasmático rugoso pelas proteínas secretórias, seguido da observação

de grânulos secretórios agranulados e presença de complexo de Golgi funcional. Progressivamente, as quantidades de retículo endoplasmático rugoso, Golgi e grânulos secretórios vão aumentando com a maturação dos ácinos (Yaku, 1983; Klein, 1994).

Os ductos excretores das glândulas salivares diferenciam-se a partir dos cordões principais: as ramificações distais dos cordões principais originam os grandes ductos estriados, enquanto que os ductos intercalares, pequenos ductos estriados, células secretoras e mioepiteliais originam-se das células dos túbulos terminais. A diferenciação dos ductos excretores e estriados maiores ocorre apenas após os cordões celulares sólidos terem sofrido canalização (Hand, 1980; Dale, 1994; Ellis; Auclair, 1996; Denny; Ball; Redman, 1997).

Os estímulos provenientes dos mecanismos secretores e da inervação da glândula são responsáveis pela continuação e maturação durante a citodiferenciação, porém a glândula será totalmente formada no período pós-natal. Este desenvolvimento pós-natal está relacionado com: (1) a maturação do estímulo de secreção, que é responsável pela ativação dos receptores de membrana que sinalizam caminhos de transdução de sinal junto à célula e controlam a secreção das células; e com (2) o estabelecimento de conexões neurais do sistema nervoso autônomo, que é o primeiro regulador da função das glândulas salivares (Hand, 1980; Lee *et al*., 1990; Klein, 1994; Ellis; Auclair, 1996).

Como resultado do processo de desenvolvimento acima descrito as glândulas salivares tomam a forma de estrutura composta túbulo-acinar, o

que indica a presença de um sistema ductal ramificado e unidades secretoras com porção tubular e acinar. Essas glândulas são exócrinas, cujas secreções fluem para o interior da cavidade bucal.

Histologicamente, as glândulas salivares possuem três tipos de porção secretora: mucosas, serosas e mistas, e três tipos de ductos: intercalado, estriados (intralobulares) e excretor (interlobular). As principais células encontradas são as células mucosas, células serosas e as mioepteliais. Circundando e fornecendo suporte para os sistemas ductal e secretor existe uma cápsula de tecido conjuntivo denso que se estende na glândula formando septos dividindo o parênquima em lóbulos. O tecido conjuntivo é importante tanto para a sustentação das glândulas como dos nervos (autônomos), vasos sanguíneos e linfáticos (Bhaskar, 1978; Hand, 1980; Klein, 1994; Tonge; Luke, 1994; Ellis; Auclair, 1996).

As diversas estruturas das glândulas salivares completamente desenvolvidas possuem características fenotípicas, protéicas e moleculares peculiares, podendo ser identificadas por técnicas de detecção de proteínas marcadoras específicas, como a imunoistoquímica. Dessa forma, subunidades de citoqueratinas identificam os diversos segmentos epiteliais das glândulas salivares e as células mioepiteliais podem ser detectadas pela expressão de proteínas contráteis como, por exemplo, a actina de músculo liso (Dardick *et al*., 1988; Araújo; Carvalho; Araújo, 1994).

No total, após toda a sua formação, as glândulas salivares são compostas de: (1) glândulas maiores, que compõe todo o conjunto de parótida, sublingual e submandibular e (2) glândulas menores, que são

nomeadas de acordo com a sua localização como labiais, bucais, linguais, palatinas, gengivais e glossopalatinas (Bhaskar, 1978; Hand, 1980, Klein, 1994).

A Figura 1 exemplifica os estágios da morfogênese das glândulas salivares humanas e a Figura 2 mostra esquematicamente a estrutura de uma glândula salivar completamente desenvolvida.

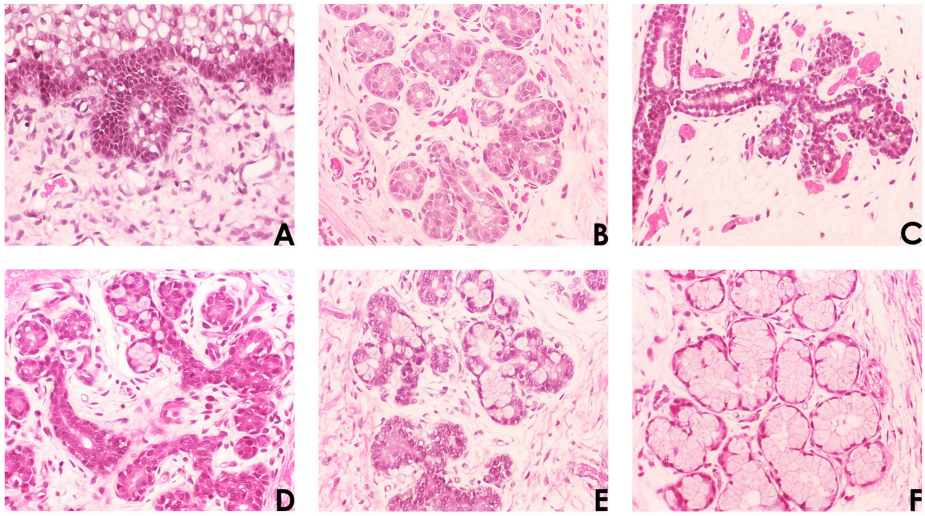

FIGURA 1

Figura 1 – Estágios de diferenciação das glândulas salivares.

A: Fase de pré-botão composto por células de aspecto basalóide e indiferenciado (hematoxilina/eosina).

B: Cordões epiteliais ramificados e presença de algumas estruturas exibindo início de lúmen central (hematoxilina/eosina).

C: Cordões epiteliais ramificados e canalizados (hematoxilina/eosina);

D: Ducto excretor canalizado e exibindo estratificação epitelial (hematoxilina/eosina).

E: Início da fase canalicular com presença de sacos terminais rudimentares (hematoxilina/eosina).

F: Glândula salivar mucosa: fase terminal de botão com estruturas acinares morfologicamente diferenciadas, com células de citoplasma amplo e claro e aspecto piramidal (hematoxilina/eosina).

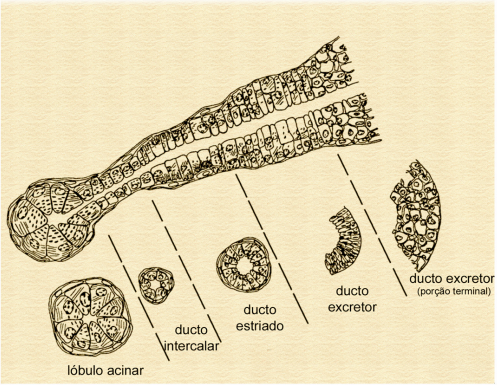
ducto excretor
(porção terminal)
ducto
excretor
ducto
estriado
ducto
intercalar
lóbulo acinar

Figura 2

Semelhante a outros órgãos, a formação das glândulas salivares envolve um mecanismo morfogenético de coordenação, incluindo mudanças reguladas na forma celular, expressão de genes, e migração celular direcionada levando a um completo desenvolvimento glandular com importantes funções secretoras. Apesar dos locais e do tempo de desenvolvimento diferir significativamente entre as diversas glândulas, o processo envolvido no desenvolvimento é similar e sofre influências de fatores extrínsecos e intrínsecos que regulam o processo de morfogênese, proliferação e diferenciação celular.

Os fatores intrínsecos são definidos como características pré-programadas da expressão genética específica para cada tipo celular. Durante seqüência programada, os genes são ativados e desativados em tempos apropriados levando ao crescimento e diferenciação normal das células (Cutler, 1990; Klein, 1994; Denny; Ball; Redman, 1997).

Os fatores extrínsecos são sinais produzidos pela interação célula-célula e célula-matriz-extracelular. Dessa forma, o desenvolvimento do tecido glandular envolve interações entre o epitélio e o mesênquima para formar a porção funcional da glândula (parênquima). Essas interações são definidas como induções secundárias, nas quais a presença do mesênquima torna-se necessária para o desenvolvimento normal do epitélio. O mesênquima é composto por células derivadas do mesoderma e da crista neural e tem sido chamado de ectomesênquima ou mesoectoderma. Portanto, o ectomesênquima possui papel essencial no desenvolvimento do tecido glandular humano visto que, sua interação com o epitélio regula tanto

a iniciação como o crescimento e a citodiferenciação das células do tecido glandular (Hand, 1980; Azuma; Sato, 1994; Klein, 1994; Denny; Ball; Redman, 1997).

A posição e forma dos órgãos são determinadas pela atividade coordenada de um grupo de células primitivas umas com outras e com células vizinhas. Embora as informações disponíveis sejam limitadas de como essas atividades são coordenadas, a expressão de ligantes e receptores específicos de superfície celular são altamente relacionadas em uma rede complexa de sinalização, a qual regula a divisão celular, migração e diferenciação (Thiery, 2003).

Dentre as principais citocinas envolvidas em processos de diferenciação celular está o TGF-β.

2.2 Fator transformador de crescimento – beta (TGF-β)

O TGF-β (fator transformador de crescimento-beta) é uma citocina multifuncional de 25 kDa que faz parte da "Superfamília dos TGF-β" composta por TGF-β, activinas, inhibinas, hormônio anti-mulleriano (AMH), proteína morfogenética óssea (BMP do inglês *bone morphogenetic protein*), miostatina e outros que secretam polipeptídeos sinalizadores com diversas funções no desenvolvimento celular e na homeostase de tecidos adultos em todos os metazoários (Sporn; Roberts, 1990; Piek; Heldin; Ver Dijke, 1999; Chin *et al*., 2004).

A família de TGF-β é composta por oito membros verdadeiros, que compartilham entre si uma vasta seqüência homóloga de aminoácidos englobados na "Superfamília dos TGF-β" (Millan *et al*., 1991). Conforme cita Chin *et al*. (2004), estas proteínas atuam na regulação da proliferação, diferenciação e apoptose de vários tipos celulares.

2.2.1 A estrutura do TGF-β

Clones de DNA complementar foram isolados em cinco tipos de TGF-β (TGF β1-5), entretanto, clones de DNA purificado ou recombinante estavam presentes somente nos tipos 1 ao 3 (Derynck, 1985; Derynck *et al*., 1988; Madisen *et al*.,1988; Ten Dijke *et al*., 1988).

Além disso, somente nos tipos de 1 a 3 foram encontrados em mamíferos. Suas estruturas moleculares são semelhantes e cada polipeptídeo é sintetizado como uma pró-proteína monomérica que é clivada produzindo um polipeptídeo de 112 aminoácidos que se mantém associado com a porção molecular latente (Revisão de Lyons; Moses, 1990; Miller *et al*., 1990).

Geralmente, a região desenvolvida da proteína TGF-β3 possui 80% de semelhança com os tipos protéicos TGF-β1 e TGF-β2, além disso, a porção NH2-terminal ou região promotora dessas três moléculas participa em apenas 27% da seqüência homóloga (Derynck *et al*., 1988; ver Dijke *et al*., 1988).

Encontram-se vários membros dessa superfamília em uma larga variedade de seres vivos como insetos, anfíbios, aves e seres humanos (Derynck *et al*., 1985; Padgett; Johnston; Gelbart, 1987; Weeks; Melton, 1987). Além disso, os três tipos de TGF-β apresentam padrão celular específico em vários estágios do desenvolvimento e uma grande variedade de tecidos expressa esta proteína (Pelton *et al*., 1991). O TGF-β media

várias interações célula-célula durante o período embrionário (Mercola; Stiles, 1988; Whitman; Melton, 1989; Nilsen-Hamilton, 1990).

A sinalização do TGF-β via receptor serina/tirosina kinase é realizada por meio do receptor tipo I ou tipo II, que são glicoproteínas de peso molecular aproximado de 55 kDa e 70 kDa respectivamente. Estes formam complexos ativos com ligantes celulares da membrana celular que são resultados da ação de kinases inativas com receptores do tipo I. Este ligante então fosforila e ativa membros da família SMAD (do inglês *Small Mother Against Decapentaplegic*) denominados de R-Smads (do inglês *receptor-activated* Smads), que incluem Smad 2 e Smad 3 no caso do TGF-β. O R-Smad ativado forma oligômeros com um único Co-Smad (do inglês *common-partner* Smads), o tipo Smad4, e rapidamente transloca-se para o núcleo associados com outros fatores de transcrição e regulam a expressão do gene alvo. Desse modo, os Smads transferem informações para o núcleo a fim de controlar a expressão específica de genes que podem manifestar uma multifuncional fisiologia do TGF-β. Os Smads são divididos em três subclasses baseados nas funções que desempenham: R-Smad – receptor-ativador de Smad, Co-Smad – parceiro comum de Smad e anti-Smad – inibidor de Smad (Engel; Datta; Moses, 1998; Massagué, 1998; Wrana, 1998; Piek; Heldin; Ver Dijke, 1999).

No geral, os TGF-βs 1, 2 e 3, apresentam ações qualitativamente similares quando presentes em culturas de células e estudos comparativos sugerem que essas proteínas interagem com os mesmos agentes de superfície celular (Graycar *et al*., 1989), embora em muitos tipos celulares

exista uma determinada isoforma de TGF β que preferencialmente estimula cada conjunto de receptor pré- estabelecido (Segarini, 1990).

Cada TGF-β possui uma diversidade biológica e muitas diferenças são observadas *in vitro* e *in vivo* (Ohta *et al*., 1987; Jennings *et al*., 1988; Rosa *et al*., 1988; Merwin *et al*., 1991; Piek; Heldin; Ver Dijke, 1999).

In vitro o TGF-β é mitogênico para células que derivam do tecido de suporte como o ósseo e o cartilaginoso e é inibidor para outros vários tipos celulares. Ele estimula a deposição de matriz extracelular, a quimiotaxia de certas células e induz a formação o mesoderma durante o início da embriogênese (Lehnert; Akurst, 1988; Pelton *et al*., 1989, 1990 a, b; Akhurst *et al*., 1990; Fitzpatrick *et al*., 1990; Miller *et al*., 1990; Millan *et al*., 1991; Schmid *et al*., 1991).

In vivo o TGF-β apresenta padrões de resposta diferentes para cada isoforma. Estudos realizados em ratos deficientes para a molécula de TGF-β 1, apresentaram morte pós-natal precoce, com quadro de vasta inflamação linfocitária e macrófagos em vários órgãos, ratos com falta de TGF-β 1, por sua vez, exibiram morte *in útero* devido a defeitos no sistema vascular e hematopoiético e ratos com total ausência de TGF-β 1 e nascidos de mães deficientes para a molécula de TGF-β 1, revelaram malformações cardíacas. Ratos *knockout* para TGF-β 2, mostraram um panorama de múltiplas malformações em tecidos e órgãos que levaram a morte pré-natal. Ratos *knockout* para TGF-β 3, revelaram atraso no desenvolvimento do pulmão e morte logo após o nascimento (Piek; Heldin; Ten Dijke, 1999).

Ao nível celular, o TGF-β inibe a proliferação do epitélio, endotélio e de células hematopoiéticas, regula a diferenciação do sistema imune, neural, mesênquima e células epiteliais e modulam a suas respostas apoptóticas (Brown; Patil; Home, 2000; Massagué, 2000). Possui ação de estimular e inibir a replicação celular e controlar a produção de várias matrizes extracelulares (Chin; Boyle; Parsons, 2004).

Pelton *et al*. (1991), estudaram em embriões de ratos a expressão de TGF-β usando isoformas de anticorpo específicas para cada TGF-β (1-3) e comparando a distribuição dessas proteínas com seus respectivos mRNAs. Nesse estudo foi avaliado a expressão do TGF-β mRNA transcriptase em um determinado tecido embrionário e a proteína TGF-β foi freqüentemente localizada em muitos tipos celulares como o mRNA, mas em muitos casos também o mRNA foi relacionado com a indicação de complexos padrões de transcrição, translocação e secreção para o TGF-βs 1-3 em embriões de camundongos. Isto também indica que o TGF-β1, β2 e β3 atuam em ambos os mecanismos (autócrino e parácrino), durante a embriogênese dos mamíferos. Os resultados obtidos mostram que o TGF-β é expresso num tempo único e num padrão específico em uma ampla gama de tecidos embrionários, sugerindo que esses fatores desempenham várias funções durante a morfogênese e organogênese.

Pelton *et al*. (1991), ainda observaram a presença do TGF-β em vários tecidos como, por exemplo: cartilagem, osso, dente, músculo, coração, tecido vascular, pulmão, rim, intestino, fígado, olhos, ouvido, pele e tecido nervoso, e sua manifestação pode ser individual ou em grupo (TGF-β 1, 2 e

3). Além disso, os três tipos de proteína de TGF-β demonstram ação célula-específica no padrão de expressão em vários estágios do desenvolvimento e uma larga variedade de expressão epitelial, representando as lâminas germinativas embrionárias. Por exemplo, a localização específica do TGF-β1 foi observada nas fibras da ocular dos olhos (epitélio), o TGF-β2 foi visto no córtex da glândula adrenal (mesoderma) e o TGF-β3 no epitélio da cóclea do ouvido interno (endoderma).

Nas glândulas salivares, a importância de fatores de crescimento e diferenciação ainda é obscura, principalmente durante os processos de morfogênese glandular. Nesse âmbito, dois estudos se destacam: Jaskoll e Melnick (1999) mostraram que diversas vias de sinalização, incluindo a do TGF-β e seus receptores estão relacionadas com a progressão dos estágios de desenvolvimento das glândulas submandibulares de ratos; Patel, Rebustini e Hoffman (2006), mostraram que outros fatores de crescimento, como por exemplo, os fatores de crescimento fibroblásticos (FGF do inglês *Fibroblastic Growth Factor*) e fatores de crescimento epidérmicos (EGF do inglês *Epidermic Growth Factor*) têm papel central nos estágios pseudoglandular e de canalização das glândulas salivares de murinos.

Considerando a crescente importância em se compreender o papel desses diversos fatores na orquestração do desenvolvimento glandular, este trabalho se propõe a responder a seguinte questão: Qual a participação de componentes da família do TGF-β na morfogênese das glândulas salivares humanas.

A análise morfológica da expressão desses fatores em espécimes de glândulas salivares humanas poderá responder parcialmente essa questão, nos oferecendo importantes subsídios para a compreensão do complexo mecanismo da morfogênese glandular.

3 OBJETIVOS

3. OBJETIVOS

3.1 GERAIS

Fundamentados em resultados preliminares do nosso grupo de pesquisa que apontam importante participação de fatores do micro-ambiente no desenvolvimento das glândulas salivares humanas nos propomos a aprofundar nossos estudos, investigando a expressão das isoformas de TGF-β em espécimes de glândulas salivares em desenvolvimento, derivados de fetos humanos em variados estágios gestacionais.

3.2 ESPECÍFICOS

- Analisar, por meio da imunoistoquímica, a localização morfológica das subunidades de TGF-β durante as diversas etapas da morfogênese das glândulas salivares humanas.
- A expressão do TGF-β será comparada com marcadores da diferenciação glandular.

4 MATERIAL E MÉTODO

4. MATERIAL E MÉTODOS

4.1 Obtenção e seleção de fetos humanos para dissecação de estruturas glandulares

Trinta fetos humanos provenientes de abortos legais, pesando até 500g e com idades, entre a 4ª e a 24ª semana de gestação e submetidos a exame de verificação de óbito foram utilizados em nosso estudo. Esse material foi coletado na Divisão de Anatomia Patológica do Hospital das Clínicas da Faculdade de Medicina da Universidade de São Paulo (em conformidade com a autorização do Comitê de Ética desta Instituição). Espécimes macerados e em mau estado de preservação foram excluídos da amostra. Também foram descartados fetos que apresentavam aberrações ou que sabidamente possuíam algum tipo de alteração genética. As idades gestacionais dos fetos foram determinadas por meio da medida plantar segundo Mc Bride, Baillie e Polland (1984).

Estudo anatômico da face fetal foi realizado para haver maior precisão durante a dissecção com melhor aproveitamento das estruturas glandulares.

As estruturas orais e glandulares foram então dissecadas com instrumentos cirúrgicos com o intuito da máxima preservação das estruturas e órgãos, do ponto de vista anatômico e histopatológico. Todas as estruturas

dissecadas foram então catalogadas de acordo com a idade fetal e localização anatômica ou órgão e processadas histologicamente para posterior análise em microscopia óptica para identificação das estruturas glandulares e determinação de sua fase de desenvolvimento.

Nos fetos em fase mais precoce de desenvolvimento, cuja anatomia facial ainda não permitia separação por estruturas, a dissecção se procedeu "*en bloc*", separando-se toda a porção inferior da face para processamento.

Em geral, foram dissecadas as seguintes estruturas:

- Mucosa jugal
- Lábios superior e inferior
- Palato
- Mandíbula
- Língua
- Soalho bucal

4.2 Processamento histológico

Todo o material dissecado foi processado histologicamente e posteriormente incluído em blocos de parafina. Cortes histológicos de 5μm de espessura foram realizados e estes foram corados em hematoxilina e eosina para checagem das estruturas glandulares presentes.

Para facilidade da análise de nosso estudo, as estruturas glandulares encontradas foram classificadas segundo o estágio de diferenciação das glândulas salivares, baseados em revisão de Tucker de 2007, a saber:

- Fase de pré – botão
- Fase de botão inicial
- Fase pseudoglandular
- Fase canalicular
- Fase de botão terminal

Espécimes de glândulas salivares totalmente desenvolvidos foram obtidos nos arquivos do Laboratório de Dermatopatologia da mesma instituição e foram utilizados como controle. Todos os espécimes foram fixados em formalina 10% tamponada por 24 horas e embebidos em parafina. Lâminas coradas pela técnica histoquímica de hematoxilina e eosina foram utilizadas para verificar a presença de glândulas salivares e estudar a sua morfologia. Aqueles que apresentaram glândulas salivares menores desenvolvidas foram selecionados para o presente estudo.

4.3 Imunoistoquímica

Cortes de 4μm dos espécimes selecionados foram desparafinizados em dois banhos de xilol: o primeiro a 60°C por 30 minutos e o segundo a temperatura ambiente por 20 minutos. A seguir os cortes foram re-hidratados em cadeia descendente de etanol (100%, 95% respectivamente) e imersos em solução de hidróxido de amônia a 10% durante 10 minutos para a remoção de pigmentos formólicos.

Recuperação dos sítios antigênicos ocorreu com a incubação dos cortes com pepsina a 0,5% em PBS a 37ºC pH 1,8 por 30 minutos.

Os cortes foram então lavados em água corrente e em seguida em água destilada, e incubados em solução aquosa de peróxido de hidrogênio a 3% por 10 minutos com o intuito de bloquear a peroxidase endógena tecidual.

Repetida a lavagem com água corrente e com água destilada, os cortes foram imersos duas vezes em solução de PBS pH 7,4 por dois minutos cada.

Em seguida, os cortes foram incubados com soro primário diluído em solução de 1% BSA em PBS pH 7,4 por 12 horas. Os anticorpos primários utilizados foram policlonais anti-coelho TGF-β 1 (clone sc -146), TGF-β 2 (clone sc – 90) e TGF-β 3 (clone sc – 82) (Santa Cruz Biotechnology – Santa Cruz, CA, U.S.A.). A concentração utilizada foi de 1:150 para os três

anticorpos. A reação seguiu com a incubação com um sistema de detecção indireta de polímeros (En Vision – Dako, Carpinteria, CA, U.S.A.).

A revelação da reação foi concluída com o cromógeno DAB (3`3 tetracloreto de diaminobenzidine) por 3 minutos. A contra-coloração foi realizada com hematoxilina de Mayer. Seguiu-se a desidratação e montagem das lâminas com lamínula de vidro e resina permount.

Controles negativos foram obtidos substituindo os anticorpos primários com soro não imune.

Controles positivos internos foram considerados de acordo com a recomendação do fabricante. Todas as reações de imunoistoquímica foram realizadas em triplicata.

4.4 Imunofluorescência

Cortes histológicos de 3μm de espessura dos espécimes foram submetidos à reação de imunofluorescência utilizando o seguinte protocolo:

Desparafinização com dois banhos de 30 minutos em xilol a 60 °C, em seguida mais dois banhos de 10 minutos em xilol a temperatura ambiente. Seguiu-se a incubação em cadeia descendente de álcoois (álcool 100% dois banhos de 2 minutos, álcool 95% dois banhos de dois minutos). A seguir, passou-se para a remoção dos pigmentos formólicos (solução de

álcool 95% com hidróxido de amônia 10%) durante vinte minutos. Para a remoção dos resíduos de xilol e hidróxido de amônia os cortes foram submetidos à lavagem em água corrente por dez minutos e cinco minutos em água destilada.

A recuperação antigênica foi realizada com ácido cítrico pH 6,0 em micro-ondas. Os cortes foram novamente lavados em água corrente durante 10 minutos e em água destilada por 5 minutos para a remoção dos resíduos das soluções tampão utilizados na etapa de recuperação antigênica.

Lavagem com tampão Tris-HCl pH 7.4 por 5 minutos foi realizada para em seguida realizar a incubação dos cortes com os anticorpos primários diluídos em solução de PBS-BSA. Os anticorpos primários utilizados, clone, procedência e diluição encontram-se listados na tabela 1. A incubação foi realizada em câmara úmida e armazenada a 4ºC por 12 horas.

A continuação da reação seguiu-se com a lavagem dos cortes em solução de Tris-HCl pH7.4 durante 15 minutos.O trabalho realizado a partir dessa etapa foi realizado em ambiente escuro para que com isso fosse minimizada a perda da fluorescência do anticorpo secundário. Seguiu-se então a incubação com o anticorpo secundário (anti-IgG marcado com o cromógeno fluorescente fluoresceína) por 60 minutos em câmara úmida escura a 4ºC. O anticorpo secundário foi diluído em solução de PBS-BSA.

Após a incubação os cortes foram lavados em solução de Tris-HCl pH 7,4 por 10 minutos preparando os cortes para a segunda marcação que foi efetuada com a incubação dos cortes com um segundo anticorpo primário. Realizamos a incubação com o segundo anticorpo primário diluído em

solução tampão de PBS-BSA por 60 minutos em câmara úmida escura a 4ºC.

Passado o período de incubação, os cortes foram novamente lavados em solução de Tris-HCl pH 7,4 por 10 minutos. Procedeu-se então a incubação com o segundo anticorpo secundário (anti IgG marcado com o cromógeno rodamina), também diluído em tampão PBS-BSA por 60 minutos em câmara úmida escura a 4ºC. Após o período de incubação os cortes foram mais uma vez lavados com solução de Tris-HCl pH 7,4 e 5 lavagens de 2 minutos com água destilada para que com isso diminuíssemos a quantidade de precipitado decorrente de resíduos de sais e dos anticorpos secundários.

Após as lavagens, os cortes foram montados com o agente de montagem Vecta Shield™ (*Vector Laboratories Incorporation*, CA, U.S.A) e lamínula de vidro.

O controle negativo foi realizado com a substituição do anticorpo primário e secundário por solução tampão (PBS-BSA, pH 1,8).

Tabela 1 - Os anticorpos primários utilizados, clone, procedência e diluição

soro primário	clone	origem	recuperação antigênica	diluição
CK 14	ll 002	Neomarker	ácido cítrico ph 6,0	1:50
CK low-MW	35 βh 11	DAKO	ácido cítrico ph 6,0	1:50
actina músculo liso	1A4	DAKO	ácido cítrico ph 6,0	1:50

Os resultados foram analisados sob microscópio Zeiss™ equipado com epi-iluminação e filtros de fluoresceína e rodamina e registrados com uma câmera digital (Axiocam-MRC).

Controles positivos internos foram considerados, como por exemplo, epitélio de revestimento e vasos sanguíneos.

5 RESULTADOS

5. RESULTADOS

5.1 Imunoistoquímica e imunofluorescência

Os espécimes estudados foram coletados de glândulas salivares menores em vários estágios de desenvolvimento que estavam na fase de pré-botão, botão inicial, pseudoglandular, canalicular e de botão terminal.

Glândulas salivares que estavam na fase de pré-botão / botão inicial apresentaram resultado negativo para TGF-β 1 (Figura 3 a1). Neste estágio, o TGF-β 2 foi detectado em algumas células (Figura 3 a2), e fraca expressão para o TGF-β 3 foi observada ao redor de células do botão (Figura 3 a3, seta). No estágio de pré-botão / botão inicial, poucas células foram fracamente positivas para a citoqueratina (CK) 14 (Figura 4 a).

Durante a fase de botão inicial / pseudoglandular, ductos das glândulas salivares em desenvolvimento puderam ser observados. TGF-β-1 foi detectado no estroma ao redor de estruturas glandulares em canalização (Figura 3 b1). Células de estruturas rudimentares da glândula na fase pseudoglandular foram fortemente positivas para TGF-β 2 (Figura 3 b2), e o TGF-β 3 foi visto com fraca intensidade no pólo apical de células em contato com o lúmen (Figura 3 b3). Durante este estágio de desenvolvimento a CK 14 e a citoqueratina de baixo peso molecular (CKWL) estavam presente nas

células epiteliais dos ductos. A actina músculo liso (SMA) (em vermelho) foi encontrada somente em raras células (Figura 4 b, c, g, h).

No estágio pseudoglandular / canalicular, o TGF-β 1 foi fortemente expresso no citoplasma de células rudimentares mucosas no final da estrutura glandular em ramificação (Figura 3 c1). Células ductais foram intensamente positivas para TGF-β 2 (Figura 3 c2), e o TGF-β 3 foi fracamente expresso no pólo apical de células luminares em glândulas salivares em desenvolvimento. Além disso, o TGF-β 3 foi positivo ao redor de lóbulos acinares rudimentares nas células mioepiteliais (Figura 3 c3, setas). No estágio pseudoglandular / canalicular, células ductais foram positivas para CK 14 (Figura 4 d). Células do lúmen do sistema ductal em formação foram positivas para CK WML. SMA (em vermelho) foi detectado em células da porção terminal do sistema ductal e em células que estavam ao redor de lóbulos acinares rudimentares (Figura 4 i, j).

Em uma etapa posterior, na fase de botão terminal, o TGF-β 1 foi positivo no citoplasma em poucas células acinares em lóbulos acinares bem desenvolvidos (Figura 3 d1). O TGF-β 2 mostrou forte expressão no citoplasma de células do ducto em todo o sistema glandular (Figura 3 d2.1, seta e também d2.2) e o TGF-β 3 estava presente nas células mioepiteliais ao redor de lóbulos acinares (Figura 3 d3.1). No entanto, uma fraca expressão deste fator foi observada em células dos ductos excretores bem desenvolvidos (Figura 3 d3.2).

No final da citodiferenciação acinar, a CK 14 foi detectada no citoplasma das células basais do sistema ductal. Células mioepiteliais foram

positivas para CK 14 (verde) e SMA (vermelho). A CK LMW foi visto em células do lúmen do sistema ductal (Figura 4 e, f, k, l). Os espécimes de glândulas salivares totalmente desenvolvidas estudadas foram compostos por glândulas menores compostas por unidades secretoras mucosas, células mioepiteliais e ductos intercalados, estriados e excretores. O TGF-β 1 foi intensamente expresso no citoplasma de células acinares mucosas e TGF-β 2 e 3 foi detectado em células epiteliais do sistema ductal (Figura 3 a, b, c).

A análise semi-quantitativa da expressão das isoformas de TGF-β em glândulas salivares adultas e em desenvolvimento foi apresentado e classificado de acordo com a intensidade da marcação imunoistoquímica em negativo (0), fraco (+), moderado (++) e forte (+++). Estes resultados estão ilustrados na Tabela 2

A figura 3 ilustra a presença do TGF-β nas diversas fases de desenvolvimento das glândulas salivares humanas e a figura 4 mostra o padrão de expressão dos marcadores citoesqueletais e os períodos de sua expressão.

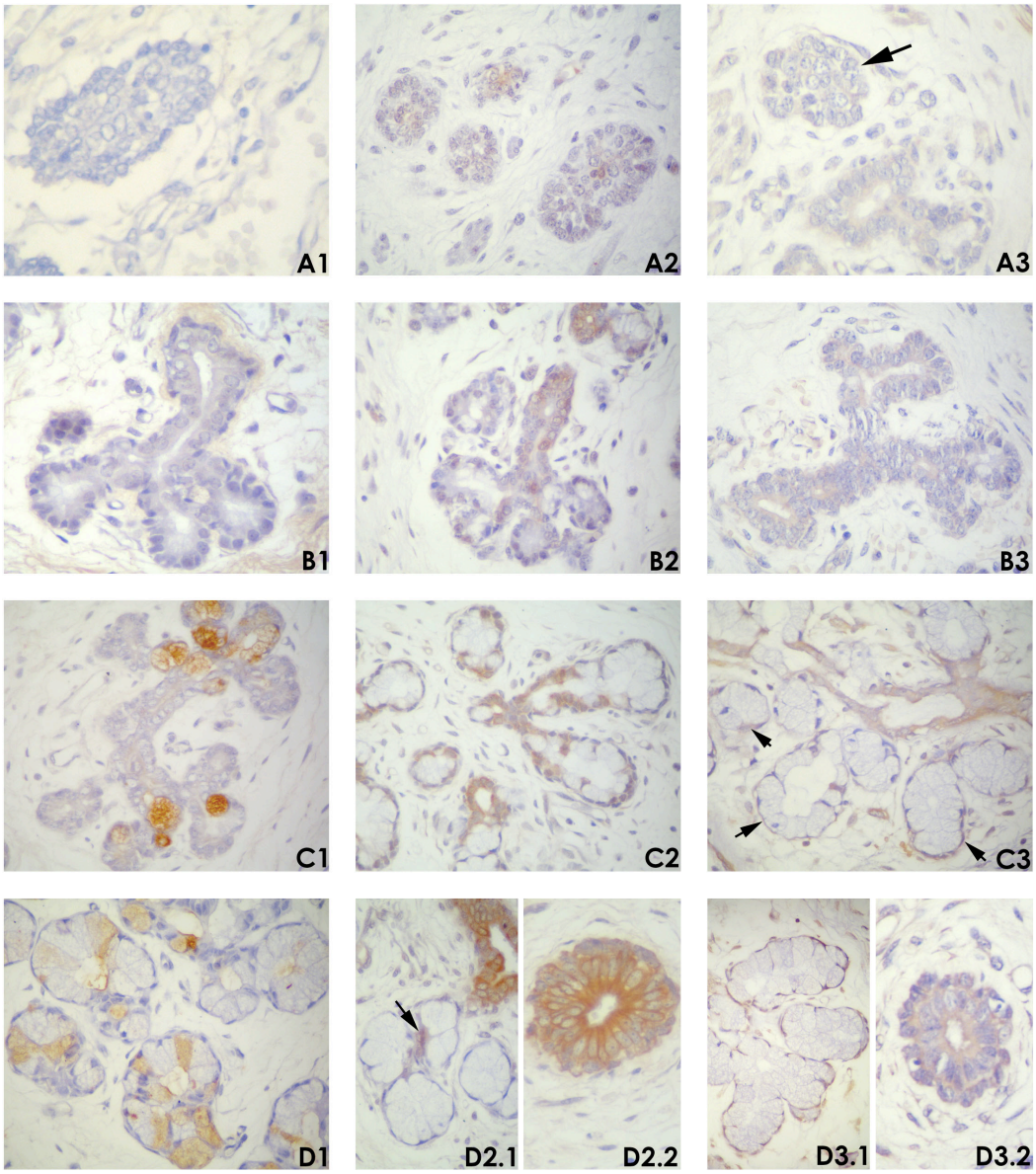

Figura 3

Figura 3 – Expressão das isoformas de TGF-β durante o desenvolvimento das glândulas salivares humanas.

Fase de pré-botão / botão inicial (a1) (a2) (a3) (a1) Não há nenhuma evidência de manifestação de TGF-β1 nas células epiteliais na fase inicial da glândula salivar em desenvolvimento (estreptavidina peroxidase ampliação original 400x). (a2) Expressão do TGF-β2 no citoplasma de algumas células do cordão epitelial das glândulas salivares em desenvolvimento (estreptavidina-biotina peroxidase ampliação original 400x). (a3) Fraca expressão de TGF-β3 ao redor das células epiteliais dos brotos da glândula (estreptavidina-biotina peroxidase ampliação original 400x). **Fase pseudoglandular** (b1) (b2) (b3) (b1) Presença de TGF-β1 no estroma em torno do sistema de canais do ducto (estreptavidina peroxidase ampliação original 400x). (b2) O TGF-β2 apresenta forte expressão no citoplasma de células epiteliais do sistema de ductos da glândula salivar (estreptavidina-biotina peroxidase ampliação original 400x). (b3) Fraca expressão do TGF-β3 no pólo luminal das células do sistema ductal (estreptavidina peroxidase ampliação original 400x). **Fase canalicular** (c1) (c2) (c3) (c1) Forte expressão do TGF-β1 no citoplasma de células mucosas em início de desenvolvimento na região apical do ramo em desenvolvimento da glândula salivar (estreptavidina peroxidase ampliação original 400x). (c2) Forte expressão do TGF-β2 no citoplasma de células epiteliais que compõem todo o sistema ductal em ramificação das glândulas salivares, incluindo o ducto

intercalado localizado na junção dos futuros lóbulos acinares (estreptavidina peroxidase ampliação original 400x). (c3) Expressão do TGF-β3 no citoplasma das células epiteliais do sistema ductal e nas células mioepiteliais que envolvem as células mucosas na porção terminal da glândula salivar em desenvolvimento (seta) (estreptavidina peroxidase ampliação original 400x). **Fase de botão terminal** (d1) (d2) (d3) (d1) Forte expressão do TGF-β1 em células acinares bem desenvolvidas espalhadas formando lóbulos acinares na região final das glândulas salivares (estreptavidina peroxidase ampliação original 400x). (d2.1) e (d2.2) Forte expressão do TGF-β2 no citoplasma das células dos ductos , incluindo ductos intercalares na junção ducto/ácino (d2.1 seta) (estreptavidina peroxidase ampliação original 400x). (d3.1) (d3.2) Forte expressão do TGF-β3 em células mioepiteliais ao redor de células do lóbulo acinar (d3.1) e suave expressão do TGF-β3 no citoplasma das células epiteliais que formam o ducto excretor (d3.2) estreptavidina peroxidase ampliação original 400x).

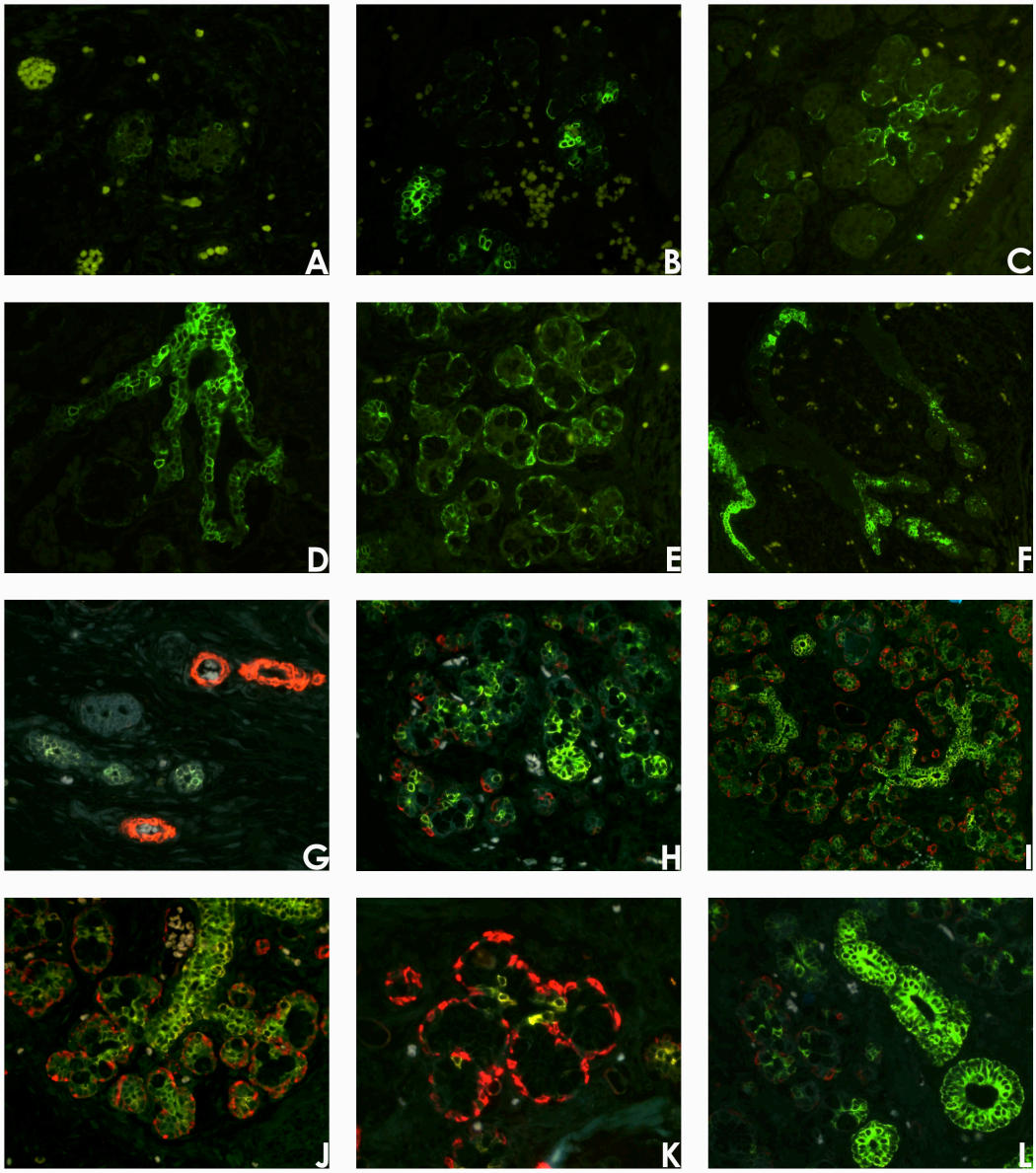

Figura 4

Figura 4 – Marcadores da diferenciação do citoesqueleto durante o desenvolvimento das glândulas salivares menores humanas –

Estágio de botão inicial: fraca expressão da CK 14 em algumas células das ilhotas epiteliais das glândulas em desenvolvimento. (**b**) e (**c**) Proliferação na fase de pseudoglandular: expressão da CK 14 no citoplasma das células ductais. (**d**) Fase de botão inicial: presença de CK 14 em um maior número de células do sistema ductal da glândula. (**e**) Fase canalicular: imunoexpressão da CK 14 nas células mioepiteliais em torno do lóbulo acinar. (**f**) Forte expressão da CK 14 na camada basal do epitélio e no sistema ductal bem formado da glândula salivar. Nota-se que a parte do ducto ao lado do epitélio de revestimento ainda é negativo para este marcador. (**g**) Fase canalicular / terminal de botão: algumas estruturas apresentam positividade para CKLMW (verde), a SMA (vermelho) é detectada apenas nas paredes dos vasos sanguíneos. (**h**) e (**i**) Fase de botão inicial / pseudoglandular: Forte expressão da CK LMW (verde) nas células do sistema ductal. Expressão inicial da SMA (vermelho) em células mioepiteliais vizinhas, principalmente na porção terminal do sistema ductal. (**j**) Fase canalicular: Expressão de CK LMW (verde) no sistema ductal e SMA (vermelho) em torno das estruturas acinares. (**k**) Lóbulos acinares bem formado: Forte expressão da SMA (vermelho) em torno de estruturas acinares. Poucas células são positivas para CK LMW (verde) normalmente presente em estruturas do ducto intercalado. (**l**) Sistema ductal bem desenvolvido fortemente positivo pra a CK LMW (verde).

Tabela 2 - Análise semi-quantitativa da expressão das subunidades de TGF-beta durante as fases da morfogênese das glândulas salivares humanas e nas glândulas salivares humanas plenamente desenvolvidas

			TGF-beta 1	TGF-beta 2	TGF-beta 3
MORFOGÊNESE DAS GLÂNDULAS SALIVARES HUMANAS	ESTÁGIO DE BOTÃO INICIAL	células epiteliais	0	++	+
		estroma	0	0	0
	ESTÁGIO PSEUDOGLANDULAR	cordões epiteliais	0	+++	+
		estroma	++	0	0
	ESTÁGIO CANALICULAR	células ductais	0	+++	+
		células mioepiteliais	0	0	++
		estroma	0	0	0
	ESTÁGIO TERMINAL DE BOTÃO	células ductais	0	+++	++
		células acinares	+++	0	0
		células mioepiteliais	0	0	++
		estroma	0	0	0
GLÁNDULA SALIVAR HUMANA PLENAMENTE DESENVOLVIDA		células ductais	0	+++	++
		células mioepiteliais	0	0	0
		células acinares	+++	0	0

0: negativo

+: positividade fraca

++: positividade moderada

+++: positividade intensa

6 DISCUSSÃO

6. DISCUSSÃO

Mecanismos moleculares envolvendo glândulas salivares em desenvolvimento foram descritos em detalhes em ratos e em camundongos. De acordo com esses trabalhos, sabe-se pouco sobre a expressão da TGF-β durante o período pré-natal e pós-natal de glândulas salivares humanas. Juntamente com outras glândulas e tecidos, é muito provável que esses fatos sejam coordenados por inúmeras vias integrando eventos e afetando a proliferação, a morfogênese e a interação célula-substrato.

Nossos resultados revelaram que TGF-β 1, 2 e 3 estavam presentes obedecendo um determinado padrão nas várias fases do desenvolvimento das glândulas salivares: pré-botão, botão inicial, pseudoglandular, canalicular e de botão terminal. Este padrão foi dinâmico e houve variedade de acordo com o estágio de desenvolvimento. Esse tipo de padrão também foi visto em glândulas mamárias e outras glândulas do corpo. A transição da forma de expressão do TGF-β no epitélio morfogeneticamente ativo foi relatada em estruturas de roedores na cabeça e no pescoço, semelhante ao folículo piloso, glândula salivar e germe dentário.

A superfamília do TGF-β é envolvida em muitos aspectos do desenvolvimento e incluem: TGF-βs, BMPs, actina, inibidores e outros. Especificamente TGF-βs, actinas e BMPs são relatados como controladores da glândula salivar no estagio de ramificação e estudos têm investigado esses fatores em glândula submandibular de camundongos.

Durante a fase inicial do desenvolvimento morfogenético das glândulas salivares, na fase de pré-botão, o TGF-β 1 não foi positivo e o TGF-β 2 e TGF-β 3 foram observados em raras células. Neste estágio há grande proliferação, com pequena ou nenhuma evidência de marcação pelos marcadores de proliferação. Considerando-se a atividade desse estágio, pode-se prever que a expressão do TGF-β não é uma vantagem, como tem sido previamente, pois este fator pode agir na fase terminal de botão, estágio mais avançado do desenvolvimento glandular. A expressão das citoqueratinas não foi detectada também neste estágio, em que a proliferação das células é o evento principal. Neste estágio, nenhuns dos marcadores estavam presentes em glândulas salivares em desenvolvimento, indicando que o tecido glandular estava imaturo e realizando novas ligações com a matriz extracelular preparando para o estágio posterior da diferenciação, quando os fenótipos dos marcadores poderão ser detectados. Este resultado está de acordo com o achado de Martins *et al*. (2002), que não encontrou esses marcadores de diferenciação em estágios muito avançado de desenvolvimento das glândulas salivares.

À medida que ocorreu o desenvolvimento da glândula salivar, houve o aumento da diferenciação tecidual (botão inicial / pseudoglandular) e o TGF-β 1 foi detectado no mesênquima ao redor do cordão epitelial de canalização e ramificação. Esse padrão de desenvolvimento do TGF-β 1 imita o resultado relatado por Robinson *et al*. (1991), em mama de ratos em ramificação, e é também reportado em pulmão em desenvolvimento. Esta distribuição do TGF-β 1 durante a fase de botão inicial / pseudoglandular

pode refletir uma reação autócrina do fator de desenvolvimento, o qual estimula o crescimento da extremidade do parênquima do broto celular. O TGF-β 2 e TGF-β 3 foram expressos pela célula epitelial do sistema ductal. Estes resultados estão parcialmente de acordo com os achados publicados de Jaskoll e Melnick (1999), que relatam a presença de TGF-β 1 e 2 em epitélio ramificado e TGF-β 3 em epitélio e mesênquima. Nesta fase, o sistema glandular continua apresentando substancial proliferação celular, principalmente nas pontas do sistema de canais ductais, na qual a subunidade TGF-β não é detectada. De qualquer forma, isso é caracterizado pela formação do lúmen do ducto, e significando uma mudança na expressão dos marcadores da diferenciação citoesqueletal. Neste estágio (pseudoglandular), observou-se positividade para CK 14 e 35βH11, indicando o progresso da citodiferenciação.

Durante o avanço das fases de botão inicial / pseudoglandular e canalicular da glândula salivar, o fenótipo da célula é composto principalmente por estruturas das glândulas em desenvolvimento foi bem definido pela expressão da CK 14, CKML e SMA. O TGF-β 1 mostrou forte expressão no citoplasma de células mucosas imaturas, nos sistemas de terminais e ramificações. O TGF-β 2 e 3 estavam distribuídos ao longo de todo o lúmen do sistema ductal, incluindo o ducto intercalar. O TGF-β 3 foi observado em células mioepiteliais ao redor de células mucosas imaturas, no extremo das células ductais. Este resultado está de acordo com os dados de Robinson *et al*. (1991), o qual descreve a expressão do TGF-β 3 em células mioepiteliais de mama de ratos. Essa expressão pode também ser

comparada com a expressão do TGF-β 3 em outros órgãos que apresentam células que possuem componentes contráteis, como as células esqueléticas do músculo cardíaco e células associadas a artérias. Células mioepiteliais da glândula salivar compõem a camada mais externa dos lóbulos acinares e ductos e agem tanto como células contráteis para secreção salivar e células com grande capacidade de síntese de lâmina basal que compõe essas estruturas. Robinson *et al*. (1991), descreveram a expressão do TGF-β 3 em células-tronco mioepiteliais, especulando sobre a possível função de inibição da diferenciação do terminal, que permitiria a formação dos botões laterais em mamas em desenvolvimento. Eles também sugeriram que o TGF-β 3 poderia estar envolvido na elaboração dos componentes da lâmina basal. Esses aspectos podem não ser acessíveis em nosso estudo e continua a ser elucidado na formação de glândulas salivares humanas.

Nos últimos estágios da morfogênese da glândula salivar na fase canalicular e de botão terminal, quando ocorre a ramificação e citodiferenciação de células acinares, CK 14, 35βH11 e SMA foram detectados num padrão específico. O SMA foi expresso quando os lóbulos acinares começam a se diferenciar, enfatizando a presença de células mioepiteliais ao redor dessas estruturas. CK 14 foi expressa por células basais de ductos excretores e 35βH11 foi achado nas células luminares do sistema ductal. CK 14, de acordo com outros autores, proverá uma forte base para a conexão de células basais com a membrana basal, funcionando como integradores do citoplasma e permitindo resistência a estresse mecânico e manutenção da arquitetura do sistema ductal. Nessa fase, o

TGF-β 1 foi visto esparsamente, e as células acinares mucosas bem desenvolvidas, e em glândulas salivares adultas, as células acinares conservaram a expressão desse fator de crescimento. Esse padrão pode ser indicativo de que o TGF-β 1 é sintetizado por células acinares e é importante para a manutenção de glândulas salivares. Entretanto, a expressão de TGF-β 1 em glândulas salivares adultas normais é discutível, e Kizu *et al*. (1996) relataram a sua expressão nos ácinos e ductos, Kusafuka *et al*. (2000), não acharam evidências de sua presença. O TGF-β 2 foi exclusivamente detectado em células epiteliais do sistema ductal, e o TGF-β 3 conservou sua expressão pelo sistema ductal e em células mioepiteliais que envolvem os lóbulos acinares mucosos e esses padrões mantidos em estruturas adultas.

O conjunto de resultados obtidos nesse trabalho indica, com bases morfológicas, que o TGF-β em suas diferentes isoformas, participa de forma importante na maturação das glândulas salivares. Os mecanismos da atividade desses fatores são ainda obscuros e novos trabalhos devem ser desenvolvidos, talvez utilizando-se de métodos *in vitro* para que se compreenda de forma conclusiva a atividade dessa importante família de fatores de crescimento na maturação das glândulas salivares.

7 CONCLUSÕES

7 CONCLUSÕES

Conclusão 1: A respeito da localização morfológica do TGF-β durante a morfogênese das glândulas salivares, concluímos:

- A troca de subunidades de TGF-β ocorre concomitante a mudanças evolutivas da morfogênese glandular durante o transcorrer do desenvolvimento das glândulas salivares.
- Há um padrão dinâmico e variedade no momento de expressão das subunidades de TGF-β de acordo com o estágio de desenvolvimento.

Conclusão 2: A respeito da relação do TGF-β com marcadores citoesqueletais das glândulas salivares, concluímos:

- O TGF-β é expresso em fases mais avançadas do desenvolvimento reafirmando sua ação na diferenciação glandular, onde se observa a presença dos marcadores citoesqueletais da diferenciação glandular.

8 ANEXOS

ANEXO A – PARECER DO COMITÊ DE ÉTICA EM PESQUISA

9 REFERÊNCIAS

REFERÊNCIAS

Adi MM, Chisholm DM, Waterhouse JP. Sterological and immunohistochemical study of development of human fetal labial salivary glands and their S-100 protein reactivity. *J Oral Pathol Med.* 1994;23(1):36-40.

Akhurst RJ, Lehnert SA, Gatherer D, Duffie E. The role of TGF beta in mouse development. *Ann N Y Acad Sci.* 1990;593:259-71.

Araújo VC, Carvalho YR, Araújo NS. Actin versus vimentin in my epithelial cells of salivary gland tumors. A comparative study. *Oral Surg Oral Med Oral Pathol.* 1994;77:387-91

Araújo VC, Sousa SOM. Expression of different cytokeratins in salivary gland tumors. *Eur J □rigin B Oral Oncol.* 1996;32B(1):14-8.

Araújo VC, Sousa SOM, Carvalho YR, Araújo NS. Application of immunohistochemistry to the diagnosis of salivary gland tumors. *Appl Immunohistochem Mol Morph.* 2000;8(3):195-202.

Araújo VC, Sousa SOM, Jaeger R, Loyola A, Crivelini M, Araújo N. Characterization of the cellular component of polymorphus low-grade adenocarcinoma by immunohistochemistry and electron microscopy. *Oral Oncol.* 1999;35(2):164-72.

Araújo VC, Souza SOM, Jaeger RG, Araújo NS. Immunohistochemical study of malignant salivary gland tumor. An analysis of 67 cases. *Rev Odontol USP.* 1991a;5:37-42.

Araújo VC, Souza SOM, Nunes FD, Araújo NS. Immunohistochemical analysis of 89 benign salivary gland tumors. *Rev Odontol USP.* 1991b;5:1-6.
Araújo VC, Sousa SOM, Lopes EA, Araújo NS, Sesso A. Mucus-producing adenopappilary carcinoma of minor salivary gland origin with signet ring cells and intracytoplasmic lumina. *Arch Otorhinolaryngol.* 1988;245(3):145-50.

Araújo VC, Sousa SOM, Sesso A, Sotto MN, Araújo NS. Salivary duct carcinoma: ultrastructural and histogenetic considerations. *Oral Surg Oral Med Oral Pathol.* 1987;63(5):592-6.

Attie JN, Sciubba JJ. Tumors of major and minor salivary glands: clinical and pathologic features. *Curr Probl Surg.* 1981;18(2):65-155.

Azuma M, Sato M. Morphogeneseis of normal human salivary gland cells in vitro. *Histol Histopathol.* 1994;9(4):781-90.

Batsakis JG. Salivary neoplasia: an outcome of modified morphogenesis and differentiation. *Oral Sur Oral Med Oral Pathol.* 1980;49(3):229-32.

Batsakis JG, Regezi JA, Luna MA; el-Naggar A. Histogenesis of salivary gland neoplasms: a postulate with prognostic implications. *J Laryngol Otol.* 1989;103(10):939-44.

Bernfield MR, Banderjee SD, Cohn RH. Dependence of salivary epithelial morphology and branching morphogenesis upon acid mucopolysaccharide-protein (proteoglican) at epithelial surface. *J Cell Biol.* 1972;52(3):674-89.

Bhaskar SN. Glândulas salivares. In: Orban BJ. *Histologia e Embriologia Oral de Orban*. 8ª ed. São Paulo: Artes Médicas; 1978.

Brown TL, Patil S, Howe PH. Analysis of TGF-beta-inducible apoptosis. *Methods Mol Biol.* 2000;142:149-67.

Carvalho YR, Araújo NS, Araújo VC, Sesso A. A polymorphous low-grade adenocarcinoma. An ultraestructural and immunohistochemical study. *Ver Odontol UNESP.* 1993;22(1):19-29.

Carvalho YR, Nogueira TO, Souza SOM, Araújo VC. Adenocarcinoma polimorfo de baixo grau de malignidade do tipo papilífero, estudo morfológico e imuno-histiquímico. *Rev Odontol UNESP.* 1990;19:165-71.

Chin D, Boyle GM, Parsons PG, Coman WB. What is transforming grow factor-beta (TGF-β)? *Br J Plast Surg.* 2004;57(3):215-21.

Crivelini MM, Araújo VC. Estudo clínico e histológico dos carcinomas de células acinares de glândulas salivares menores. *RPG Ver Pós-Grad.* 1995;2(5):6-10.

Crivelini MM, Souza SOM, Araújo VC. Immunohistochemical study of acinic cell carcinoma of minor salivary gland. *Oral Oncol.* 1997;33(3):204-25.

Cutler LS. The role of extracellular matrix in the morphogenesis and differentiation of salivary glands. *Adv Dent Res*. 1990;4:27-33.

Dale AC. Salivary gland: In Ten Cate AR. *Oral histology*: development, structure, and function. 4th ed. St. Louis: Mosby; 1994. p. 356.

Dardick I, Naiberg J, Leung R, Ramjohn S, Christensen H, Burford-Mason A, Henderson WD, Rippstein P. Ultraestructural study of acinar and intercalated duct organization of submandibular and parotid salivary gland. *Lab Invest.* 1990;63(3):394-404.

Dardick I, Parks WR, Little J, Brown DL. Characterization of cytoskeletal proteins in basal cells of human parotid salivary gland ducts. *Virchows Arch A Pathol Anat Histopalthol*. 1988;412(6):525-32.

Denny PC, Ball WD, Redman RS. Salivary glands: a paradigm for diversity of gland development. *Crit Rev Oral Biol Med.* 1997;8(1):51-75.

Derynck R, Janet JA, Chen EY, Eaton DH, Bell JR, Assoian RK, Roberts AB, Sporn MB, Goeddel DV. Human transforming growth factor ß complementary DNA sequence and expression in normal and transformed cells. *Nature* 1985;316(6030):701-5.

Derynck R, Lindquist PB, Lee A, Wen D, Tamm J, Graycar JL, Rhee L, Mason AJ, Miller DA, Coffey RJ, et al. A new type of transforming growth factor-beta, TGF-beta 3. *EMBO J.* 1988;7(12):3737-43.

Ellis GL, Auclair PL. *Tumors of salivary glands.* Bethesda: Armed Forces Institute of Pathology; 1996. (Atlas of tumor pathology, 17).

Engel ME, Datta PK, Moses HL. Signal transduction by transforming growth facto-beta: a cooperative paradigm with extensive negative regulation. *J Cell Biochem Suppl*. 1998(30-31):111-22.

Eversole LR. Histogenetic classification of salivary glands. *Arch Pathol.* 1971;92(6):433-43.

Figueiredo CRLV, Sousa SOM, Araújo VC. Estudo imunohistoquímico do carcinoma adenóide cístico de glândula salivar menor. *RPG*. 1997(4):231-7.

Fitzpatrick DR, Denhez F, Kondaiah P, Akhurst RJ. Differential expression of TGF beta isoforms in murine palatogenesis. *Development.* 1990;109(3):585-95.

Freitas RA, Araújo VC, Araújo NS. Argyrophilia in nucleolar □rigin□ct regions (AgNOR) in adenoid cystic carcinoma and polymorphous low-grade adenocarcinoma of salivary glands. *Eur Arch Otorhinolaryngol.* 1993(259):213-7.

Graycar JL, Miller DA, Arrick BA, Lyons RM, Moses HL, Derynck R. Human transforming growth factor-beta 3: recombinant expression, purification, and biological activities in comparison with transforming growth factors-beta 1 and beta 2. *Mol Endocrinol.* 1989;3(12):1977-86.

Gustafsson H, Kjörell U, Eriksson A, Virtanen I, Thornell LE. Distribution of intermediate filament proteins in developing and adult salivary glands in man. *Anat Embryol*. 1988;178(3):243-51.

Hand AR. Salivary glands. In: Provenza DV. Oral histology inheritance and development. 2nd ed. Philadelpia Les & Febinger; 1980.

Hiatt JL, Sauk JJ. Embryology and anatomy of salivary glands In: Ellis GL, Auclair PL, Gnepp DR. *Surgical pathology of salivary glands*. Philadelphia: Saunders; 1991. 580 p.

Jarger RG, Oliveira PT, Jaeger MMM, Araújo VC. Expression of smooth-muscle actin in cultured cells from human plasmacytoid myoepithelioma. *Oral Surg Oral Med Oral Pathol Oral Radiol Endod.* 1997;84(6):663-7.

Jaskoll T, Melnick M. Submandibular gland morphogenesis: stage-specific expression of TGF-alpha/EGF, IGF, TGF-β, TNF, and IL-6 signal transduction in normal embryonic mice and the phenotypic effects of TGF-β 2, TGF-β 3, and RGF-R null mutations. *Anat Rec*. 1999;256(3):252-68.

Jennings JC, Mohan S, Linkhart TA, Widstrom R, Baylink DJ. Comparison of the biological actions of TGF ß beta 1 and TGF ß 2: differential activity in endothelial cells. *J Cell Physiol.* 1988;137(1):167-72.

Kizu Y, Sakurai S, Katagiri S, Shinozaki N, Ono M, Tsubota K, Saito J. Immunohistochemical analysis of tumor growth factor-beta 1 in normal and inflamed salivary glands. *J Clin Pathol*. 1996;49(9):728-32.

Klein RM. Development, structure and function of salivary glands. In: Avery JK. *Oral development and histology.* 2nd ed. New York: Thieme; 1994.

Kusafuka K, Yamaguchi A, Kayano T, Takemura T. Immunohistochemical localization of members of the transforming growth factor-beta superfamily in normal human salivary glands and pleomorphic adenomas. *J Oral Pathol Med*. 2000;30:413-20.

Lee SK, Lim CY, Chi JG, Yamada K, Kunikata M, Hashimura K, Kunikata M, Mori M. Prenatal development of human major salivary glands and immunohistochemical detection of keratins using monoclonal antibodies. *Acta Histochem*. 1990;89(2):213-35.

Lehnert SA, Akhurst RJ. Embryonic expression pattern of TGF-β type-1 RNA suggest both paracrine and autocrine mechanisms of action. *Development.* 1988;104(2):263-73.

Loducca SV, Raitz R, Araújo NS, Araújo VC. Polymorphous low-grade adenocarcinoma and adenoid cystic carcinoma: distinct □rigin□ctural composition revealated by collagen IV, laminin and their integrin ligands (alpha2beta1 and alpha3beta1). *Histopathology.* 2000;37(2):118-23.

Loyola AM, Araújo VC. Carcinoma mucoepidermóide de glândulas salivares menores: estudo clínico, histopatológico. *RPG.* 1996;3(2):115-21.

Loyola AM, Araújo VC, Sousa SO, Araújo NS. Minor salivary gland tumours. A retrospective study of 164 cases in a Brazilian population. *Eur J Cancer B Oral Oncol.* 1995;31B(3):197-201.

Lyons RM, Moses HL. Transforming growth factors and the regulation of cell proliferation. *Eur J Biochem.* 1990;187(3):467-73.

Madisen L, Webb NR, Rose TM, Marquardt H, Ikeda T, Twardzik D, Seyedin S, Purchio AF. Transforming growth factorß2: cDNA cloning and sequence analysis. *DNA.* 1988;7(1):1-8.

Martins MD, Araújo VC, Raitz R, Araújo NS. Expression of cytoskeletal proteins in developing human minor salivary glands. *Eur J Oral Sci*. 2002;110(4):316-21.

Massagué J. How cells read TGF-beta signals. *Nat Rev Mol Cell Biol*. 2000;1(3):169-78.

Massagué J. TGF beta signal transduction. *Annu Rev Biochem.* 1998;67:753-91.

Mc Bride ML, Baillie J, Polland BJ. Growth parameters in normal fetuses. *Teratology*. 1984;29(2):185-91.

McNicol AM, Richmond JA. Optimizing immunohistochemistry: antigen retrieval and signal amplification. *Histopathology.* 1998;32(2):97-103.

Mercola M, Stiles CD. Growth factor superfamilies and mammalian embryogenesis. *Development.* 1988;102(3):451-60.

Merwin JR, Newman W, Beall LD, Tucker A, Madri J. Vascular cells respond differentially to transforming growth factor beta 1 and beta 2 in vitro. *Am J Pathol.* 1991;138(1):37-51.

Millan FA, Denhez F, Kondaiah P, Akhurst RJ. Embryonic gene expression patterns of TGF-β 1, beta 2 and beta 3 suggest different developmental functions in vivo. *Development*. 1991;111(1):131-43.

Miller DA, Pelton RW, Derynck R, Moses HL. Transforming growth factor-beta. A family of growth peptides. *Ann N Y Acad Sci.* 1990;593:208-17.

Nilsen-Hamilton M. Transforming growth factor-beta and its actions on cellular growth and differentiation. *Curr Top Dev Biol.* 1990;24:95-136.

Ohta M, Greenberger JS, Anklesaria P, Bassols A, Massagué J. Two forms of transforming growth factor-beta distinguished by multipotential haematopoietic progenitor cells. *Nature.* 1987;329(6139):539-41.

Padgett RW, St Johnston RD, Gelbart WM. A transcript from a Drosophila pattern gene predicts a protein homologous to the transforming growth factor-beta family. *Nature.* 1987;325(6099):81-4.

Patel VN, Rebustini IT, Hoffman MP. Salivary gland branching morphogenesis*. Differentiation*. 2006;74(7):349-64.

Pelton RW, Dickinson ME, Moses HL, Hogan BL. In situ hybridization analysis of TGF beta 3 RNA expression during mouse development: comparative studies with TGF beta 1 and beta 2. *Development.* 1990a;110(2):609-20.

Pelton RW, Hogan BL, Miller DA, Moses HL. Differential expression of genes encoding TGFs beta 1, beta 2, and beta 3 during murine palate formation. *Dev Biol*. 1990b;141(2):456-60.
Pelton RW, Nomura S, Moses HL, Hogan BL. Expression of transforming growth factor beta 2 RNA during murine embryogenesis. *Development*. 1989;106(4):759-67.

Pelton RW, Saxena B, Jones M, Moses HL, Gold LI. Immunohistochemical localization of TGF beta 1, TGF beta 2, and TGF beta 3 in the mouse embryo: expression patterns suggest multiple roles during embryo development. *J Cell Biol.* 1991;115(4):1091-105.

Piek E, Heldin CH, Ten Dijke P. Specificity, diversity, and regulation in TGF-beta superfamily signaling. *FASEB J.* 1999;13(15):2105-24.

Regezi JA, Batsakis JG. Histogenesis of salivary gland neoplasms. *Otolaryngol Clin North Am.* 1977;10(2):297-307.

Robinson SD, Silberstein GB, Roberts AB, Flanders KC, Daniel CW. Regulated expression and growth inhibits effects of transforming growth factor-beta isoforms in mouse mammary gland development. *Development*. 1991;113(3):867-78.

Rosa F, Roberts AB, Danielpour D, Dartt LL, Sporn MB, Dawid IB. Mesoderm induction in amphibians: the role of TGF beta 2-like factors. *Science.* 1988;239(4841 Pt 1):783-5.

Schmid P, Cox D, Bilbe G, Maier R, McMaster GK. Differential expression of TGF beta 1, beta 2, and beta 3 genes during mouse embryogenesis. *Development*. 1991;111(1):117-30.

Segarini PR. Cell type specificity of TGF-beta binding. *Ann N Y Acad Sci.* 1990;593:73-90.

Sousa SOM, Araújo VC. Estudo morfológico e imunohistoquímico do adenoma pleomórfico de glândula salivar menor. *RPG Ver Pós-Grad.* 1994;1(2):22-6.

Souza SCOM, Sesso A, Araújo NS, Araújo VC. Inverted ductal papilloma of minor salivary gland origin: morphological aspects and cytokeratin expression. *Eur Arch Otorhinolaryngol*. 1995;252(6):370-3.

Sporn MB, Roberts AB. TGF-beta: problems and prospects. *Cell Regul.* 1990;1(12):875-82.

Ten Dijke P, Hansen P, Iwata KK, Pieler C, Foulkes JG. Identification of another member of the transforming growth factor type beta gene family. *Proc Natl Acad Sci USA.* 1988;85(13):4715-90.

Thiery JP. Epithelial-mesenquimal transitions in development and pathologies. *Current Opinion Cell Biol.* 2003;15(6):740-6.

Tonge CK, Luke DA. Dental anatomy: the salivary glands. *Dent Update.* 1984;11(5):264, 266, 268-70.

Tucker AS. Salivary gland development. *Semin Cell Dev Biol*. 2007;18(2):237-44.

Weeks DL, Melton DA. A maternal mRNA localized to the vegetal hemisphere in Xenopus eggs codes for a growth factor related to TGF-beta. *Cell.* 1987;51(5):861-7.

Whitman M, Melton DA. Growth factors in early embryogenesis. *Annu Rev Cell Biol*. 1989;5:93-117.

Wrana JL. TGF-beta receptors and signaling mechanisms. *Miner Electrolyte Metab.* 1998;24(2-3):120-30.

Yaku Y. Ultrastructural studies on development of human fetal salivary glands. *Arch Histol Jpn*. 1983;46(5):677-90.

10 APÊNDICE

Histochem Cell Biol (2007) 128:361–369
DOI 10.1007/s00418-007-0322-6

ORIGINAL PAPER

Human salivary gland branching morphogenesis: morphological localization of claudins and its parallel relation with developmental stages revealed by expression of cytoskeleton and secretion markers

Silvia V. Lourenço · Cláudia M. Coutinho-Camillo · Marcilei E. C. Buim · Sabrina H. Uyekita · Fernando A. Soares

Accepted: 22 July 2007 / Published online: 9 August 2007

Abstract Development of salivary glands is a highly complex and dynamic process termed branching morphogenesis, where branched structures differentiate into mature glands. Tight junctions (TJ) are thought to play critical roles in physiological functions of tubular organs, contributing to cell polarity and preventing lateral movement of membrane proteins. Evidence demonstrated that claudins are directly involved in TJ formation and function. Using immunohistochemistry and immunofluorescence we have mapped the distribution of claudins-1, 2, 3, 4, 5, 7 and 11 and compared it with the expression of differentiation markers in human salivary glands obtained from foetuses ranging from weeks 4 to 24 of gestation. Expression of all claudins, except claudin-2 was detected in the various phases of human salivary gland development, up to fully mature salivary gland. The expression of all claudins increased according to the progression of salivary gland maturation evidenced by the classical markers—cytokeratin 14, cytokeratin low molecular weight, smooth muscle actin and human secretory component. Tight junction proteins—claudins appear to be important in the final shape and physiological functions of human salivary glands and are parallel related with markers of salivary gland differentiation.

Keywords Human salivary gland · Branching morphogenesis · Claudins

S. V. Lourenço · F. A. Soares
Department of General Pathology, Dental School, University of São Paulo, São Paulo, Brazil

S. V. Lourenço
Laboratory of Immunopathology, Institute of Tropical Medicine, São Paulo University, São Paulo, Brazil

S. V. Lourenço · S. H. Uyekita
Department of Dermatology, Medical School, University of São Paulo, São Paulo, Brazil

C. M. Coutinho-Camillo · M. E. C. Buim · F. A. Soares
Department of Pathology, Hospital A. C. Camargo, São Paulo, Brazil

S. V. Lourenço (✉)
Disciplina de Patologia Geral, Faculdade de Odontologia da Universidade de São Paulo, Av Prof Lineu Prestes, 2227, Cidade Universitária, CEP 05508-000 São Paulo, SP, Brazil
e-mail: sloducca@usp.br

Introduction

The development of salivary glands from simple precursor epithelial buds to functional glands is a highly complex and dynamic process. The mechanism by which a simple bud becomes such a complicated final structure is termed branching morphogenesis, where tissues generate branched structures that are subsequently differentiated into mature glands. Briefly, salivary gland formation starts with the proliferation of a solid cord of cells from the epithelium of the stomatodeum into the underlying ectomesenchyme. This cord of cells extends deeply into the ectomesenchyme and branches extensively. These cells then canalise by degradation of the central cells to form the ductal system and the terminal secretory end pieces. The epithelial ingrowths constitute the parenchyme of a salivary gland. The ectomesenchyme differentiates to form the connective tissue component of the gland, which supports the parenchyma (Kashimata and Gresik 1996; Cutler 1989, 1990).

Minor salivary glands begin to develop at 4–6 weeks of embryonic life. Branches from parasympathetic and

sympathetic nerves migrate to the gland and the collecting veins are formed. Salivary gland development consists of a series of ducts ending in terminal secretory end pieces, grape-like in structure (Kashimata and Gresik 1996; Cutler 1989, 1990). At the end of the maturation process, salivary glands should be ready for salivary production, which occur in two phases: an acinar phase of production of primary saliva and a ductal phase of electrolyte reabsorption, resulting in hypotonic saliva. This process depends on molecules and ions exchange, which are transported actively or passively through the cell membranes of the ducts and acinar units of the salivary glands. The process is also dependent on the maintenance of adhesion and polarization of cells forming the glands (Cook et al. 1998; Guyton and Hall 2000).

Tight junctions (TJ) are thought to be the principal structures that contribute to cell polarity, by acting as an intramembrane barrier to prevent lateral movement of membrane proteins that form specific sites in the apical or basolateral membranes, thereby playing a critical role in the physiological functions of tubular organs (Anderson 2001; Tsukita et al. 2001). Several lines of evidence have demonstrated that claudins, proteins of a multigene family of TJ, are directly involved in the formation of TJ strands as well as their barrier function (Tsukita et al. 2001). Claudins are also described to confer selective barrier properties on TJs, being important in physiological functions of several tissues and organs (Anderson 2001; Mitic and Anderson 1998; Peppi and Ghabriel 2004).

To date, little is known of the key regulators of human salivary gland development and function. Temporal and spatial regulation of these events is likely to be important to salivary gland development and for proper tissue function and our group has been studying some of these aspects demonstrating the participation of integrins in the process (Lourenço and Kapas 2005). However, other highly specialised cellular mechanisms of adhesion have evolved to keep adhesion, to form selective barriers and to keep a polarised state between apical and basolateral membranes of the cells.

In the present study, we investigated the morphological expression of several claudins molecules to understand their participation in the lumen formation of human developing salivary glands. Also, the expression of claudins was compared with the expression of maturation markers (Lourenço et al. 2007; Martins et al. 2002) in the different phases of the human salivary glands branching morphogenesis.

Materials and methods

Tissue preparation

Fragments of the oral cavity from post-mortem of 20 human foetuses (provenient from natural miscarriages) at 4–24 weeks of gestation were obtained from the Medical School of the University of São Paulo and in accordance with authorisation of the Ethical Committee of the institution. The specimens were collected from different oral sites, including buccal mucosa, tongue, mandible and hard palate. Five specimens of fully developed salivary gland specimens present in oral mucosa biopsies were retrieved from the archives of the Laboratory of Dermatopathology of the same institution and were used as controls. They were histologically normal and presented no inflammatory or neoplastic processes associated. All specimens were fixed in 10% buffered formalin for 24 h and embedded in paraffin. They were then histologically processed, serial-sectioned and stained with haematoxylin and eosin to check for the presence of salivary glands and study their morphology. Those presenting developing minor salivary glands were selected for the present immunohistochemical analysis.

Immunohistochemistry

Three μm serial sections of the specimens were re-hydrated and incubated in 3% aqueous hydrogen peroxide for 30 min to quench endogenous peroxidase activity. Incubation with 1% bovine serum albumin (BSA) and 5% foetal calf serum (FCS) in Tris–HCl pH 7.4 for 60 min at room temperature was performed to suppress non-specific binding of subsequent reagents. The sections were then submitted to antigen retrieval, followed by incubation overnight with the primary antibody. Details on antigen retrieval methods as well as primary antibodies clones, source, title are described in Table 1. The reaction followed with incubation with the indirect dextran polymer detection system (En Vision—Dako Carpinteria, CA, USA). Staining was completed by incubation with 3′3 diaminobenzidine tetrachloride (DAB) for 3 min. The specimens were then lightly counterstained with Mayer's haematoxylin, dehydrated and mounted with glass coverslip and xylene based mountant.

Negative controls were achieved by substituting primary specific antibodies with non-immune serum and internal positive controls were considered according to primary serum manufacturer's datasheet recommendation.

All immunohistochemical reactions were carried out in triplicate.

Immunofluorescence

Three μm serial sections of the formalin-fixed, paraffin embedded developing salivary glands specimens were re-hydrated and incubated with 1% bovine serum albumin (BSA) and 5% foetal calf serum (FCS) in Tris–HCl pH 7.4 for 60 min at room temperature to suppress non-specific binding of subsequent reagents. The double labelling immunofluorescence reactions were performed in two

Table 1 Primary serum, clones, source, working title and antigen retrieval

Primary serum	Clone	Source	Working title	Antigen retrieval
Claudin-1	Policlonal	Zymed (Carlsbad, CA, USA)	1:400	Citrate, PH6.0
Claudin-2	Policlonal	Neomarkers (Fremont, CA, USA)	1:400	Citrate, PH6.0
Claudin-3	Policlonal	Neomarkers (Fremont, CA, USA)	1:500	Citrate, PH6.0
Claudin-4	Policlonal	Neomarkers (Fremont, CA, USA)	1:200	Citrate, PH6.0
Claudin-5	Policlonal	Neomarkers (Fremont, CA, USA)	1:1000	Citrate, PH6.0
Claudin-7	Policlonal	ZYMED (Carlsbad, CA, USA)	1:800	Citrate, PH6.0
Claudin-11	Policlonal	Neomarkers (Fremont, CA, USA)	1:800	Citrate, PH6.0
CK LMW/	35beta H11	Dako (Carpinteria, CA, USA)	1:50	Citrate, PH6.0
CK 14	LL 002	Neomarkers (Fremont, CA, USA)	1:50	Citrate, PH6.0
SMA	1A4	Dako (Carpinteria, CA, USA)	1:50	Citrate, PH6.0
HSC	A0187	Dako (Carpinteria, CA, USA)	1:10	Citrate, PH6.0
Alexa 488	–	Molecular Probes	1:1,000	–
Alexa 594	–	Molecular Probes	1:1,000	–

steps. For that, the sections were incubated with the first primary antibody, followed by incubation with Goat Anti-Mouse IgG labelled with green fluorescent Alexa 488 (Molecular Probes, Carlsbad, CA, USA) at a concentration of 1:100 in BSA-PBS. Incubation with the second primary antibody was performed, followed by incubation with Goat Anti-Mouse IgG labelled with red fluorescent Alexa 594 (Molecular Probes, Carlsbad, CA, USA) at a concentration of 1:100. Primary antibodies used, source, clone and working dilutions are described in Table 1. All steps were preceded by two incubations with Tris–HCl pH7.4 for 5 min at room temperature. The sections were then air dried and mounted with Vecta Shield (Vector Laboratories, Burlingame, CA, USA).

The results were analysed, observed and photographed under Zeiss microscope (Zeiss Inc., Jena, Germany) equipped with epi-illumination and filters for fluorescein and rodamin with digital camera.

Negative controls were treated as above, but a solution of 1% BSA in Tris–HCl pH 7.4 replaced the primary antibody. Specimens incubated with normal serum were used as additional negative controls. Internal positive controls such as basal layer of epithelium and blood vessels were present.

Results

The specimens studied were of the minor human salivary glands in various stages of development, comprising bud, proliferation, canalisation, branching and cytodifferentiation.

Immunohistochemistry

All claudins tested were present in the glands studied with exception of claudin-2, which was not detected in any phase of salivary gland development or adult gland but was positive in the controls used. These results are described according to the salivary gland morphology and depicted in Table 2.

At bud/proliferation stage, when salivary glands start to develop, claudin-1 was negative (Fig. 1a). Claudin-3 was expressed surrounding the cell membrane in some glandular buds while others were mostly negative (Fig. 1b, b arrow). Claudin-4 was expressed in the apico-lateral membrane of some cells of the salivary gland bud (Fig. 1c). Claudin-5 was expressed in a few cells of the solid bud of the very initial stage of salivary gland morphogenesis (Fig. 2a). At this stage, claudin-7 was observed surrounding the apico-lateral membrane of cells in the centre of the solid bud and claudin-11 showed a membrane-cytoplasmic expression in all cells of the bud (Fig. 2b, c, respectively).

At branching stage, claudin-1 was observed in scattered cells along the branching cords of epithelial cells (Fig. 1d). Claudin-3 was expressed at the apico-lateral membrane of epithelial cells in the centre of the branching cords and claudin-4 followed this same pattern, however with greater and more demarcated intensity (Fig. 1e, f, respectively). Claudins-5 and 7 were also detected in the apico-lateral cytoplasmic membrane of epithelial cells that occupy the centre of the branching cords (Fig. 2d, e, respectively). Claudin-11 was observed in a cytoplasmic pattern of expression, with weak intensity, along the epithelial cells of the branching/canalising cords (Fig. 2f).

During canalisation/initial cytodifferentiation, claudin-1 was seen at the lateral cytoplasmic membrane of scattered cells of well-canalised ducts. The arborised glandular system, including the ductal endpieces (future acinar lobules) was negative for this claudin (Fig. 1g). At this stage claudins-3 and 4 showed a strong apico-lateral expression of the cell membranes along the arborised ductal system up to the end-pieces/ rudimentary acinar lobules (Fig. 1h, i).

Table 2 Semi-quantitative expression on claudins in the different phases of human salivary gland morphogenesis and in fully developed salivary gland

		CLD-1	CLD-2	CLD -3	CLD -4	CLD -5	CLD -7	CLD-11
Bud	Epithelial cells	-ve	-ve	-ve/+	+	+	+	+
Branching	Arborising cords	-ve/+	-ve	+	++	++	++	++
Canalisation/initial acinar differentiation	Rudimentary ducts	+	-ve	+++	+++	+++	+++	++
	Rudimentary acinar lobules (endpieces)	-ve	-ve	+++	+++	+++	+++	++
Acinar differentiation	Acinar cells	-ve	-ve	-ve	-ve	+++	-ve	-ve
	ME cells	-ve	-ve	-ve	++	+++	-ve	-ve
	Intercalated ducts	+	-ve	+	+++	+++	+++	++
	Excretory ducts	+	-ve	+	+++	+++	+++	++
Adult gland	Acinar lobules	-ve	-ve	++	++	++	++	++
	ME cells	-ve	-ve	-ve	-ve	-ve	-ve	-ve
	Intercalated ducts	++	-ve	++	++	++	++	++
	Striated ducts	++	-ve	++	++	++	++	++
	Excretory ducts	++	-ve	++	++	++	++	++

CLD claudin, *ME* myoepithelial, -ve negative, + positivity in scattered cells, ++ mild positivity, +++ strong and wide distributed positvity

Claudins-5 and 7 were also observed following the latter pattern (Fig. 2g, h). Claudin-11 was present in the cytoplasm of epithelial cells along the entire arborised system (Fig. 2i).

In later stages of salivary gland morphogenesis, (acinar advanced cytodifferentiation), claudin-1 remained with expression limited to scattered cells in the ductal system, in the lateral aspect of the plasma membrane. Acinar lobules were negative for this protein (Fig. 1j). Claudin-3 was seen at the apico-lateral portion of luminal cells of intercalated duct and initial portion of excretory duct. In distal segments of excretory ducts it was observed only in scattered cells. Acinar lobules and the surrounding myoepithelial cells were negative for this protein (Fig. 1k). Claudin-4 was expressed along the entire ductal system in the phase of acinar differentiation and it was also positive in myoepithelial cells surrounding immature acinar lobules (Fig. 1l1). Later, in this phase, fully developed acinar lobules were negative for claudin-4 (Fig. 1l2). Claudin-5 was strongly positive in the late stage of salivary gland differentiation. It was observed surrounding acinar cell membranes and in the apico-lateral aspect of luminal cells along the entire ductal system including intercalated duct (Fig. 2j). Claudin-7 was also positive at the apico-lateral aspect of the membranes of luminal cells, but was not detected in the acinar lobules (Fig. 2k). Claudin-11 retained its cytoplasmic pattern of expression along the luminal cells of the entire ductal system and it was negative in acinar lobules (Fig. 2l).

In fully developed adult salivary glands, claudin-1 was detected at the apico-lateral aspect of ductal cells membranes that composed interlobular ducts and excretory ducts, but was negative on acinar cells (Fig. 3a). A similar aspect was observed for claudin-3 (Fig. 3b). Claudin-4 was observed around the cell membrane of ductal and acinar cells (Fig. 3c). Claudin-5 was detected at the apical and basal poles of the cell membrane of ductal cells as fine lines (Fig. 3d). Weak expression of this claudin was seen on the membrane of acinar cells. Claudin-7 was mainly observed on the membrane of myoepithelial cells and on ductal cells of the intercalated ducts (Fig. 3e, arrow). Finally, claudin-11 presented a weak expression, detected at the intercalated duct cells and myoepithelial cells (Fig. 3f).

Immunofluorescence

During proliferation and canalisation stage of salivary glands, solid epithelial buds and few developing salivary gland ducts were observed. In these phases, Low Molecular Weight Cytokeratin (CK LMW/35beta H11) was observed in cells of the centre of the epithelial cords (Fig. 4a1, a2-green). Solid epithelial buds were negative for this protein (Fig. 4a1, arrow). In the same phase, CK14 was present in the ductal epithelial cells (Fig. 4b). During ramification/canalisation phase, CK LMW/35beta H11) was detected in the cytoplasm of ductal cells (green) and smooth muscle actin (SMA) was expressed in myoepithelial cells surrounding the initial ductal system (red) (Fig. 4c). In this phase, strong expression of CK14 was detected in the cytoplasm of ductal cells and weak expression of this protein was seen in the rudimentary end-pieces of the initial ductal system. In a further developmental stage (initial cytodifferentiation) luminal cells showed a cytoplasmic positivity for CK LMW/ 35beta H11 and myoepithelial cells surrounding proximal segments of ductal system and rudimentary acinar lobules were positive for SMA. At this stage, myoepithelial cells also demonstrated positivity for CK14 (green)

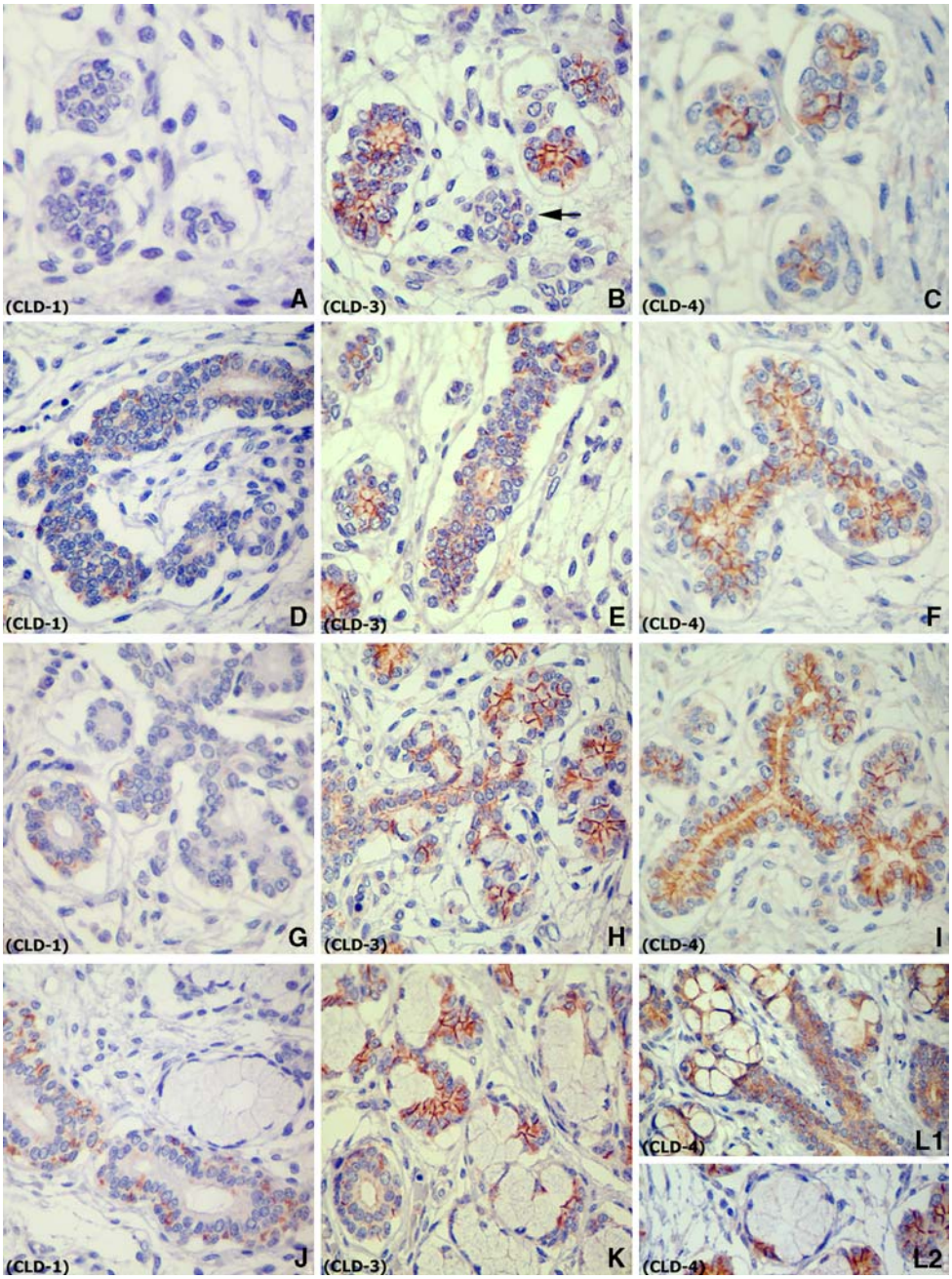

Fig. 1 Expression patterns of claudins-1, 3 and 4 in the morphogenesis of human minor salivary glands. **a**–**c** Bud/proliferation stage: solid nests of epithelial cells in the mesenchyme. In **a**, no evidence of claudin-1 is observed. Claudins-3 and 4 are expressed as *thin lines* at the apico-lateral membranes of the epithelial cells in this early phase of salivary gland development (**b**, **c**, respectively). Some rudimentary salivary gland nests still present a negative/weak expression of claudin-3 (**b** *arrow*) (Original magnification ×400). **d**–**f** Branching/initial canalisation stage: epithelial solid nests and cords elongate and branch forming an arborised structure, some with rudimentary lumens. Claudin-1 is observed as clustered at the lateral aspect of cells along the solid epithelial cords (**d**). Claudins-3 and 4 appear as *thin lines* at the apico-lateral aspect of the membranes of epithelial cells that occupy the centre of the branching cords (**e** and **f**, respectively) (Original magnification ×400). **g**–**i** Canalisation/initial cytodifferentiation: the arborised ductal system presents well-canalised ducts, some with epithelial clusters at their endpieces that represent rudimentary acinar lobules. Claudin-1 is observed as clusters at the lateral aspect of scattered ductal cells in well-canalised interlobular ducts (**g**). Claudins-3 and 4 are detected as *thin lines* at the apico-lateral membrane of luminal cells of the entire ductal system, including the endpieces (**h**, **i**) (Original magnification ×400). **j**–**l** Advanced cytodifferentiation: a well-formed and complex ductal system linked to developed acinar lobules is present as a final stage of salivary gland morphogenesis. Claudin-1 is only seen in scatter luminal and basal cells of stratified interlobular excretory ducts (**j**). Claudin-3 is expressed as strong *thin lines* at the apico-lateral aspect of the membranes of luminal cells of intercalated and striated ducts, and as clusters in scattered cells of intra-lobular excretory ducts. Acinar lobules are negative for claudin-3 (K). Claudin-4 is expressed along the entire ductal system and also surrounding immature acinar cells (*L1*). In mature acinar lobules claudin-4 was not detected (*L2*) (Original magnification ×400)

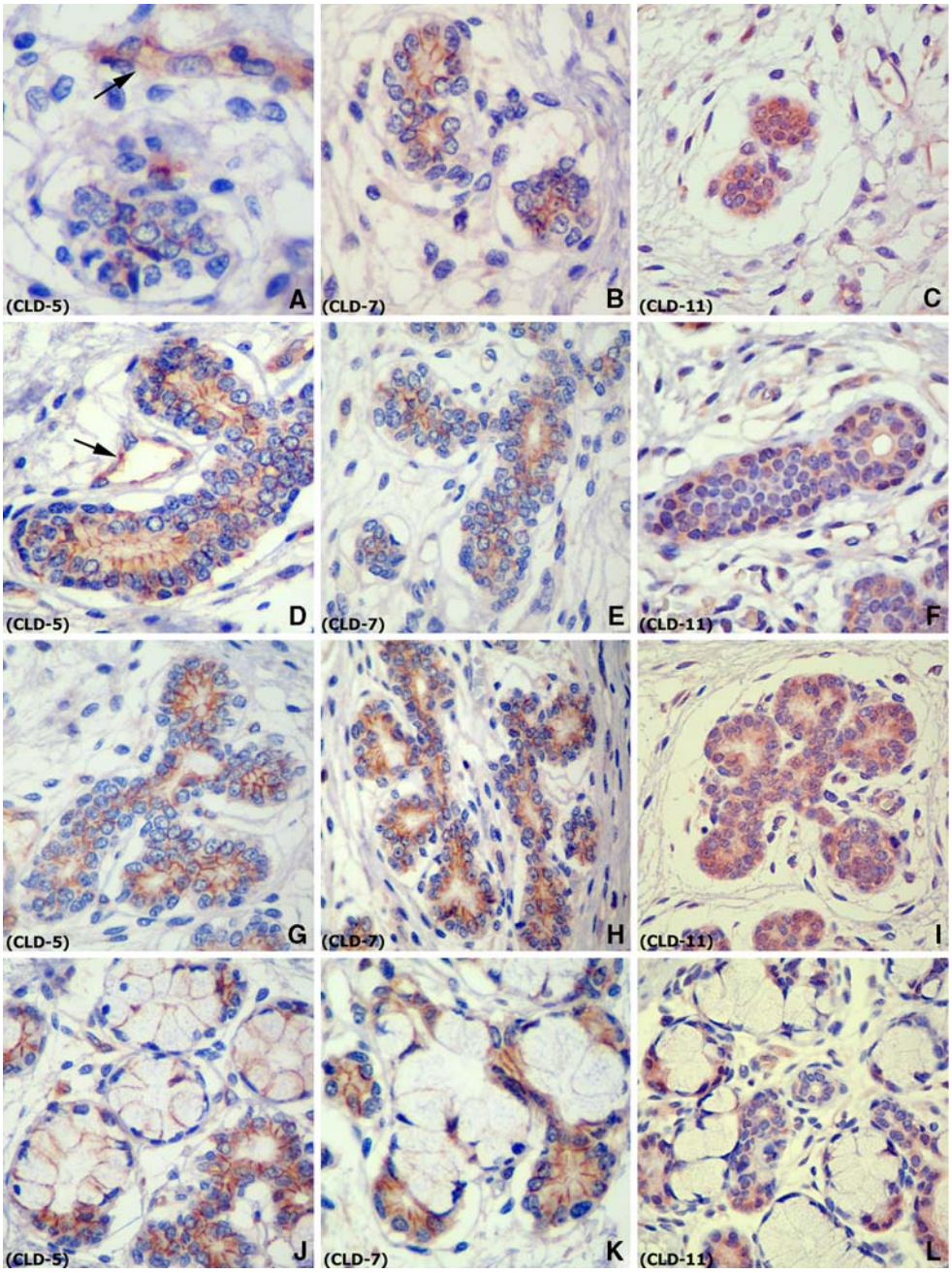

Fig. 2 Expression patterns of claudins-5, 7 and 11 in the morphogenesis of human minor salivary glands. **a–c** Bud/proliferation stage: solid nests of epithelial cells in the mesenchyme. Claudin-5 is expressed as clusters at the membrane of scattered cells of the solid nests. It is also detected is endothelial cells (*arrow*) (**a**). Claudin-7 is seen as thin lines at the membranes of cells in the centre of epithelial nests (**b**). Claudin-11 is expressed in the cytoplasm of epithelial cells of the solid nests (**c**) (Original magnification ×400). **d–f** Branching/initial canalisation stage: epithelial solid nests and cords elongate and branch forming an arborised structure, some with rudimentary lumens. Claudins-5 and 7 are expressed as *thin lines* and clusters at the membranes of epithelial cells of the solid cords (**d**, **e**, respectively). Claudin-5 is also observed in endothelial cells of the intra-glandular vessels (**d** *arrow*). Claudin-11 is detected as a cytoplasmic positivity in a few epithelial cells of the branching cords (**f**). (Original magnification ×400). **g–i** The arborised ductal system presents well- canalised ducts, some with epithelial clusters at their endpieces that represent rudimentary acinar lobules. Claudins-5 and 7 are detected mostly as *thin lines*, and sometimes as clusters at the membranes of luminal cells of well-canalised ducts, up to their endpieces (**g**, **h**). Claudin-11 is expressed in the cytoplasm of the well-formed arborised and canalised structure (I) (Original magnification ×400). **j–l** Advanced cytodifferentiation: a well-formed and complex ductal system linked to developed acinar lobules is present as a final stage of salivary gland morphogenesis. Claudin-5 is expressed as thin lines at the membranes of luminal cells and surrounding well-developed acinar cells (**j**). Claudin-7 is observed as *thin lines* at the apico-lateral membranes of luminal cells of intercalated ducts and intra-lobular ducts. Acinar lobules are negative (**k**). Claudin-11 is present in the cytoplasm of epithelial cells that compose the intercalated and intra-lobular ducts. Acinar lobules do not express this molecule (**l**) (Original magnification ×400)

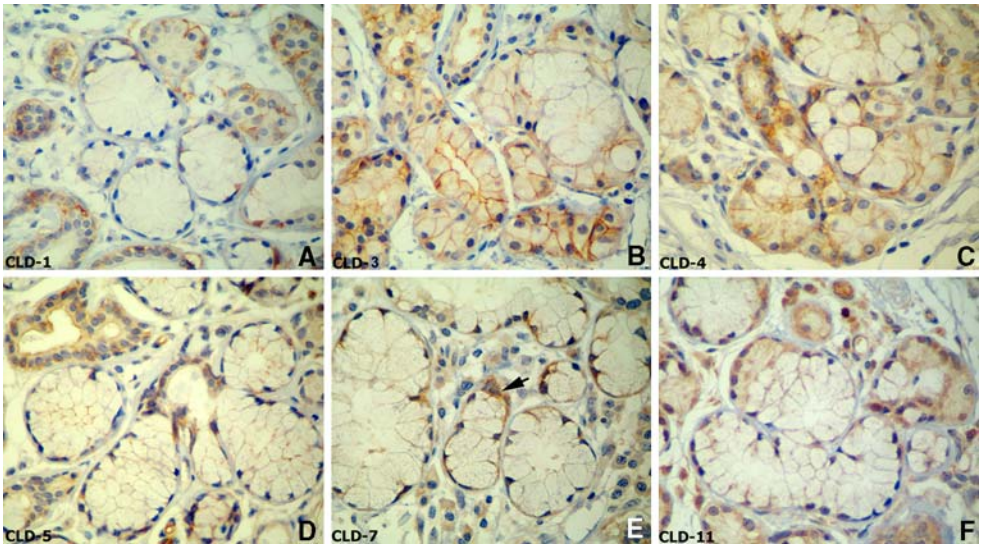

Fig. 3 Claudins expression in adult human minor salivary glands. **a**, **b** Claudins-1 and -3, respectively: Expression as fine lines mainly delineating apico-lateral membrane of ductal cells (Original magnification ×400). **c** Claudin-4 (Original magnification ×400). **d** Claudin-5: Expression of this claudin is mainly observed as *fine lines* delimitating both apical and basal poles of luminal cells. Weak and eventual expression of claudin-4 is also seen on acinar cells membrane. **e** Claudin-7: Myoepithelial cells are positive for claudin-7. Luminal cells of the intercalated ducts also express this protein (*arrow*) (Original magnification ×400). **f** Claudin 11: Expression of claudin-11 is weak, mainly detected on myoepithelial cells and on cells of the intercalated ducts (Original magnification ×400)

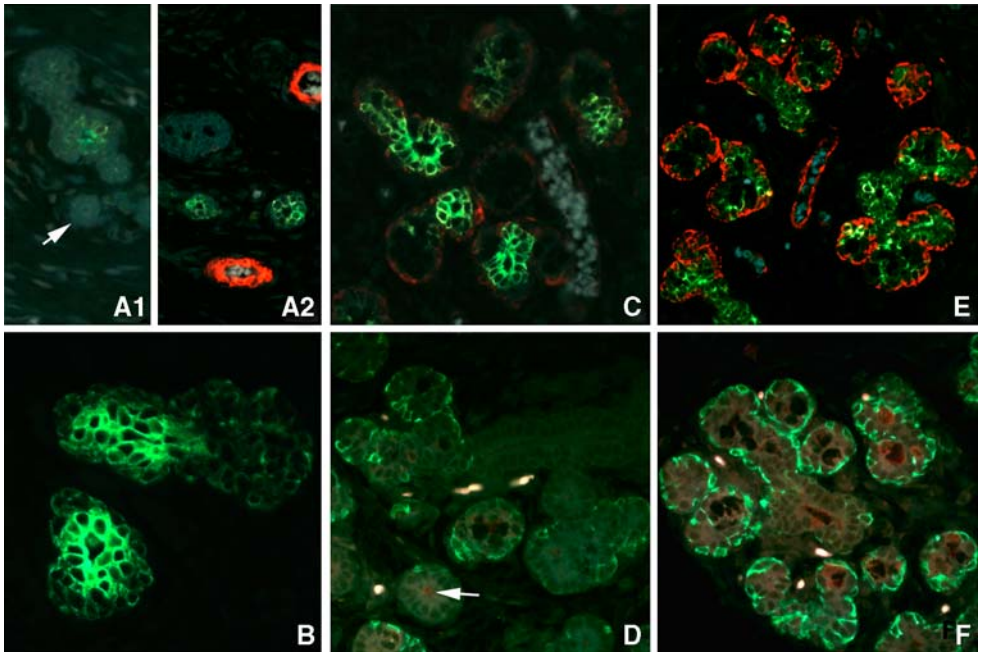

Fig. 4 Immunofluorescence: cytoskeletal and secretion markers of salivary gland maturation. **a1**, **a2, b** Bud/proliferation stage of salivary gland development: at this initial phase of salivary gland development, weak expression of CK LMW/ 35beta H11 (**a1**, **a2**) and CK14 (**b**) are detected in the cytoplasm of a few epithelial cells of the incipient gland islets. Solid epithelial buds are negative for CK LMW/ 35beta H11 (**a1** *arrow*) (Original magnification ×400). **c, d** Branching/canalization phase: Strong expression of CK LMW/35beta H11 (*green*) is observed in cytoplasm of epithelial cells of the branched ductal system. Expression of SMA (*red*) is seen in the cytoplasm of myoepithelial cells surrounding the terminal portion of the branching ducts (**c**). In this further step of salivary gland development, strong expression for CK14 is observed in the cytoplasm of ductal cells (**d**). HSC is detected as clusters in a few lumens (*red*) (**d** *arrow*) (Original magnification ×400). e, **f** Acinar differentiation: At this stage, morphogenesis of salivary gland is advanced with many detectable acinar lobules. Strong expression of SMA (*red*) is observed in the thin cytoplasm of elongated myoepithelial cells around the well-developed acinar lobules. Ductal cells are positive for CK LMW/35beta H11 (*green*), (**g**). At this phase, immunoexpression of CK14 is detected in myoepithelial cells surrounding the acinar lobules (well-developed or rudimentary) and presence of HSC is increased, being present in many luminal and acinar structures (*red*) (**h**) (Original magnification ×400)

(Fig. 4d), and human secretory component (HSC), a marker of salivary gland secretion was detected in the luminal aspect of some ducts and in a few acinar cells (red) (Fig. 4d, arrow). Finally, in advanced cytodifferentiation, CK LMW/ 35beta H11 was positive in the cytoplasm of ductal cells, including cells of intercalated duct (green). Myoepithelial cells surrounding acinar lobules were SMA-positive (red) (Fig. 4e). In this phase CK14 was detected in the cytoplasm of excretory duct cells and in myoepithelial cells (green) and the presence of HSC was now more frequent in the luminal aspect of the ducts and in acinar cells (red) (Fig. 4f).

Discussion

The present work showed, in the unique material of human embryos developing salivary glands, the patterns of claudins expression and its evolution throughout the developmental phases of glandular morphogenesis. These claudins were expressed in region-specific combinations along the process of salivary gland maturation.

Claudins were detected in all stages of salivary gland development examined, with the exception of claudin-1, which was not observed in bud stage and claudin-2, which was not observed in any phase of glandular morphogenesis. This fact is in accordance with the results of other workers who reported similar events in the development of mouse salivary glands (Hashizume et al. 2004; Peppi and Ghabriel 2004). Expression of claudin-2 is observed in cells that have low transepithelial electrical resistance (TER), a measure of the tightness of tight junctions (TJs) (Furuse et al. 2001). This means that cells with lack of claudin-2, as seen in our results, increase their TER, which allows a selective decreased paracellular conductivity for sodium and potassium ions (Amasheh et al. 2002). This phenomenon probably allows advantages in the process of cations changes and may be consistent with the suggested roles of certain segments of salivary glands such as the striated ducts in the physiological production of hypotonic saliva (Dinudom et al. 1993).

Claudins-1, 3, 4, 5 and 7 were expressed as a thin line, mostly at the apico-lateral aspect of the membrane of ductal luminal cells, in patterns described for the localization of TJ (Hashizume et al. 2004; Peppi and Ghabriel, 2004).

Claudin-1 was mostly detected on the membranes of intralobular excretory ducts, differing from the results of other workers who detected this protein mainly in cells of intercalated and striated ducts of rat submandibular glands (Peppi and Ghabriel 2004). This difference may be accounted to the type of gland as we only studied the development of minor salivary glands. Claudin-1 is a component of epithelial and endothelial cells (Furuse et al. 1998). Although the exact physiological role for claudin-1 is not clear, it is possible that this molecule plays important roles in the function of water absorption by these ducts, as newborn mice with claudin-1 deficiency develop severe dehydration leading to death (Furuse et al. 2002).

Claudins-3, 4, 5 and 7 were the tight junction proteins expressed in most segments of the human developing minor salivary glands. Stronger and wider expression of these claudins was mostly observed at the membranes of luminal cells intercalated and striated ducts. Some claudins (claudin-4 and 5) were also detected in the acinar lobules, either transiently or in a more stable type of staining. These results also present some discrepancies with others published on rat developing salivary glands, and these differences may be due to specie-specific claudin patterns or to the type of the gland studied (Peppi and Ghabriel 2004).

The patterns of claudins expression observed during human minor salivary gland morphogenesis probably reveal the basis for a progressive tightening of the epithelium, and may be similar to a proximal to distal tightening reported in other tubular epithelial such as the intestine and nephron (Rahner et al. 2001; Kiuchi-Saishin et al. 2002).

Variations in the tightness of TJ strands are determined by the combination ratios of claudin subtypes (Simon et al. 1999; Tsukita and Furuse 2000; Furuse et al. 2001; Tsukita et al. 2001). Other recent studies have documented selective distribution of individual claudins in various tissues, suggesting that these molecules play a major role in the variability of barrier functions of tight junctions (Mitic et al. 2000; Anderson 2001; Rahner et al. 2001). Differences and region-specific combinations of claudins in salivary glands, since its early phases of development may contribute to the differences in the transepithelial electrical resistance and permeability to molecules between the ducts and the terminal tubules or acini (Hand 1987). It is yet important to note that salivary glands exhibit differences in permeability and quality of salivary secretion depending on the type of nervous stimulation (Hand 1987; Segawa 1994). These changes may involve the transient regulation of adhesion molecules, including those of the tight junctions. In this way, claudin members' interactions and coexpresion may be affected.

Claudins-4 and 5 were the only ones with notable expression on the membranes of acinar cells. Claudin-4 was seen when acinar cells were still immature and claudin-5 was present up to the final maturation of these cells. Previous studies on cell lines suggested that claudin-4 forms pores trough the TJ that discriminate against sodium ions but are indifferent to chloride ions (van Itallie et al. 2001, 2003). Claudin-5 is reported to play roles in the determination and regulation of vascular permeability, controlling the paracellular movement of water and solutes across barriers (Morita et al. 1999). The combined expression of these two

claudins in acinar cells may account for the mechanism of hypotonic saliva production described by other authors (Dinudon et al. 1993; Peppi and Ghabriel 2004).

Unlike the other claudins, claudin-11 showed a cytoplasmic positivity in cells that revealed ductal differentiation. This expression pattern is obscure and may reflect an inactive molecule, deserving further investigation.

Considering the major aspects of claudins expression it has become clear that their presence is wider and stronger as development progresses and this is well illustrated with the increasing evidence of salivary gland maturation markers—cytoskeleton CKs and SMA and HSC. Other workers also reported that expression of claudins seems to be spatially and temporally regulated in development, in a work that involved salivary glands of other mammals (Hashizume et al. 2004).

The present report demonstrated morphologically the presence and distribution of claudins subunits during morphogenesis of human minor salivary glands. This expression appears to be related with the maturation phases of salivary glands as demonstrated by the classical markers of salivary gland differentiation. Further studies are now required to unravel obscure points on the roles and interactions of these proteins with other components of tight junctions and other adhesive proteins essential for salivary gland development, final shape and physiological functions.

Acknowledgments FAPESP Grant 02/02676–7. Mrs. Maria Cristina Conceição for histological processing of all specimens

References

Amasheh S, Meiri N, Gitter AH, Schoneberg T, Mankertz J, Schulzke JD, Fromm M (2002) Claudin-2 expression induces cation-selective channels in tight junctions of epithelial cells. J Cell Sci 115:4969–4976

Anderson JM (2001) Molecular structure of tight junctions and their role in epithelial transport. News Physiol Sci 16:126–130

Cook DI, Dinudom A, Komwatana P, Young JA (1998) Control of Na^+ transport in salivary duct epithelial cells by cytosolic Cl- and NA^+. Eur J Morphol 36:67–73

Cutler LS (1989) Functional differentiation of salivary glands. In: Forte J (ed) Handbook of physiology, salivary, pancreatic, gastric and hepatobiliary secretion, vol 3. Am Physiological Soc Press, New York, pp 93–105

Cutler LS (1990) The role of extracellular matrix in the morphogenesis and differentiation of salivary glands. Adv Dent Res 4:27–33

Dinudom A, Young JÁ, Cook DI (1993) Na^+ and Cl^- conductances are controlled by cytosolic Cl^- concentration in the intralobular duct cells of mouse mandibular glands. J Membr Biol 135:289–295

Furuse M, Fuita K, Hiiragi T, Fujimoto K, Tsukita S (1998) Claudin-1 and -2: novel inegral membrane proteins localizing at tight junctions with no sequence similarity to occluding. J Cell Biol 141:1539–1550

Furuse M, Furuse K, Sasaki H, Tsukita S (2001) Conversion of zonulae occludentes from tight to leaky strand type by introducing claudin-2 into Madin-Darby canine kidney I cells. J Cell Biol 153:263–272

Furuse M, Hata M, Furuse K, Yoshida Y, Haratake A, Sugitani Y, Noda T, Kubo A, Tsukita S (2002) Claudin-based tigiht junctions are crucial for the mammalian epidermal barrier: a lesson from claudin-1 deficient mice. J Cell Biol 156:1099–1111

Guyton AC, Hall JE (2000) Textbook of Medical Physiology, 10th edn. Chapter 64. WB Saunders Company, Philadelphia, pp 738–753

Hand AR (1987) Functional ultrastructure of the salivary glands. In: Sreebny LM (ed) The salivary system. CRC press, Florida, pp 44–67

Hashizume A, Ueno T, Furuse M, Tsukita S, Nakanishi Y, Hieda Y (2004) Expression patterns of claudin family of tight junction membrane proteins in developing mouse submandibular gland. Dev Dyn 231:425–431

Kashimata M, Gresik EW (1996) Contemporary approaches to the study of salivary gland morphogenesis. Eur J Morphol 34:143–147

Kiuchi-Saishin Y, Gotoh S, Furuse M, Takasuga A, Tano Y, Tsukita S (2002) Differential expression patterns of claudins, tight junction membrane proteins in mouse nephron segments. J Am Soc Nephrol 13:875–886

Lourenço SV, Kapas S (2005) Integrin expression in developing salivary glands. Histochem Cell Biol 124:391–399

Lourenço SV, Lima DMC, Uyekita SH, Schultz R, de Brito T (2007) Expression of beta 1 integrin in human developing salivary glands and its parallel relation with maturation markers: in situ hybridization and immunofluorescence study. Arch Oral Biol (in press)

Martins MD, Araújo VC, Raitz R, Araújo NS (2002) Expression of cytoskeletal proteins in developing human minor salivary glands. Eur J Oral Sci 110:316–321

Mitic LL, Anderson JM (1998) Molecular architecture of tight junctions. Annu Rev Physiol 60:121–142

Mitic LL, Van Itallie CM, Anderson JM (2000) Molecular physiology and pathophisiology of tight junctions. I. Tight junction structure and function: lessons from mutant animals and proteins. Am J Physiol Gastrointest Liver Physion 279(2):G250–G254

Morita K, Sasaki H, Furuse M, Tsukita S (1999) Endothelial claudin: claudin-5/TMVCF constitutes tight junction strands in endothelial cells. J Cell Biol 147:185–194

Peppi M, Ghabriel MN (2004) Tissue-specific expression of the tight junction proteins claudins and occudin in the rat salivary glands. J Anat 205:257–266

Rahner C, Mitic LL, Anderson JM (2001) Heterogeneity in expression and subcellular localization of claudins 2, 3, 4, and 5 in the rat liver, pancreas, and gut. Gastroenterol 120:411–422

Segawa A (1994) Tight junctional permeability in living cells: dynamic changes directly visualized by confocal laser microscopy. J Electron microsc (Tokyo) 43:290–298

Simon DB, Lu Y, Choate KA, Velásquez H, Al- Sabban E, Praga M, Casari G, Bettinelli A, Colussi G, Rodríguez-Soriano J, Lifton RP (1999). Paracellin-1, a renal tight junction protein required for paracellular Mg^{2+} resorption. Science 285:103–106

Tsukita S, Furuse M (2000) Pores in the wall: claudins constitute tight junction strands containing aqueous pores. J Cell Biol 149:13–16

Tsukita S, Furuse M, Itoh M (2001) Multifunctional strands in tight junctions. Nat Rev Mol Cell Biol 2:285–293

Van Itallie CM, Fanning AS, Anderson JM (2003) Reversal of charge selectivity in cation or anion-selective epithelial lines by expression of different claudins. Am J Physiol Renal Physiol 285:F1078-F1084

Van Itallie CM, Rahner C, Anderson JM (2001) Regulated expression of claudin-4 decreases paracellular conductance through a selective decrease in sodium permeability. J Clin Invest 107:1319–1327

available at www.sciencedirect.com

ScienceDirect

journal homepage: www.intl.elsevierhealth.com/journals/arob

Expression of beta-1 integrin in human developing salivary glands and its parallel relation with maturation markers: *In situ* hybridisation and immunofluorescence study

Silvia Vanessa Lourenço [a,b,c,*], *Dirce Mary C. Lima* [b], *Sabrina Hitomi Uyekita* [b], *Regina Schultz* [d], *Thales de Brito* [b]

[a] *General Pathology Department, Dental School, University of São Paulo, Brazil*
[b] *Immunopathology Laboratory, Tropical Medicine Institute, University of São Paulo, Brazil*
[c] *Dermatology Department, Medical School, University of São Paulo, Brazil*
[d] *Pathology Division, Hospital das Clínicas, Medical School, University of São Paulo, Brazil*

ARTICLE INFO

Article history:
Accepted 14 May 2007

Keywords:
Salivary gland development
Human
Beta-1 integrin

ABSTRACT

Background and objective: Salivary gland development entails co-ordinated processes involving complex molecular interactions in which integrins have a fundamental role. The integrins are a family of heterodimeric transmembrane receptors comprising alpha and beta subunits that mediate intercellular and extracellular signals involved in the organisation of cells in tissues and organs during development. The beta-1 integrin in particular have been implicated in proliferation and differentiation of cells involved in the development of epithelial tissues. To understand the role of beta-1 integrin in salivary gland development we have studied its expression in human foetal tissues.

Design: *In situ* hybridisation was used to compare the expression and localisation of integrin beta-1 with differentiation markers in developing human salivary glands obtained from foetuses of 8–24 weeks gestation.

Results: Integrin beta-1 first appeared during bud stage in a few cells and its distribution increased as salivary gland morphogenesis progressed. This increased pattern of beta-1 integrin expression was coincident with the appearance of the differentiation markers CK14, CK low MW and smooth-muscle actin.

Conclusions: The developmentally regulated expression of integrin beta-1 in association with the establishment of a mature phenotype indicated by salivary gland tissue differentiation markers is suggestive of its role in salivary gland morphogenesis.

1. Introduction

The position and shape of organs is determined by the co-ordinated activity of groups of primitive cells with each other and with surrounding cells. Cell shape changes, rearrangements and movements, often accompanied by regulated cell proliferation and/or cell death, are the primary mechanisms for generating the final shape of a functional mature organ. Although there is limited information available on how these cellular activities are co-ordinated, the expression of specific

* *Corresponding author at*: Instituto de Medicina Tropical de São Paulo, Av Dr Enéas de Carvalho Aguiar, 500, 2° andar, CEP 05403-000, São Paulo, SP – Brazil. Tel.: +55 11 3061 7065; fax: +55 11 3061 7065.
E-mail address: sloducca@usp.br (S.V. Lourenço).
0003–9969/$ – see front matter
doi:10.1016/j.archoralbio.2007.05.002

cell surface ligands and receptors tightly linked in a complex web of signalling pathways that regulate cell division, migration and differentiation is essential feature of organ development.[1]

Similar to other organs the formation of the salivary gland involves co-ordination of morphogenetic mechanisms, including regulated cell shape changes and gene expression, and directed cell migration leading to a fully developed gland with important secretory functions. Morphologically, all salivary glands develop similarly, with formation starting with the proliferation of a solid cord of cells from the epithelium of the stomatodeum into the underlying ectomesenchyme. This cord of cells extends deeply into the ectomesenchyme, branches extensively, forming canals with secretory end pieces.[2,3] The molecular mechanisms driving the development sequence of salivary gland appear to involve orchestration of different adhesion molecules and, in a series of studies, we have shown that interactions between cells and extracellular matrix are important in salivary gland biology and disease.[4–6] These interactions are partially mediated by integrins, a family of heterodimeric transmembranic molecules composed by alpha and beta subunits.[7] These heterodimers are divided into subfamilies on the basis of the beta subunit and those of the beta-1 subfamily bind chiefly to components of the extracellular matrix.[7,8] In addition to their cell attachment properties, integrins have been implicated in the maintenance of intercellular contacts as well as being involved in other dynamic biological mechanisms such as cell signalling and regulation of gene expression leading to proliferation and differentiation.[7,9,10]

Darribère et al.[11] showed that integrins are fundamentally important in cellular differentiation involved in embryogenesis beginning at the fertilisation stage and through organogenesis. This knowledge has been applied to studies of the mammary and salivary gland epithelium and the key role of beta-1 integrin plays in glandular morphogenesis and differentiation verified.[6,12,13] In salivary glands, however, the expression of this adhesion molecule and its relationship to the glandular development sequence has not been elucidated. Given the importance of the beta-1 integrin in cell adhesion and signalling in various tissues and organs and in developmental processes, the objective of this study was to evaluate the temporo-spatial expression of integrin beta-1 during human salivary gland development using *in situ* hybridisation. To determine the relationship of integrin beta-1 expression with salivary gland morphogenesis the study included the analysis of classical cytoskeletal markers of salivary gland structures.

2. Material and methods

Specimens from the oral cavity of 26 human foetuses at 8–24 weeks of gestation were obtained from the Medical School of the University of São Paulo and in accordance with authorisation of the Ethical Committee of this institution. The specimens were collected from different oral sites, including the buccal mucosa, tongue, mandible and hard palate. All specimens were fixed in buffered formalin and embedded in paraffin. Sections of the specimens were stained with haematoxylin and eosin to check for the presence of salivary glands and to study their morphology and determine their developmental phase. Those presenting developing major or minor salivary glands were selected for the present analysis. Three specimens of adult, fully developed salivary gland were also included in the study for comparative analysis of the expression patterns of integrin beta-1.

3. *In situ* hybridisation

To assess the expression of integrin beta-1 in the specimens selected, an oligonucleotide probe was synthesised to detect beta-1 integrin based on the published sequence of this molecule.[13] Probe (5′-3′ AAA TTC CTG AGC TTA GCT GGT GTT GTG CTA ATG TSS GGC ATC ACA GTC TTT TCC ACA AAT) (GenBank accession number X07979) is a sense biotin-labelled probe complementary to the sequences used for PCR. As a negative control, a biotin-labelled scrambled probe was employed following the same protocol (5′-3′ CCG TGT GGG ACG GAA CTT ACG CGA TSS CGG CAG ACT AAT AGC AGT CGG AAG GTC CAT). For ISH, 5 μm sections were de-paraffinised, re-hydrated through a graded series of ethanol, and washed with water treated with 0.1% diethylpyrocarbonate (DEPC) for 5 min. The sections were incubated with 25 μg/mL of proteinase K (Sigma, St. Louis, MO, USA) in PBS for 10 min at 37 °C and then permeabilised with 2% Triton in Tris–HCl 10 mM, at room temperature. These sections were rinsed with DEPC for 10 min and incubated at 95 °C for 7 min in hybridisation buffer (50% dextran sulphate, 20× SSC, 50× Denhart's, 10 mg/mL of salmon sperm DNA, 10 mg/mL of inorganic pyrophosphate in 1 M Tris buffer, pH 7.4, deionised formamide, and DEPC). The sections were then incubated overnight at 55 °C, with the corresponding probe, at a concentration of 1 μM in hybridisation buffer. After incubation, the sections were washed in Tris–HCl, pH 7.4, at 42 °C for 10 min and further washed with water five times for 5 min. The slides containing the tissue sections were then incubated with the subsequent steps of the kit Gen point (Dako Cytomation). The reactions were finally developed with the chromogen 3′3 diaminobenzidine tetrachloride (DAB) (Sigma, St. Louis, MO 63178, USA). The specimens were then lightly counterstained with Carazzi's haematoxylin, dehydrated and mounted with a glass coverslip and a xylene-based mounting reagent. The results were analysed under an optical microscope equipped with a digital camera for image acquisition.

4. Immunofluorescence

Serial sections (3 mm) of the formalin-fixed, paraffin embedded developing salivary glands specimens were re-hydrated and incubated with 1% bovine serum albumin (BSA) and 5% foetal calf serum (FCS) in Tris–HCl pH 7.4 for 60 min at room temperature to suppress non-specific binding of subsequent reagents. The double labelling immunofluorescence reactions were performed in two steps. First, the sections were incubated with the primary antibody, followed by incubation with sheep anti-mouse FITC-conjugated immunoglobulin (Novocastra) (diluted 1:100 in BSA–PBS). Incubation with the

Table 1 – Primary serum, clones, source, and details of working protocol

Primary serum	Clone	Specificity	Source	Antigen retrieval	Working dilution
CK14	LL002	Epitope C-terminal of human CK14, isotype IgG 3	Neomarker	Citrate buffer pH 6.0	1:50
CK low-MW	35beta H11	Epitope not specified, isotype IgM kappa	DAKO	Citrate buffer pH 6.0	1:50
SMA	1A4	Epitope N-terminal, isotype IgG2a kappa	DAKO	Citrate buffer pH 6.0	1:50

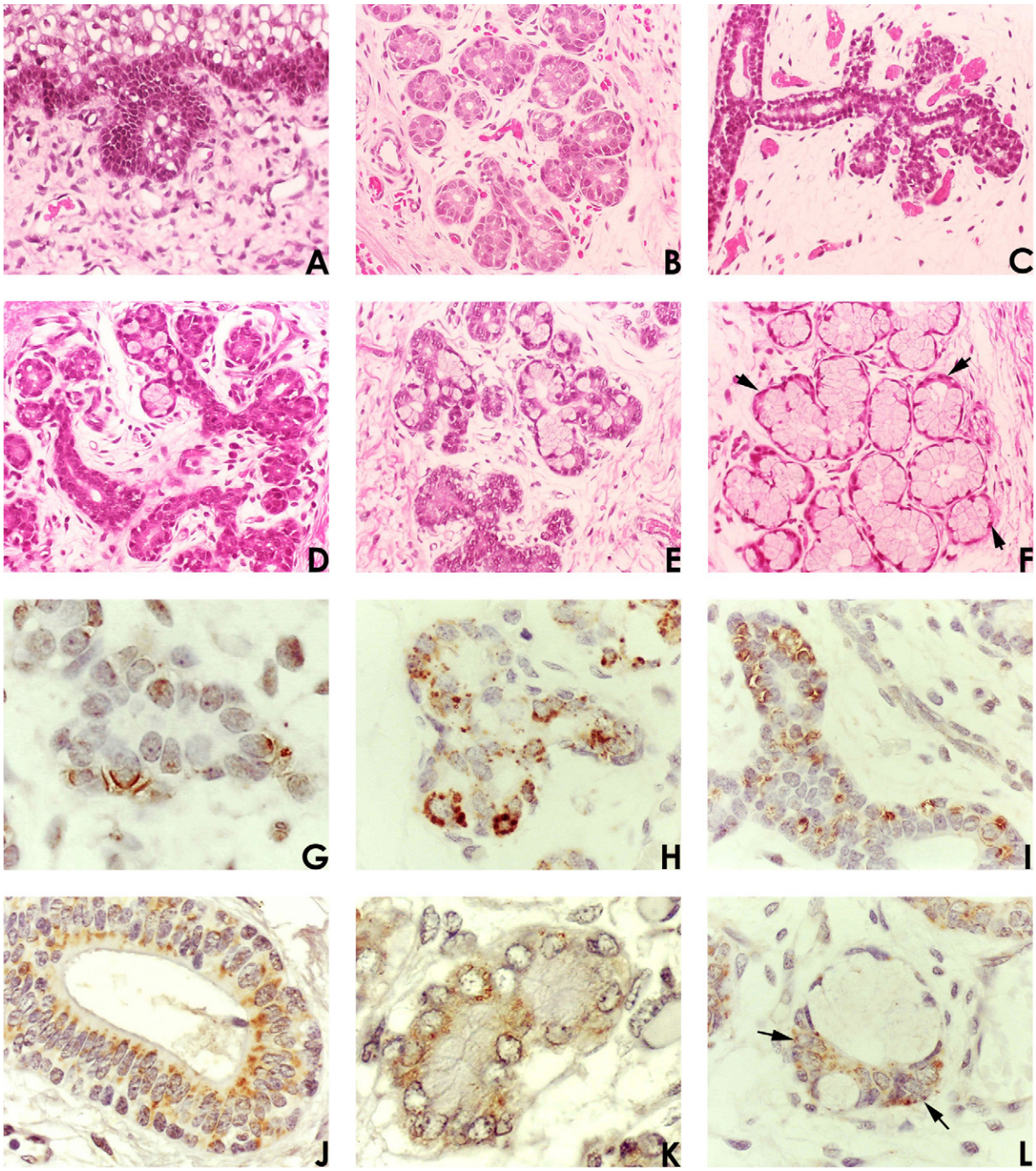

Fig. 1 – (A) Initial phase of salivary gland development—epithelial bud composed of eosinophilic cuboidal cells, invaginating into the mesenchyme from the basal layer of the covering mucosal epithelium (H/E, original magnification ×400). (B) Proliferation/canalisation phase of salivary gland development—presence of epithelial nests with formation of small lumen in the center (H/E, original magnification ×250). (C) Branching/arborisation phase: complex ductal system well formed and canalised (H/E, original magnification ×250). (D and E) Initial phase of acinar differentiation—presence of rudimentary acinic structures (end pieces) in the terminal portion of the branching ductal system (H/E ×250). (F) Advanced acinar

second primary antibody was performed, followed by incubation with goat anti-mouse IgG labelled with red fluorescent Alexa 594 (Molecular Probes) at a concentration of 1:100. The details of the monoclonal primary antibodies used, their source, and working dilutions are described in Table 1. All steps were preceded by two incubations with Tris–HCl pH 7.4 for 5 min at room temperature. The sections were then air dried and mounted with Vecta Shield. The results were analysed and photographed using a Zeiss microscope equipped with epi-illumination and a digital camera with filters for fluorescein and rodamine. Negative controls were treated as above, but a solution of 1% BSA in Tris–HCl pH 7.4 replaced the primary antibody. Specimens incubated with normal serum were used as additional negative controls. Internal positive controls such as basal layer of epithelium were present.

5. Results

The specimens studied were of the major and minor human salivary glands at various stages of development, comprising bud, proliferation, canalisation, branching and cytodifferentiation (Fig. 1A–F).

5.1. *In situ hybridisation (ISH) of human embryonic salivary glands (Fig. 1G–L)*

Salivary glands at the bud stage of development were scarce and only rare cells expressed integrin beta-1, which was located around the cell membrane at their contact with the stroma and, sometimes, as cytoplasmic dots. During the initial steps of proliferation and canalisation stage, a few developing salivary gland ducts could be observed. Beta-1 integrin was present in rare cells, showing a ring-like pattern seen in the basal pole of some ductal cells or around the cell membrane in an intercellular position. When canalisation was more evident, an increased number of ductal cells expressed the beta-1 integrin in a similar pattern as described above and in a punctate pattern around the cell membrane. At the stage of branching and initial cytodifferentiation, beta-1 integrin was present in a greater number of cells, usually as bipolar dots in the cytoplasm and membrane of epithelial cells of the canalised ducts and around the cell membrane. Expression of integrin beta-1 was also seen at the basolateral portion of a few rudimentary developing acinic cells. Expression of this integrin was seen along the more mature ducts, usually showing a bipolar distribution and at the apical pole of luminal cells.

Cytoplasmic signal was increasingly detected as differentiation of salivary gland progressed.

At a subsequent differentiation stage (advanced cytodifferentiation), beta-1 integrin was present at the basolateral portion of some acinic structures and more abundantly in the cells along the ductal system, more frequently as cytoplasmic signals. The ring-like pattern of expression was still observed in a few ductal cells. Finally, adult normal salivary glands, used as controls for the reactions showed expression of integrin beta-1 along all the ductal system. Intercalated ducts showed signal for beta-1 integrin in a cell-membrane bipolar pattern. The other segments of salivary gland duct presented expression of integrin beta-1 both in a cytoplasmic and membrane location. Negative controls did not show any signal.

5.2. *Immunofluorescence of human embryonic salivary glands*

At the bud stage of salivary gland development, only a few cells were weakly positive for CK14 (Fig. 2A). During the proliferation and canalisation stage, a few developing salivary gland ducts were observed. In these phases, CK14 and low molecular weight cytokeratin (CK LMW/35beta H11) were present in the ductal epithelial cells and smooth-muscle actin (SMA) was only found in rare cells (Fig. 2B, C, G, H).

At the stage of branching and initial cytodifferentiation, ductal cells were positive for CK 14 (Fig. 2D). Luminal cells of the developing ductal system were positive for CK LMW/35beta H11. Smooth-muscle actin was detected in cells of the terminal portion of the ductal system and in cells that surrounded the rudimentary acinic lobules (Fig. 2 I and J). At late acinar cytodifferentiation, CK14 was detected in the cytoplasm of basal cells of the ductal system. Myoepithelial cells were positive for CK14 and SMA. CK LMW/35beta H11 was seen on luminal cells of the ductal system (Fig. 2E, F, K and L).

6. Discussion

Our results demonstrated that the expression of beta-1 integrin in different patterns along the process of differentiation of human salivary glands increased as development progressed, suggesting that it may be an indicator of salivary gland maturation. The demonstration of integrin beta-1 mRNA using the very sensitive technique of *in situ* hybridisation complemented the results of our previous work in which the beta-1 integrin protein was demonstrated the using

differentiation: mucous acinar lobules well developed, composed by pyramidal cells with large and clear cytoplasm and surrounded by thin elongated myoepithelial cells (arrow) (H/E original ×400). (G) Initial phase of proliferation/canalisation: expression of beta-1 integrin concentrated of the baso-lateral portion of the membrane in a few epithelial cells (*in situ* hybridisation, original magnification ×400). (H and I) Canalisation/arborisation of the developing ductal system: increased expression of beta-1 integrin on the membrane of ductal cells. Note in (H), the marked expression of the molecule in a dotted pattern surrounding the entire cell membrane (*in situ* hybridisation, original magnification ×250). (J) Fully developed excretory duct: expression of beta-1 integrin in a bipolar pattern in the various layers of ductal cells (*in situ* hybridisation, original magnification ×250). (K) Initial phase of acinar differentiation: expression of beta-1 integrin around the cell membrane and in peri-nuclear position of the immature acinar cells (*in situ* hybridisation, original magnification ×400). (L) Fully developed acinar lobule: expression of beta-1 integrin concentrated in the cells of the intercalary-acinar unit (arrows) (*in situ* hybridisation, original magnification ×400).

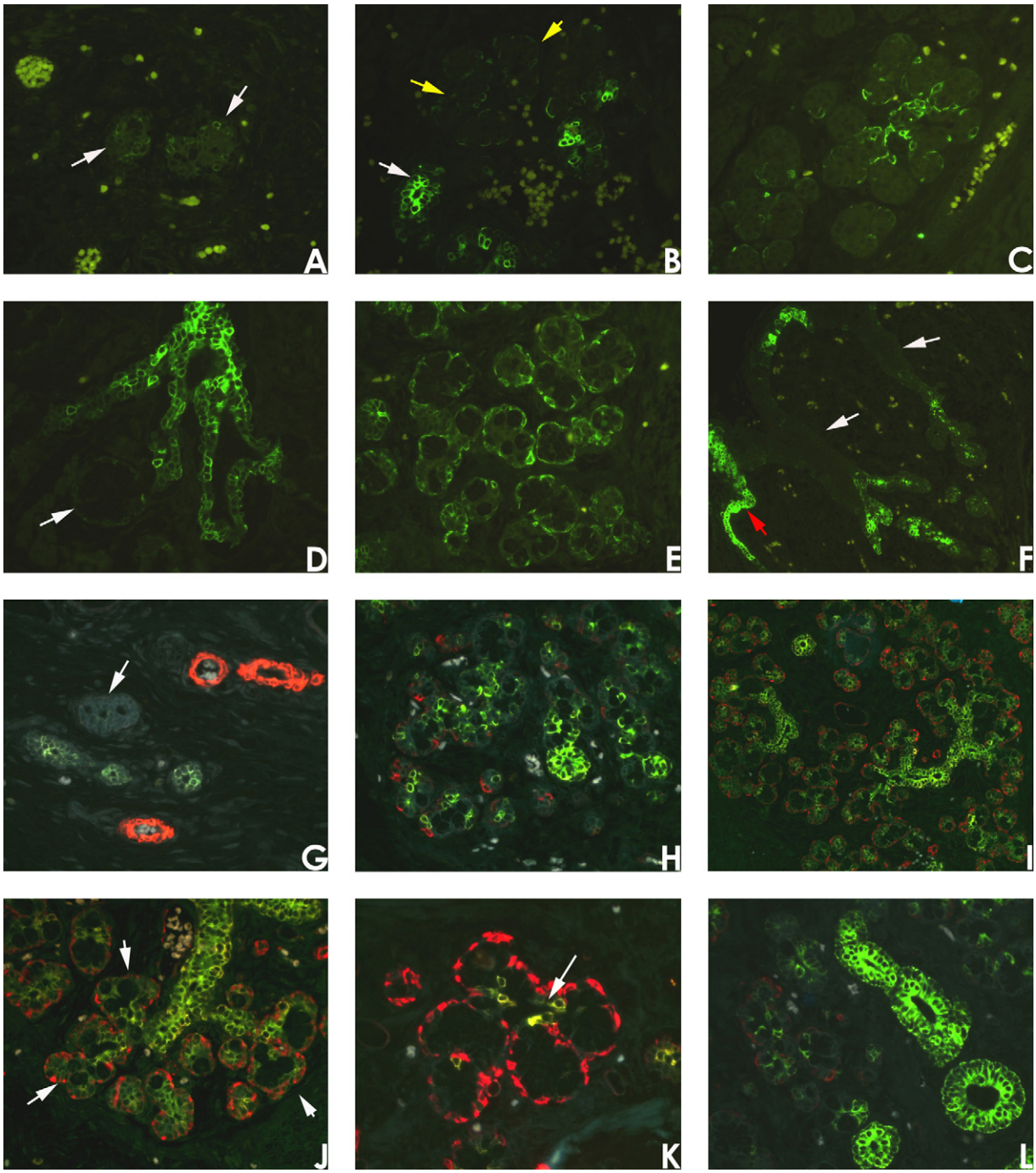

Fig. 2 – (A) Bud stage of salivary gland development: weak expression of CK14 in is detected in the cytoplasm of a few epithelial cells of the incipient gland islets (arrows) (original magnification ×400). (B and C) Proliferation/canalisation phase: epithelial structures exhibiting strong expression of CK14 in the cytoplasm of ductal cells. Observe in (C) a well-formed and canalised salivary gland structure (arrow). Other further developed structures start to present weak positivity surrounding epithelial lobules, probably representing the initial maturation of myoepithelial cells (yellow arrow) (original magnification ×250 (B) and ×400 (C)). (D) Branching phase: in this stage presence of CK 14 is observed in a greater number of cells of the ductal system of the developing gland (original magnification ×400). (E) Acinar differentiation: acinar lobules that present immunoexpression of CK14 in myoepithelial cells surrounding the acinar lobules (original magnification ×400). (F) Well-developed excretory ducts: strong expression of CK14 is observed in the cytoplasm of basal keratinocytes of the lining mucosa epithelium (red arrow) and in cytoplasm the well-formed ductal system of the salivary gland. Note that the portion of the duct next to the covering epithelium is still negative for this marker (white arrow) (original magnification ×400). (G) Initial phase of proliferation/canalisation: a few canalising epithelial lobules of developing salivary glands present weak cytoplasmic positivity for CK LMW/35beta H11 (green). SMA (red) is only detected in blood vessels walls in this phase. Note the presence of more rudimentary salivary gland lobules still negative for CK LMW/35beta H11 (arrow) (original

immunohistochemistry.[6] In this study, double labelling immunofluorescence was used to identify and highlight the presence of classical cytoskeletal markers of salivary gland differentiation.

To date, little is known of the molecular mechanisms that regulate the development of the human salivary gland. As with other glands and tissues, it is very likely that development is co-ordinated via several integrated events affecting proliferation, morphogenesis and cell–substratum interactions. These events are tightly regulated both temporally and spatially.[14] Differentiation of salivary glands begins around week 6 of foetal development when specific oral epithelium cells undergo organised, co-ordinated growth that is based on epithelio–mesenchymal interactions, leading to morphogenesis and cytodifferentiation.[15,16] Integrins appear to be key molecules involved in these interactions and perturbations of their expression can lead to impaired glandular form and function. For example, Menko et al.[17] have demonstrated that the absence of the integrin dimer alpha3beta1 affects multiple components of adhesive complexes and their associated signalling pathways in salivary glands. These include profound alterations in the signalling cascade that involves Cdc42 and RhoA, two Rho GTPases that regulate the organisation of the actin cytoskeleton.[17]

The role of beta-1 integrin has been investigated in other tissues and its importance in their developmental processes is being established. In mammary glands, which display a similar morphology to the salivary glands, perturbation of beta-1 integrin results in impaired development and differentiation of the secretory epithelium.[18] Supporting this, Naylor et al.[13] has shown that the disturbance of mammary gland lobular development in mice is due to the lack of beta-1 integrin which manifest as defects in epithelial proliferation triggered by the absence of this molecule.

During the initial stages of human salivary gland morphogenesis – bud stage – beta-1 integrin, was present in scattered cells and as differentiation progressed, it was expressed in an increasing number of cells. These results suggest that beta-1 integrin is important in the initial phase of salivary gland development, when interactions between the bud epithelial cells and their newly formed extracellular environment occur. In a parallel analysis, double staining immunofluorescence showed none of the classical cytoskeletal differentiation markers, indicating that the glandular tissue is very immature at this phase. This result is in accordance with a previous report by Martins et al.[19] who did not find any markers of differentiation in the very early stage of salivary gland development. With further differentiation, expression of beta-1 integrin increases, creating new connections likely to be important for subsequent steps in gland development.

In early stages of salivary gland canalisation, beta-1 integrin was expressed in a peculiar ring-like pattern in some cells of the developing ductal network. Analogous to the results of other authors, whose studies have implicated beta-1 integrin as a marker of the stem cell niche in mammary gland and skin,[20] it is conceivable that these cells may represent very primitive, pluripotent cells of the salivary gland tissue. Additionally, extracellular matrix proteins may modulate the expression and activation of beta-1 integrins in these cells, and local variation in the composition of basement membrane during the gland development might play a role in establishing and maintaining their distribution.[20]

At the canalisation stage when beta-1 integrin is also well identified in cells of the ductal network, more differentiation markers are detected in the developing salivary glands, which stain for CK14 and CK LMW/35beta H11, indicating that cytodifferentiation has progressed. Integrin receptors and ligands have been shown to activate signalling pathways involving mitogen-activated protein kinases, tyrosine kinases or GTP-binding proteins. These are thought to affect cell cytoskeleton and proliferative responses that are required during organ development.[21] However, this relationship has yet to be shown at the molecular level in human salivary gland development. On the basis of the present morphological evidence, functional studies, possibly using tissue culture or animal models are imperative for substantiating the suggestions made from these morphological observations.

In advanced canalisation stage of salivary gland development, beta-1 integrin was present in a greater number of cells, with signals detected either on the membrane or in the cytoplasm. The differential mRNA localisation may reflect a novel type of post-transcriptional control involved in many cellular processes, including the regulation of cellular asymmetry required for creating and maintaining cell polarity, which is important for cellular differentiation during development. Thus, site-specific localisation of mRNA in the cytoplasm may provide an important mechanism whereby specialised proteins can be expressed at discrete sites within the cell.[21,22] In developing salivary glands, the presence of beta-1 integrin at these locations may be important for the protein transcription locally, which later may determine cell polarity to prepare glandular structures for their secretory functions. Also, some cells still retained the ring-like pattern of beta-1 integrin expression. Other cells of the branched ductal system expressed beta-1 integrin at the basolateral surface of the membrane. This varied morphological pattern of expression suggests that integrins might play diverse roles in the process of salivary

magnification ×400). (H and I) Canalisation/branching phase: strong expression of CK LMW/35beta H11 (green) is observed in cytoplasm of epithelial cells of the branched ductal system. Initial expression of SMA (red) is seen in the cytoplasm of myoepithelial cells surrounding the terminal portion of the branching ducts (original magnification ×400 and ×250, respectively). (J) Initial phase of acinar differentiation: expression of CK LMW/35beta H11 (green) is detected in the cytoplasm of epithelial cells of the ductal system. Smooth muscle actin (red) is present in the cytoplasm of myoepithelial cells surrounding the incipient acinic structures (arrows) (original magnification ×400). (K) Well-formed acinar lobules: strong expression of SMA (red) is observed in the thin cytoplasm elongated myoepithelial cells around the well-developed acinar lobules. A few cells are positive for CK LMW/35beta H11 (green), probably representing intercalated duct cells (arrow) (original magnification ×600). (L) Well-developed ductal system: epithelial cells showing cytoplasmic strong positivity for CK LMW/35beta H11 (green) (original magnification ×400).

gland development, either in the differentiation and maintenance of the salivary gland phenotype, mediating a close relationship between gland parenchyma and extracellular matrix and also being associated with glandular functions, as reported by others (see [1] for review). This pattern of distribution is thought to be involved in the stable attachment of stationary epithelial cells to the matrix and in the maintenance of cell–cell interactions,[23] suggesting that integrin beta-1 expression might be a cell-membrane indicator of the evolutionary steps of salivary gland morphogenesis. At this time, the phenotype of cells that comprise the main structure of the developing gland is well defined by the expression of CK14, CK LMW/35beta H11 and SMA, which provide a parallel demonstration of glandular maturation.

In late stages of salivary gland development, indicated by branching and cytodifferentiation of acinar cells, beta-1 integrin mimics the patterns seen in the normal adult salivary gland structures. Thus, beta-1 integrin showed a cytoplasmic expression in the apical pole of luminal cells, as well as basolateral portion of ductal cells. This phenomenon may account for the secretory functions of salivary glands and is similar to what has been observed in other secretory organs such as stomach and breast.[23–25] Cytoskeletal markers of salivary gland differentiation are present in this phase of the gland development in specific patterns, close to those classically described in adult glands.[19,26,27] The increase in the expression of beta-1 integrin and markers of differentiation as salivary gland development and differentiation confirms the requirement for this integrin in maintaining tissue-specific functions. For instance, being implicated in the control, of mammary gland differentiation.[13,28]

The present research has shown morphological evidence that integrins may be cell membrane indicators of human salivary gland differentiation with a parallel relation with the establishment of a salivary gland mature phenotype disclosed by the classical cytoskeletal differentiation markers. The integrins are developmentally regulated and appear to be sensitive to changes in the gland extracellular microenvironment as morphogenesis progresses. These morphological data provide a cornerstone for future functional and molecular studies that are at present being carried out in our laboratory.

Acknowledgements

Supported by FAPESP grants 02/02676-7 and 03/00450-4 and British Council Academic Link SPA/881/155. Division of Pathology of the Hospital da Clínicas, Medical School, University of São Paulo, for supplying the foetal tissue used in this work. All experiments carried out in this work comply with the laws of the Ethical Committee of the Medical School of the University of São Paulo.

REFERENCES

1. Thiery JP. Cell Adhesion in development: a complex signalling network. *Curr Opin Gen Dev* 2003;**13**:365–71.
2. Dale AC. Salivary gland. In: Ten Cate AR, editor. *Oral histology*. 4th ed. St. Louis: Mosby; 1994. p. 312–33.
3. Klein RM. Development, structure and function of salivary glands. In: Avery JK, editor. *Oral development and histology*. 2nd ed. New York: Thieme; 1994. p. 352–79.
4. Araújo VC, Loducca SVL, Sousa SOM, Williams DM, Araújo NS. The cribriform features of adenoid cystic carcinoma and polymorphous low-grade adenocarcinoma: cytokeratins and integrins expression. *Ann Diagn Pathol* 2001;**5**(6):330–4.
5. Loducca SVL, Raitz R, Araújo NS, Araújo VC. Polymorphous low-grade adenocarcinoma and adenoid cystic carcinoma: distinct architectural composition revealed by collagen IV, laminin and their integrin ligands α2β1 and α3β1. *Histopathology* 2000;**37**:118–23.
6. Lourenço SV, Kapas S. Integrin expression in developing salivary glands. *Histochem Cell Biol* 2005;**124**:391–9.
7. Hynes RO. Integrins: versatility, modulation, and signalling in cell adhesion. *Cell* 1992;**69**:11–25.
8. Hynes RO. Integrins: a family of cell surface receptors. *Cell* 1987;**48**:549–54.
9. Ruoslahti E, Reed JC. Anchorage dependence, integrins, and apoptosis. *Cell* 1994;**77**:477–8.
10. Varner JA, Cheresh DA. Integrins and cancer. *Curr Opin Cell Biol* 1996;**8**:724–30.
11. Darribère T, Skalski M, Cousin H, Gaultier A, Montmory C, Alfandari D. Integrins: regulator of embryogenesis. *Biol Cell* 2000;**92**:5–25.
12. Beauvais-Joneau A, Thierry JP. Multiple roles for integrins during development. *Biol Cell* 1997;**89**:5–11.
13. Naylor MJ, Li N, Cheung J, Lowe ET, Lambert E, Marlow R, et al. Ablation of β1 integrin in mammary epithelium reveals a key role for integrin in glandular morphogenesis and differentiation. *J Cell Biol* 2005;**171**:717–28.
14. Cutler LS, Functional differentiation of salivary glands.Forte J, editor. *Handbook of physiology salivary pancreatic gastric and hepatobiliary secretion*, vol. 3. New York: Am Physiological Soc Press; 1989. p. 93–105.
15. Cutler LS. The role of extracellular matrix in the morphogenesis and differentiation of salivary glands. *Adv Dental Res* 1990;**4**:27–33.
16. Kashimata M, Gresik EW. Contemporary approaches to the study of salivary gland morphogenesis. *Eur J Morphol* 1996;**34**:143–7.
17. Menko AS, Kreidberg JA, Ryan TT, Van Bockstaele E. Loss of alpha3beta1 integrin function results in an altered differentiation program in the mouse submandibular gland. *Dev Dyn* 2001;**220**(4):337–49.
18. Faraldo MM, Deugnier MA, Lukashev M, Thierry JP, Glukhova MA. Perturbation of beta 1-integrin function alters the development of murine mammary gland. *EMBO J* 1998;**17**:2139–47.
19. Martins MD, Araújo VC, Raitz R, Araújo NS. Expression of cytoskeletal proteins in developing human minor salivary glands. *Eur J Oral Sci* 2002;**110**:316–32120.
20. Watt FM, Hogan LM. Out of Eden: stem cells and their niches. *Science* 2000;**287**:1427–30.
21. Jansen RP, Kiebler M. Intracellular RNA sorting, transport and localization. *Nat Strut Mol Biol* 2005;**12**:826–9.
22. Czaplinski K, Singer RH. Pathways for mRNA localization in the cytoplasm. *Trends Biochem Sci* 2006;**31**:687–93.
23. Coraux C, Zahm JM, Puchelle E, Gaillard D. Beta-1 integrins are involved in migration of human fetal tracheal epithelial cells and tubular morphogenesis. *Am J Pathol* 2000;**279**: 224–34.
24. Chénard M, Barque JR, Chailler P, Trembaly E, Beaulieu JF, Ménard D. Expression of integrin subunits correlates with differentiation of epithelial cell lineages in developing human salivary human gastric mucosa. *Anat Embryol* 2000;**202**:223–33.
25. Li N, Zhang Y, Naylor MJ, Schatzmann F, Maurer F, Wintermantel T, et al. Beta-1 integrins regulate mammary

gland proliferation and maintain the integrity of mammary alveoli. *EMBO J* 2005;**24**:1942–53.
26. Draeger A, Nathrath WB, Lane EB, Sundstrom BE, Stigbrand TI. Cytokeratins, smooth muscle actin and vimentina in human normal salivary gland and pleomorphic adenomas. Immunohistochemical studies with particular reference to myoepithelial and basal cells. *APMIS* 1991;**99**(5):405–15.
27. Zarbo RJ, Bacchi CE, Gown AM. Muscle-specific protein expression in normal salivary glands and pleomorphic adenomas: an immunocytochemical study with biochemical confirmation. *Mod Pathol* 1991;**4**(5):621–6.
28. Fuchs E, Cleveland DW. A structural scaffolding of intermediate filaments in health and disease. *Science* 1998;**279**(5350):514–9.

Virchows Arch (2008) 452:427–434
DOI 10.1007/s00428-007-0552-y

ORIGINAL ARTICLE

Developing human minor salivary glands: morphological parallel relation between the expression of TGF-beta isoforms and cytoskeletal markers of glandular maturation

Silvia Vanessa Lourenço · Sabrina Hitomi Uyekita · Dirce Mary Correia Lima · Fernando Augusto Soares

Received: 26 June 2007 / Revised: 15 October 2007 / Accepted: 14 November 2007 / Published online: 14 December 2007

Abstract Morphogenesis of salivary glands involves complex coordinated events. Synchronisation between cell proliferation, polarisation and differentiation, which are dependent on epithelial–mesenchymal interactions and on the microenvironment, is a requirement. Growth factors mediate many of these orchestrated biological processes and transforming growth factor-beta (TGF-beta) appear to be relevant. Using immunohistochemistry and immunofluorescence, we have mapped the distribution of TGF-beta 1, 2 and 3 and compared it with the expression of maturation markers in human salivary glands obtained from foetuses ranging from weeks 4 to 24 of gestation. TGF-beta 1 first appeared during canalisation stage in the surrounding mesenchyme and, in the more differentiated stages, was expressed in the cytoplasm of acinar cells throughout the adult gland. TGF-beta 2 was detected since the bud stage of the salivary gland. Its expression was observed in ductal cells and increased along gland differentiation, TGF-beta 3 was detected from the canalisation stage of the salivary gland, being weakly expressed on ductal cells, and it was the only factor detected on myoepithelial cells. The data suggest that TGF-beta have a role to play in salivary gland development and differentiation.

Keywords Transforming growth factor-beta · Salivary glands · Development

S. V. Lourenço · F. A. Soares
Department of General Pathology, Dental School,
University of São Paulo,
São Paulo, Brazil

S. V. Lourenço · D. M. C. Lima
Laboratory of Immunopathology, Institute of Tropical Medicine,
São Paulo, Brazil

S. V. Lourenço · S. H. Uyekita
Department of Dermatology, Medical School,
University of São Paulo,
São Paulo, Brazil

F. A. Soares
Hospital do A.C. Camargo,
São Paulo, Brazil

S. V. Lourenço (✉)
Disciplina de Patologia Geral, Faculdade de Odontologia,
Universidade de São Paulo,
Av Prof Lineu Prestes, 2227,
CEP: 05508-000 São Paulo, Brazil
e-mail: sloducca@usp.br

Introduction

All salivary glands develop in a similar manner. Formation starts with the proliferation of a solid cord of cells from the epithelium of the stomatodeum into the underlying ectomesenchyme. This cord of cells extends deeply into the ectomesenchyme and branches extensively. These cells then canalise by degradation of the central cells to form the ductal system and the terminal secretory end pieces. The epithelial ingrowths constitute the parenchyme of a salivary gland. The ectomesenchyme differentiates to form the connective tissue component of the gland, which supports the parenchyma.

Minor salivary glands begin to develop at 4–6 weeks of embryonic life. Branches from parasympathetic and sympathetic nerves migrate to the gland and the collecting veins are formed. Salivary gland development consists of a series of ducts ending in terminal secretory end pieces, grape-like in structure.

Table 1 Primary serum, clones, source and details of working protocol

Primary serum	Clone	Source	Antigen retrieval	Working dilution
CK14	LL002	Neomarker	Citrate buffer pH 6.0	1:50
CK low-MW	35βH11	DAKO	Citrate buffer pH 6.0	1:50
SMA	1A4	DAKO	Citrate buffer pH 6.0	1:50

To date, little is known of the key regulators of human salivary gland development and function. In most systems, there is a requirement of co-ordination between cell proliferation, polarisation and differentiation. These processes are dependent on epithelial–mesenchymal interactions and on the microenvironment. Temporal and spatial regulation of these events is likely to be important to salivary gland development and for proper tissue function, and our group has been investigating several of these aspects [20].

Hormones and growth factors mediate many of these highly orchestrated biological processes that occur during development, and the transforming growth factor-beta (TGF-beta) family is probably relevant for these processes. TGF-beta is a multifunctional growth factor that has several biological effects in vivo, including control of cell growth and differentiation, cell migration, lineage determination, motility, adhesion, apoptosis, synthesis and degradation of extracellular matrix, and it plays an important role in regulating tissue repair and regeneration [10, 22, 26, 28]. Multiple TGF-beta subunits are expressed during early embryonic morphogenesis in different order and levels which appear to have specific transcriptional regulation, fundamental in the induction and maintenance of differentiated cell types during craniofacial development [2].

The aim of this study was to study the expression and distribution of TGF-beta 1, 2 and 3 in the developing human salivary gland and its parallel relationship with morphology and maturation markers of these glands.

Materials and methods

Tissue preparation

Thirty post-mortem human foetuses at 4th to 24th weeks of gestation were obtained from the Medical School of the University of São Paulo (in accordance with authorisation of the Ethical Committee of this institution). Specimens of oral cavity were collected from different sites, including buccal mucosa, tongue, mandible and hard palate. Fully developed salivary gland specimens were retrieved from the archives of the Laboratory of Dermatopathology of the same institution and were used as controls. All specimens were fixed in 10% buffered formalin for 24 h and embedded in paraffin. Haematoxylin and eosin slides were used to check for the presence of salivary glands and to study their morphology. Those presenting developing minor salivary glands were selected for the present analysis.

Immunohistochemistry

Three-micrometer serial sections of the specimens were incubated in 3% aqueous hydrogen peroxide for 30 min to quench endogenous peroxidase activity and with 1% bovine serum albumin (BSA) and 5% foetal calf serum (FCS) in Tris–HCl pH 7.4 for 60 min at room temperature to suppress non-specific binding of subsequent reagents.

Fig. 1 TGF-beta isoforms expression in developing salivary glands. ▶ **a1**, **a2**, **a3** Bud stage. **a1** There is no evidence of TGF-beta 1 expression in epithelial cells of the very initial phase of salivary gland development (streptavidin–biotin peroxidase, original magnification ×400). **a2** Expression of TGF-beta 2 in the cytoplasm of a few cells of the solid nest of developing salivary gland (streptavidin–biotin peroxidase, original magnification ×400). **a3** Weak expression of TGF-beta 3 around epithelial cells of the budding human minor salivary gland (*arrow*) (streptavidin–biotin peroxidase, original magnification ×400). **b1**, **b2**, **b3** Canalisation stage. **b1** Expression of TGF-beta 1 in the stroma surrounding the canalising ductal system (streptavidin–biotin peroxidase, original magnification ×400). **b2** Strong TGF-beta 2 expression in the cytoplasm of scattered epithelial cells of the canalising ductal system (streptavidin–biotin peroxidase, original magnification ×400). **b3** Weak expression of TGF-beta 3 on the luminal pole of the ductal cells of the canalising ductal system (streptavidin–biotin peroxidase, original magnification ×400). **c1**, **c2**, **c3** Branching stage. **c1** Strong expression of TGF-beta 1 in the cytoplasm of the initial developing mucous cells at the end tips of the branching salivary gland (streptavidin–biotin peroxidase, original magnification ×400). **c2** Strong expression of TGF-beta 2 in the cytoplasm of epithelial cells that compose the entire ductal system of the branching salivary gland including the intercalated duct located at the junction of the future acinar lobules (streptavidin–biotin peroxidase, original magnification ×400). **c3** Expression of TGF-beta 3 in the cytoplasm of the epithelial cells of the ductal system and in the myoepithelial cells that surround the developing mucous cells at the end tips of the branching salivary gland (*arrows*) (streptavidin–biotin peroxidase, original magnification ×400). **d1**, **d2**, **d3** Cytodifferentiation stage. **d1** Strong expression of TGF-beta 1 in scattered well-developed acinar cells forming the acinic lobules at the end tips of the developing salivary gland (streptavidin–biotin peroxidase, original magnification ×400). **d2.1**, **d2.2** Strong expression of TGF-beta 2 in the cytoplasm of the well-developed ducts including the intercalated duct at the ductal/acinar junction (**d2.1** *arrow*). **d3.1**, **d3.2** Strong expression of TGF-beta 3 in myoepithelial cells surrounding the well-differentiated acinar lobules (**d3.1**) and mild expression of TGF-beta 3 in the cytoplasm of epithelial cells forming an excretory duct (**d3.2**) (streptavidin–biotin peroxidase, original magnification ×400)

They were then incubated with 0.5% pepsin in phosphate-buffered saline (PBS) at 37°C pH 1.8 for 30 min for antigen retrieval, followed by incubation overnight with the primary antibodies—rabbit polyclonal against TGF-beta 1 (clone sc-146), TGF-beta 2 (clone sc-90) and TGF-beta 3 (clone sc-82), all obtained from Santa Cruz Biotechnology (Santa Cruz, CA, USA), used in a title of 1:150. The reaction followed with incubation with the indirect dextran polymer detection system (En Vision—Dako, Carpinteria, CA, USA). Staining was completed by incubation with 3′3 diaminobenzidine tetrachloride (DAB) for 3 min. Counter-staining with Mayer's haematoxylin, dehydrating and

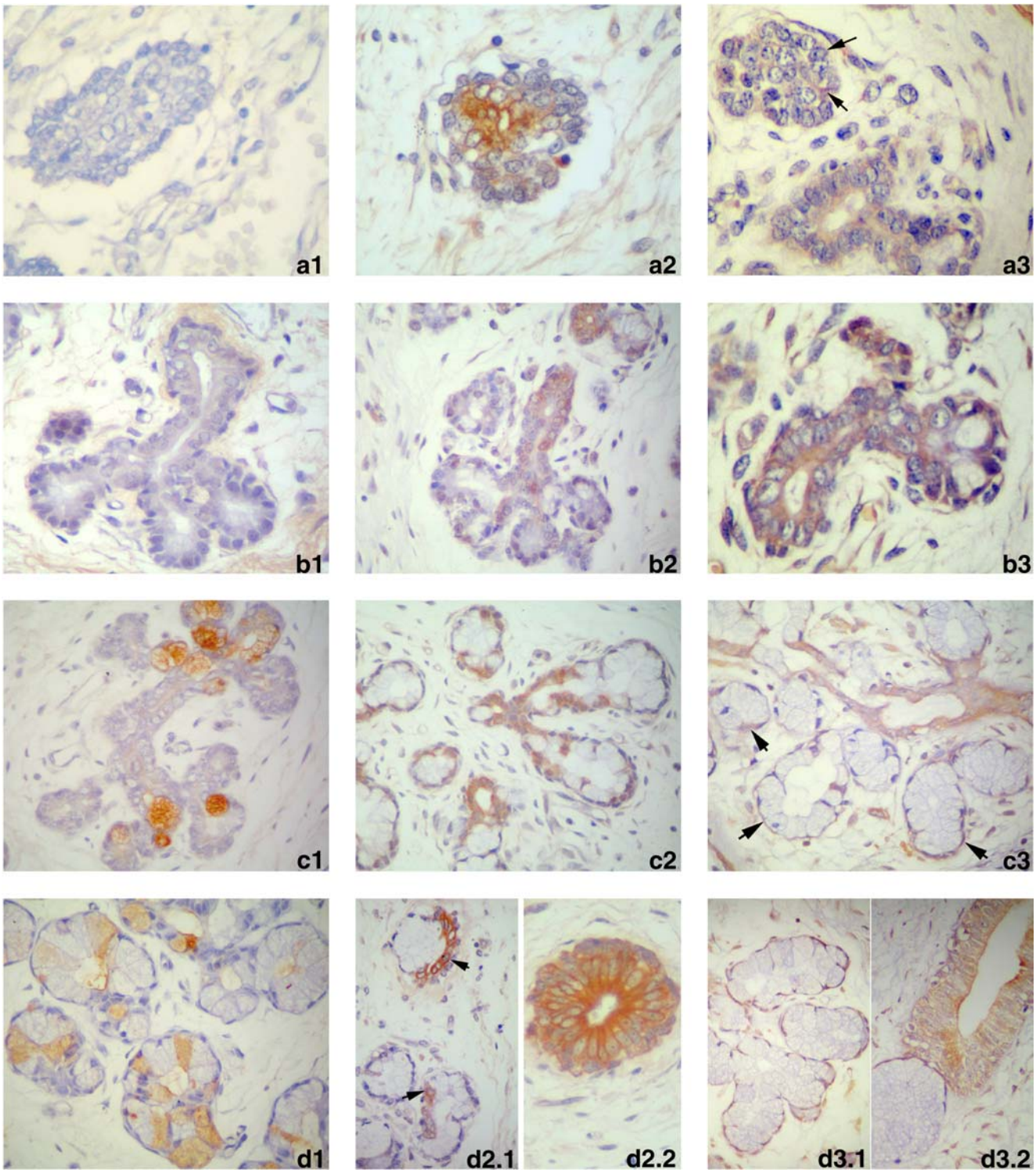

mounting the slides with glass coverslip and xylene-based mountant completed the procedure.

Negative controls were achieved by substituting primary specific antibodies with non-immune serum and internal positive controls were considered according to primary serum manufacturer's datasheet recommendation.

All immunohistochemical reactions were carried out in triplicate.

Immunofluorescence

The 3-μm serial sections of developing minor salivary glands specimens were submitted to double labelling immunofluorescence reactions, performed in two steps: sections were incubated with the first primary antibody, followed by incubation with goat anti-mouse IgG labelled with green fluorescent Alexa 488 (Molecular Probes, Carlsbad, CA, USA) at a concentration of 1:100 in BSA–PBS. Incubation with the second primary antibody was performed, followed by incubation with goat anti-mouse IgG labelled with red fluorescent Alexa 594 (Molecular Probes) at a concentration of 1:100. Primary antibodies used, source, clone and working dilutions are described in Table 1. The sections were then air dried and mounted with Vecta Shield.

The results were analysed under Zeiss microscope equipped with epi-illumination and filters for fluorescein and rodamin and registered with a digital camera.

Specimens incubated with normal serum were used as negative controls. Internal positive controls such as basal layer of epithelium and blood vessels were present.

Results

Immunohistochemistry and immunofluorescence

The specimens studied were of the minor human salivary glands in various stages of development, which were bud, proliferation, canalisation, branching and cytodifferentiation. Salivary glands at bud/proliferation stages of development were negative for TGF-beta 1 (Fig. 1**a1**). In these stages, a few TGF-beta 2 positive cells could be detected (Fig. 1**a2**), and weak expression of TGF-beta 3 was observed around cells of the solid bud (Fig. 1**a3,** arrow). At bud/proliferation stage of salivary gland development, only a few cells were weakly positive for CK14 (Fig. 2**a**).

During canalisation stage, developing salivary gland ducts could be observed. TGF-beta 1 was detected in the stroma surrounding the canalising glandular structures (Fig. 1**b1**). Cells of the rudimentary canalised glandular structures were strongly positive for TGF-beta 2 (Fig. 1**b2**), and TGF-beta 3 was seen with a weak intensity in the apical pole of cells in contact with the lumen (Fig. 1**b3**). During this development stage, CK14 and low-molecular-weight cytokeratin (CK LMW) were present in the ductal epithelial cells. Smooth-muscle actin (SMA) (red) was only found in rare cells (Fig. 2**b**, **c**, **g**, **h**).

In the stage of branching and initial cytodifferentiation, TGF-beta 1 was strongly expressed in the cytoplasm of rudimentary mucous cells at the end of the branching glandular structure (Fig. 1**c1**). Ductal cells were intensely positive for TGF-beta 2 (Fig. 1**c2**), and TGF-beta 3 was weakly expressed in the apical pole of the luminal cells of the developing salivary glands. TGF-beta 3 was also positive around the rudimentary acinic lobules in the myoepithelial cells (Fig. 1**c3**, arrows). In the stage of branching and initial cytodifferentiation, ductal cells were positive for CK 14 (Fig. 2**d**). Luminal cells of the developing ductal system were positive for CK LMW. SMA (red) was detected in cells of the terminal portion of the ductal system and in cells that surrounded the rudimentary acinic lobules (Fig. 2**i**, **j**).

In a further differentiation stage (advanced cytodifferentiation), TGF-beta 1 was positive in the cytoplasm of a few acinar cells of the well-established acinic lobules (Fig. 1**d1**). TGF-beta 2 showed a strong expression in the cytoplasm of ductal cells of the entire glandular system (Fig. 1**d2.1**, arrow, and **d2.2**) and TGF-beta 3 was present in the myoepithelial cells surrounding the acinar lobules (Fig. 1**d3.1**). Yet, a weak expression of this factor was observed in ductal cells of well-developed excretory ducts (Fig. 1**d3.2**). In late acinar cytodifferentiation, CK14 was detected in the cytoplasm of basal cells of the ductal system. Myoepithelial cells were positive for CK14 (green)

Fig. 2 Markers of cytoskeletal differentiation in human developing minor salivary gland. **a** Bud stage of salivary gland development: weak expression of CK14 in a few cells of the epithelial islet of the developing gland. **b**, **c** Proliferation/canalisation phase: expression of CK14 in the cytoplasm of ductal cells. **d** Branching phase: presence of CK 14 in a greater number of cells of the ductal system of the developing gland. **e** Acinar differentiation: immunoexpression of CK14 in myoepithelial cells surrounding the acinar lobules. **f** Strong expression of CK14 in the basal layer of the epithelium and in the well-formed ductal system of the salivary gland. Note that the ductal portion of the duct next to the covering epithelium is still negative for this marker. **g** Initial phase of proliferation/canalisation: a few structures presenting positivity for CK LMW (*green*). SMA (*red*) is only detected in blood vessels walls in this phase. **h**, **i** Canalisation/branching phase: strong expression of CK LMW (*green*) in the cells of the ductal system. Initial expression of SMA (*red*) in myoepithelial cells surrounding mainly the terminal portion of the ductal system. **j** Initial phase of acinar differentiation: expression of CK LMW (*green*) in the ductal system and SMA (*red*) surrounding the acinic structures. **k** Well-formed acinar lobules: strong expression of SMA (*red*) around the acinar structures. A few cells are positive for CK LMW (*green*), probably representing the intercalated duct structure. **l** Well-developed ductal system strongly positive for CK LMW (*green*)

and SMA (red). CK LMW was seen in luminal cells of the ductal system (Fig. 2**e**, **f**, **k**, **l**).

The specimens of normal fully developed salivary glands studied comprised minor glands composed of mucous secretory units, myoepithelial cells and intercalated, striated and excretory ducts. TGF-beta 1 was intensely expressed on the cytoplasm of mucous acinar cells, and TGF-beta 2 and 3 were detected on epithelial cells of the ductal system (Fig. 3**a**, **b**, **c**).

Semi-quantitative analysis of TGF-beta isoforms expression in developing and adult salivary glands was performed and classified according to the intensity of the immunohistochemical stain as negative (0), weak (+), mild (++) and strong (+++). These results are illustrated in Table 2.

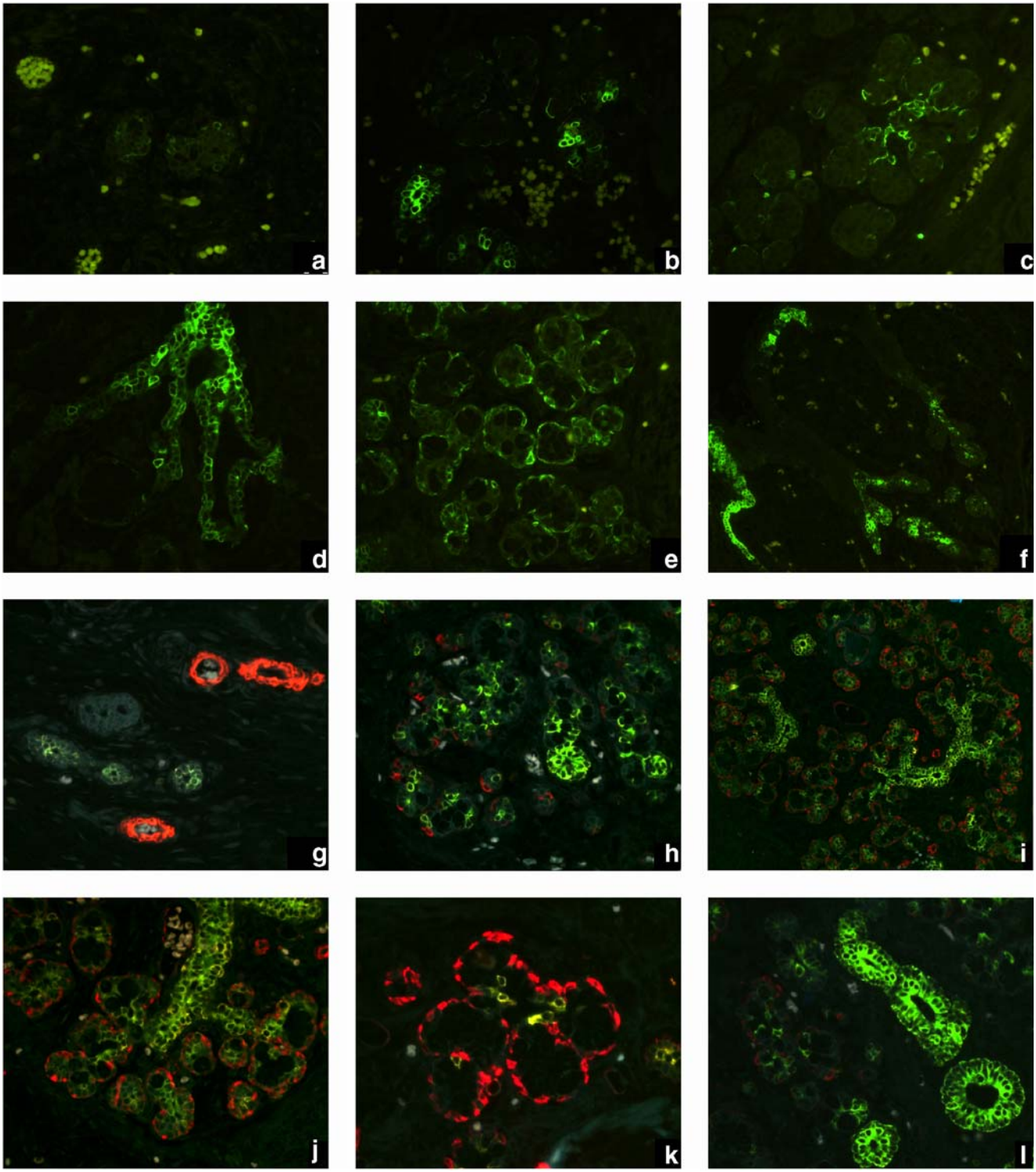

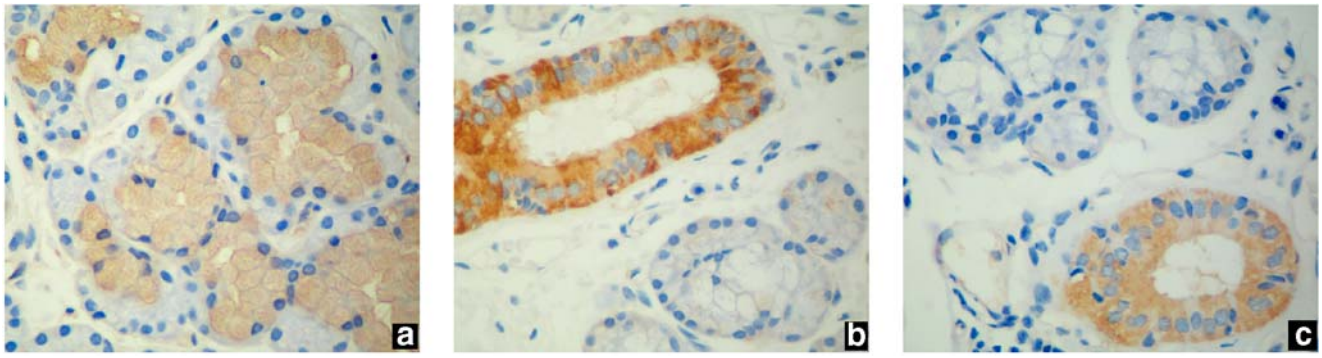

Fig. 3 TGF-beta expression in human normal adult minor salivary gland. **a** Expression of TGF-beta 1 in the cytoplasm of numerous acinar mucous cells (streptavidin–biotin peroxidase, original magnification ×400). **b** Strong expression of TGF-beta 2 in the cytoplasm of excretory ducts (streptavidin–biotin peroxidase, original magnification ×400). **c** Expression of TGF-beta 3 in the cytoplasm of excretory ducts (streptavidin–biotin peroxidase, original magnification ×400)

Discussion

The molecular mechanisms involved in salivary gland development have been described in some detail in the mouse and hamster [8, 16, 24]. To date, there is little known of the expression of growth factors during pre-natal and post-natal development of human salivary gland. Just as other glands and tissues, it is very likely that development is coordinated via several integrated events affecting proliferation, morphogenesis and cell-substratum interactions. These events are tightly regulated both temporally and spatially [4].

Our results revealed that TGF-beta 1, 2 and 3 are present in complementary patterns in the various phases of salivary gland development, branching, morphogenesis and cytodifferentiation. This pattern is dynamic and changes with the stage of development, and this tendency is also reported in the development of mammary glands and other glandular organs [1, 7, 15, 19, 25, 27, 29]. Moreover, the overlapping patterns of TGF-beta expression in morphogenetically active epithelial structures are reported in structures of murine head and neck, such as whisker follicle, salivary gland and tooth bud [25]. The TGF-beta superfamily is involved in many aspects of development and includes TGF-betas, BMPs, activins, inhibins and others [3]. Specifically, TGF-betas, activin and BMPs are reported to control salivary gland branching morphogenesis in studies that investigated these factors in mouse submandibular glands [13, 27].

During the initial stages of salivary gland morphogenesis, the bud stage, TGF-beta 1 was not present and TGF-beta 2 and 3 were detected in rare cells. This stage represents a highly proliferative phase, with little or no evidence of differentiation markers. Taking this into

Table 2 Semi-quantitative analysis of immunohistochemical expression of TGF-beta isoforms in developing and adult human minor salivary glands

		TGF-beta 1	TGF-beta 2	TGF-beta 3
Developing human minor salivary gland				
Bud stage	Epithelial cells	0	++	+
	Stroma	0	0	0
Canalisation stage	Ductal cells (epithelial)	0	+++	+
	Stroma	++	0	0
Branching stage	Ductal cells (epithelial)	0	+++	+
	Rudimentary acinar cells	+++	0	0
	Myoepithelial cells	0	0	++
	Stroma	0	0	0
Cyto-differentiation stage	Ductal cells (epithelial)	0	+++	++
	Acinar cells	+++	0	0
	Myoepithelial cells	0	0	++
	Stroma	0	0	0
Adult human minor salivary gland	Acinar cells	+++	0	0
	Ductal cells (epithelial)	0	+++	++
	Myoepithelial cells	0	0	0

Intensity of immunohistochemical stain: negative (0), weak (+), mild (++) and strong (+++)

consideration, it is predictable that TGF-beta expression is not a feature, as it has been previously reported that the factor inhibits proliferation and is more related to salivary gland differentiation and morphogenesis [6, 11, 14, 23]. Expression of cytokeratins is also not detected in this stage, in which cell proliferation is the main event. At this stage, none of the differentiation markers were present in the developing salivary glands, indicating that the glandular tissue is very immature and is establishing new connections with the extracellular matrix to prepare for a later stage of differentiation when phenotypic markers will be then detected. This result is in accordance with a previous report by Martins et al., in 2002 [21], who did not find any markers of differentiation in the very early stage of salivary gland development.

As salivary glands develop with increased tissue differentiation (canalisation/branching stage), TGF-beta 1 is detected in the mesenchyme surrounding the canalising and branching epithelial cords. This pattern of TGF-beta 1 expression imitates the one reported by Robinson et al., in 1991 [29], in branching morphogenesis of murine breast, and it is also reported in lung development [12]. This distribution of TGF-beta 1 during canalisation/branching phase may reflect an autocrine function of the growth factor, which would stimulate growth of the end-bud parenchymal cells. TGF-beta 2 and 3 are expressed in the epithelial cells of the initial ductal system. These results are only partially coincident with those published by Jaskoll and Melnick in 1999 [15], who reported the presence of TGF-1 and 2 in the branching epithelia and TGF-beta 3 in an epithelial and mesenchymal distribution. In this phase, the glandular system continues to display substantial epithelial cell proliferation, mainly at the tips of the canalising ductal system, where TGF-beta subunits are not yet detected. However, it is also characterised by the formation of ductal lumena and a significant change in the expression of cytoskeletal differentiation markers. At this stage (canalisation), positivity for CK14 and 35βH11 are observed, being indicative that cytodifferentiation progressed.

In advanced canalisation/branching stage and early cytodifferentiation of the salivary gland, the phenotype of the cells that compose the main structure of the developing gland is being well defined by the expression of CK14, CK LMW and SMA. TGF-beta 1 showed strong expression in the cytoplasm of immature mucous cells at the terminal end of the branched ductal system. TGF-beta 2 and 3 were distributed along all the luminal cells of the ductal system, including the intercalated ducts. TGF-beta 3 was also observed in the myoepithelial cells surrounding the immature mucous cells at the tip of the ductal system. This result agrees with the data reported by Robinson et al., 1991 [29], which described the expression of TGF-beta 3 in myoepithelial cells of the developing breast. This expression can also be compared with the expression of TGF-beta 3 in other organs composed of cells that present contractile components, such as skeletal and cardiac muscle and cells associated with blood vessels [25, 29]. Myoepithelial cells of salivary glands form the outermost layer of acinic lobules and ducts and act as both contractile cells to aid saliva secretion and cells with high capacity of synthesising basal lamina that ensheaths these structures [5]. Robinson et al., in 1991 [29], described the expression of TGF-beta 3 in myoepithelial stem cells, speculating on a possible function of inhibition of terminal differentiation, which would allow the formation of lateral buds in the developing breast. They also suggested that TGF-beta 3 could be involved in the elaboration of basal lamina components. These aspects could not be assessed in our study and remain to be elucidated in the formation of human salivary glands.

In late stages of salivary gland histogenesis, branching and cytodifferentiation of acinar cells, CK14, 35βH11 and SMA are present in this phase of gland development in a specific pattern. SMA is expressed when acinar lobules start to differentiate, stressing the presence of myoepithelial cells around these structures. CK14 is expressed by the basal cells of the excretory ducts and 35βH11 is found in the luminal cells of the ductal system. CK 14, according to other authors, will provide a strong base for the connection of basal cells with the basement membrane, functioning as integrators of the cytoplasm and allowing resistance to mechanical stress and maintenance of the ductal system architecture [9]. In this phase, TGF-beta 1 is seen in sparse, well-developed mucous acinar cells, and in adult salivary glands, the acinar cells conserved the expression of this growth factor. This pattern may be indicative that TGF-beta 1 is synthesised by acinar cells and is important for salivary gland maintenance. However, expression of TGF-beta 1 in adult normal salivary glands is disputable, and while Kizu et al. [17] reported its expression on acini and ducts, Kusafuka et al., in 2001 [18], found no evidences of its presence. TGF-beta 2 is exclusively detected along the epithelial cells of the ductal system, and TGF-beta 3 conserved its expression along the ductal system and in the myoepithelial cells that surround the mucous acinar lobules and these patterns and maintained in the adult structures.

The shifting prototype of TGF-beta subunits during maturation of salivary glands suggests changing stimuli requirements during the complex developmental stages of these glands. The present study adds strength to this evidence, showing that TGF-beta subunits are important factors during salivary gland differentiation, being developmentally regulated.

Acknowledgements Supported by *Fundacao de Amparo a Pesquisa do Estado de Sao Paulo* grants 02/02676-7 and 03/00450-4 and British Council Academic Link SPA/881/155.

References

1. Bartram U, Speer CP (2004) The role of transforming growth factor-beta in lung development and disease. Chest 125:754–765
2. Chai Y, Mah A, Crohin C, Groff S, Bringas P Jr, Le T, Santos V, Slavkin HC (1994) Specific transforming growth factor beta subtypes regulate embryonic mouse Meckel's cartilage and tooth development. Dev Biol 162:85–103
3. Chang H, Lau AL, Matzuk MM (2001) Studying TGF-beta superfamily signalling by knockouts and kcnokins. Mol Cell Endocrinol 180:39–46
4. Cutler LS (1989) Functional differentiation of salivary glands. In: Forte J (ed) Handbook of physiology, salivary, pancreatic, gastric and hepatobiliary secretion, vol 3. American Physiological Society Press, New York, pp 93–105
5. Cutler LS (1990) The role of extracellular matrix in the morphogenesis and differentiation of salivary glands. Adv Dent Res 4:27–33
6. Derynck R (1994) TGF-beta-receptor mediated signalling. Trends Biochem Sci 19:548–553
7. Faure E, Heisterkamp N, Groffen J, Kaartinen V (2000) Differential expression of TGF-beta isoforms during postlactational mammary gland involution. Cell Tissue Res 300:89–95
8. Fernandes RP, Cotanche DA, Lennon-Hopkins K, Erkan F, Menko AS, Kukuruzinska MA (1999) Differential expression of proliferative, cytoskeletal, and adhesive proteins during postnatal development of the hamster submandibular gland. Histochem Cell Biol 111(2):153–162
9. Fuchs E, Cleveland DW (1998) A structural scaffolding of intermediate filaments in health and disease. Science 279 (5350):514–519
10. Grande JP (1997) Role of transforming growth factor-beta in tissue injury and repair. Proc Soc Exp Biol Med 214:27–40
11. Hardman P, Landels E, Woolf AS, Spooner BS (1994) TGF-beta 1 inhibits growth and branching morphogenesis in embryonic mouse submandibular and sublingual glands in vivo. Dev Growth Differ 36:567–577
12. Heine UI, Muñoz EF, Flanders KC, Roberts A, Sporn MB (1990) Colocalization of TGF-beta 1 and collagen I and III, fibronectin and glycosaminoglycans during lung branching morphogenesis. Development 109:29–36
13. Heine U, Muñoz EF, Flanders KC, Ellingsworth LR, Lam HY, Thompson NL, Roberts AB, Sporn MB (1987) Role of transforming growth factor-beta in the development of the mouse embryo. J Cell Biol 105:2861–1876
14. Hu PP, Datto MB, Wang XF (1998) Molecular mechanisms of transforming growth factor-beta signalling. Endocr Rev 19:349–363
15. Jaskoll T, Melnick M (1999) Submandibular gland morphogenesis: stage-specific expression of TGF-alpha/EGF, IGF, TGF-beta, TNF, and IL-6 signal transduction in normal embryonic mice and the phenotypic effects of TGF-beta 2, TGF-beta 3, an EGF-R null mutations. Anat Rec 256:252–268
16. Kashimata M, Gresik EW (1996) Contemporary approaches to the study of salivary gland morphogenesis. Eur J Morphol 34:143–147
17. Kizu Y, Sakurai S, Katagiri S, Shinozaki N, Ono M, Tsubota K, Saito I (1996) Immunohistochemical analysis of tumour growth factor-beta 1 in normal and inflamed salivary glands. J Clin Pathol 49:728–732
18. Kusafuka K, Yamaguchi A, Kayano T, Takemura T (2001) Immunohistochemical localization of members of the transforming growth factor –beta superfamily in normal human salivary glands and pleomorphic adenomas. J Oral Pathol Med 30:413–420
19. Liu J, Tseu I, Wang J, Tanswell K, Post M (1996) Transforming growth factor-beta 2, but not beta 1 and beta 3, is critical for early rat lung branching. Dev Dyn 217:343–360
20. Lourenço SV, Kapas S (2005) Integrin expression in developing salivary glands. Histochem Cell Biol 124:391–399
21. Martins MD, Araújo VC, Raitz R, Araújo NS (2002) Expression of cytoskeletal proteins in developing human minor salivary glands. Eur J Oral Sci 110:316–32120
22. Massagué J (1998) TGF beta signal transduction. Annu Rev Biochem 67:753–791
23. Melnick M, Cehn H, Buckley S, Warburton D, Jaskoll T (1998) Insulin-like growth factor II receptor, transforming growth factor-beta, and Cdk4 expression and the developmental epigenetics of mouse palate morphogenesis and dysmorphogenesis. Dev Dyn 211:11–25
24. Menko AS, Kreidberg JA, Ryan TT, Van Bockstaele E, Kukuruzinska MA (2001) Loss of a3ß1 integrin function results in an altered differentiation program in the mouse submandibular gland. Dev Dyn 220(4):337–349
25. Millan FA, Denhez F, Kondaiah P, Akhurst RJ (1991) Embryonic gene expression patterns of TGF-beta 1, beta 2 and beta 3 suggest different developmental functions in vivo. Development 11:131–144
26. Moustakas A, Pardali K, Gaal A, Heldin CH (2002) Mechanisms of TGFβ signaling in regulation of cell growth and differentiation. Immunol Lett 82:85–91
27. Patel VN, Rebustini IT, Hoffman MP (2006) Salivary gland branching morphogenesis. Differentiation 74:349–364
28. Roberts AB, Sporn MB (1993) Physiological actions and clinical applications of transforming growth factor beta. Growth Fact 8:1–9
29. Robinson SD, Silberstein GB, Roberts AB, Flanders KC, Daniel CW (1991) Regulated expression and growth inhibitory effects of transforming growth factor-beta isoforms in mouse mammary gland development. Development 113:867–878