ANEXO-23

Interstitial pneumonitis in human visceral leishmaniasis

Duarte, M.I.S.; da Matta, V.L.R.; Corbett, C.E.P.; **Laurenti, M.D.;** Chebabo, R.; Goto, H.

Transactions of the Royal Tropical Medicine and Hygiene 1989; 83(1): 73-76

Interstitial pneumonitis in human visceral leishmaniasis

M. I. S. Duarte, V. L. R. da Matta, C. E. P. Corbett, M. D. Laurenti, R. Chebabo and H. Goto *Laboratório de Patologia de Moléstias Infecciosas, Pathology Department, University of São Paulo Medical School, São Paulo, Brazil*

Abstract

The involvement of the lung in 13 cases of human visceral leishmaniasis was studied. Interstitial pneumonitis with mononuclear cells was found in 76·8% of the cases; 53·8% also had foci of septal fibrosis. *Leishmania* were seen within macrophages in 3 cases only. However, all 10 interstitial pneumonitis cases showed PAP-positive material using specific *L. donovani* (MHOM/BR/72/LD 46) antiserum. 3 cases with no interstitial pneumonitis were PAP-negative. A short discussion about clinical aspects and the course of the disease is presented.

Introduction

There are many reports of coughing as a symptom of visceral leishmaniasis (CHAGAS & CHAGAS, 1938; LIPSCOMB & GIBSON, 1944; ALENCAR & ARAGÃO, 1955; SILVA, 1957; KAGER & REES, 1983; REES *et al.*, 1983; KAGER *et al.*, 1983; MARSDEN & JONES, 1985). However, there are few references to the incidence of histopathological involvement of the lung or the intensity and extent of the lesions. The data which are available are limited to a description of parasites in tissues or the association bronchopneumonia (LOMBARDO, 1913; CHAGAS *et al.*, 1947).

Interstitial pneumonitis found *post mortem* in visceral leishmaniasis patients was first described by ANDRADE (1958) in 3 of 5 cases, and he considered it to be peculiar to the disease. Later, RASO & SIQUEIRA (1964) found the same lesions in another patient with visceral leishmaniasis. DANESHBOD (1972) described a discrete septal mononuclear cell infiltrate in 4 out of 5 cases submitted to necropsy. In our experimental model, hamsters infected with *Leishmania donovani* (MHOM/BR/72/LD 46), we noticed the development of interstitial pneumonitis in 3 phases: exudative, cellular and fibrotic (DUARTE & CORBETT, 1984). It is remarkable, however, that leishmania amastigotes are rarely found in the lung in man, in experimental animals, or even in naturally infected dogs (DUARTE *et al.*, 1986a, 1986b).

This study was made to investigate the histopathological lesions in the lung of patients with visceral leishmaniasis submitted to necropsy, to determine its incidence, and to demonstrate antigenic material in lung in order to confirm the relationship between parasite antigen and interstitial pneumonitis.

Material and Methods

Lung fragments were obtained at necropsy from 13 patients with visceral leishmaniasis, treated or untreated, at the Clinical Hospital of the University of São Paulo Medical School. The diagnosis of the disease was made by finding amastigotes of *Leishmania* in bone marrow aspirate and in histological sections of liver and spleen. Sections were stained with haematoxylin and eosin and by the Giemsa, Manson trichromic and picro-sirius (JUNQUEIRA *et al.*, 1979) methods.

All fragments were submitted to the immunoenzymatic peroxidase-antiperoxidase (PAP) method for the detection of parasite antigens. The formalin fixed, paraffin embedded tissue specimens were deparaffinized with xylol, rehydrated through decreasing alcohol concentrations and then processed for the PAP reaction. Sections (3 μm) were incubated in 10% NH_4OH for 10 min to eliminate formalin pigment and then treated with 3% H_2O_2 in methanol to block endogenous peroxidase activity. The sections were then incubated with normal swine serum for 20 min to reduce non-specific reactions followed by rabbit anti-*L. donovani* serum (1/320) for 60 min at 37°C, after which they were washed in phosphate-buffered saline (PBS, 0·01M, pH 7·2). The sections were then incubated with secondary antibody (swine anti-rabbit serum; Dakopatts, Denmark) for 30 min at 37°C, washed again and incubated with rabbit PAP complex (Dakopatts) for 30 min at 37°C. The reaction product was visualized with diaminobenzidine (DAB)-H_2O_2 solution and the sections were counter stained with Mayer's haematoxylin and mounted in resin.

Specific antiserum was obtained using *L. donovani* (MHOM/BR/72/LD 46) promastigotes from cultures in NNN medium plus brain-heart infusion, washed 3 times in PBS (0·01M, pH 7·2) at 4000 rpm, resuspended in PBS and ethylenediaminetetraacetic acid, frozen and thawed 10 times. Rabbits were given 10 weekly inoculations in the foot pad with this antigen (1 mg/ml of protein) plus incomplete Freund's adjuvant. The antiserum was stored in 1 ml aliquots in glycerin (1:1) at −20°C and used as primary antibody in the PAP reaction.

The negative controls were normal human lung, human lung from patients with toxoplasmosis or viral pneumonitis, obtained at autopsy, or preparations of lung from visceral leishmaniasis patients in which the primary antibody was replaced by anti-*Leishmania* serum absorbed with a pellet of promastigotes from culture (SELLS & BURTON, 1981). The positive control was liver from experimentally infected hamsters.

Results

Histopathology

Ten cases (76·9%) had pulmonary interstitial involvement with interalveolar septal thickening due to

Address for correspondence: M. I. S. Duarte, Laboratório de Patologia de Moléstias Infecciosas, Pathology Department, University of São Paulo Medical School, Av. Dr Arnaldo, 455, 1° andar, sala 26, 01246—São Paulo—SP, Brazil.

infiltration by macrophages, lymphocytes, plasma cells and interstitial cells with lipid inclusions (Fig. 1). The mononuclear cell infiltration did not show a preference for any specific area of the parenchyma, but was irregularly distributed and of varied intensity in different cases. In 7 cases (53·8%) together with septal thickening we also observed irregularly distributed foci of fine septal fibrosis, similar to the inflammatory cell infiltration (Fig. 2). We did not notice any change in the capillary endothelial cells, in pneumocytes I and II, or in bronchi. Amastigotes within macrophages were identified in 3 cases only. In 7 (70%) of the interstitial pneumonitis cases foci of bronchopneumonia were also found. Three cases with no septal thickening due to infiltration by inflammatory cells were considered as histologically normal.

Immunohistochemical study

All interstitial pneumonitis cases showed PAP-positive material in the septal thickening area. The PAP-positive material appeared as granular particulated material phagocytized by either septal or alveolar macrophages, or even free in the interstitium, in 8 cases (Fig. 3), or as well defined amastigotes within macrophages in 3 cases (Fig. 4).

In the 3 cases with no interstitial septum involvement the PAP reaction was negative.

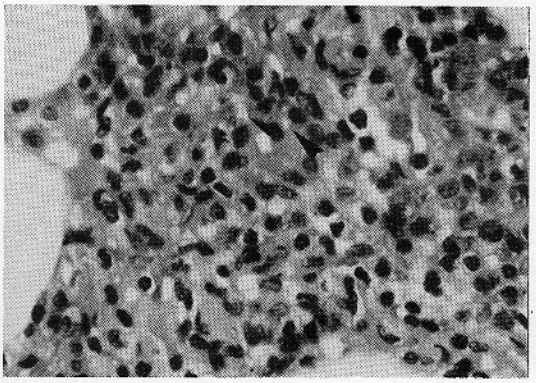

Fig. 1. Interstitial pneumonitis showing infiltration of mononuclear cells and interstitial cells with lipid inclusions (arrows) thickening the interalveolar septum (× 380).

Discussion

Previous reports on the histopathology of lung involvement in visceral leishmaniasis (LAVERAN, 1917; MELENEY, 1925; HU, 1936; RASO & SIQUEIRA, 1964; DANESHBOD, 1972) emphasized the scarcity of parasites in the lung, as we have seen in our material. This fact makes it difficult to confirm the relationship between the interstitial pulmonary changes and visceral leishmaniasis. The demonstration of antigenic material by the PAP method in the cytoplasm of macrophages or aparently free in the thickened septum indicated that this interstitial pneumonitis was really due to the disease. There was no antigenic material in the 3 cases with no septal lesion. This emphasized the importance of the presence and persistence of antigenic material in the development of interstitial pneumonitis.

In hamsters experimentally inoculated with *L.*

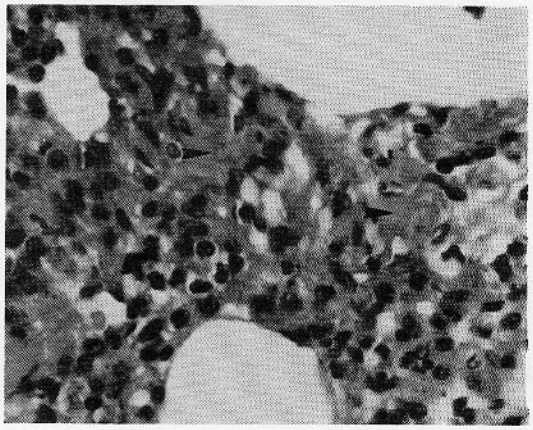

Fig. 2. Interstitial pneumonitis with foci of septal fibrosis (arrows) (× 380).

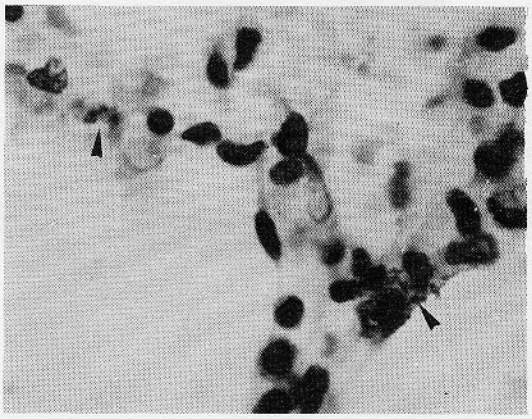

Fig. 3. Particulate PAP-positive material (arrows) in the thickened septum (× 950).

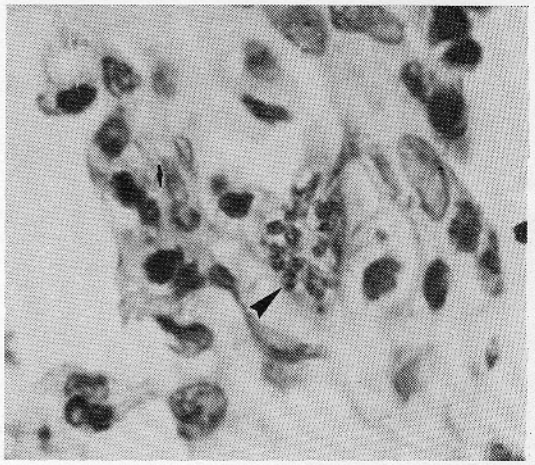

Fig. 4. PAP-positive amastigotes in the septum (× 950).

donovani we characterized the interstitial pneumonitis as developing in one of 3 phases: exudative (quick), cellular (similar to that found in man), and fibrotic (areas of fine septal fibrosis) (DUARTE & CORBETT, 1984). Interstitial pneumonitis was also seen in naturally infected dogs in an endemic region (DUARTE *et al.*, 1986a, 1986b).

Foci of septal fibrosis were detected in 53·8% of the cases. In those with interstitial pneumonitis, they were probably related to the visceral leishmaniasis. Nevertheless, it is impossible to exclude other previous diseases causing lung fibrosis in human material obtained at autopsy, but the identification of antigenic material confirmed the leishmanial aetiology of the lesion. These cases had no clinical or histopathological evidence of either viral or any other cause of interstitial pneumonitis.

Most of the authors of clinical reports (CHAGAS & CHAGAS, 1938; LIPSCOMB & GIBSON, 1944; ALENCAR & ARAGÃO, 1955; SILVA, 1957; KAGER & REES, 1983; REES, *et al.*, 1983; KAGER *et al.*, 1983; MARSDEN & JONES, 1985) described persistent dry coughing in visceral leishmaniasis patients appearing early and remaining unchanged during the disease and disappearing with cure. Clinical studies with patients from the region where our patients came from related coughing in 81·7% (ALENCAR & ARAGÃO, 1955) and 72·1% (SILVA, 1957). This cough is presumably the clinical sign of interstitial pneumonitis.

Patients with visceral leishmaniasis frequently present secondary infection (COLE, 1944; MOST & LAVIETES, 1947; FENDALL, 1952; MANSON-BAHR & HEISCH, 1956; ALENCAR & NEVES, 1982; KAGER *et al.*, 1983; BRYCESON, 1986) leading to a worsening prognosis and often death. We believe that interstitial pulmonary involvement would facilitate bacterial growth leading to bronchopneumonia.

Summarizing, we can say that in man there is a leishmanial interstitial pneumonitis in which amastigotes are rare or absent. The identification of antigenic material in the septum confirms the relationship between interstitial pneumonitis and visceral leishmaniasis. Moreover, the interstitial pneumonitis explains the persistent cough and could also be a predetermining factor in bacterial growth and secondary infection.

Acknowledgements

This work was supported by FINEP and Lab. Invest. Méd.—LIM/72. We thank Maria Lúcia G. B. Barits for technical assistance and Maria Daisi Morais for secretarial help.

References

Alencar, J. E. & Aragão, T. C. (1955). Leishmaniose visceral no Ceará. Sintomas observados em 174 casos. *XII Congresso Brasileiro de Higiene, Belém (Pará), Brasil.*

Alencar, J. E. & Neves, J. (1982). Leishmaniose visceral (calazar). In: *Doenças Infecciosas e Parasitárias*, Veronesi, R. (editor), 7th edition. Rio de Janeiro: Guanabara Koogan, p. 729.

Andrade, Z. A. (1958). A patologia da leishmaniose visceral (calazar). *Arquivo Brasileiro de Medicina Naval*, **19**, 79–204.

Bryceson, A. D. M. (1986). Visceral leishmaniasis. In: *Infectious Diseases and Medical Microbiology*, Braude, A. I., Davis, C. E. & Fierer, J. (editors), 2nd edition. Philadelphia, W. B. Saunders, p. 984.

Chagas, E. & Chagas, A. W. (1938). Notas sobre a epidemiologia da leishmaniose visceral Americana. *O Hospital*, **13**, 471–480.

Chagas, E., Cunha, A. M., Castro, G. O., Ferreira, L. C. & Romana, C. (1947). Leishmaniose visceral Americana. *Memórias do Instituto Oswaldo Cruz*, **32**, 321.

Cole, A. C. E. (1944). Kala-azar in East Africa. *Transactions of the Royal Society of Tropical Medicine and Hygiene*, **37**, 409–435.

Daneshbod, K. (1972). Visceral leishmaniasis (kala-azar) in Iran: a pathologic and electron microscopic study. *American Journal of Clinical Pathology*, **57**, 156–166.

Duarte, M. I. S. & Corbett, C. E. P. (1984). Histopathological and ultrastructural aspects of interstitial pneumonitis of experimental visceral leishmaniasis. *Transactions of the Royal Society of Tropical Medicine and Hygiene*, **78**, 683–688.

Duarte, M. I. S., Corbett, C. E. P., Laurenti, M. D., Nunes, V. L. B., Rego, F. A., Jr & Oshiro, E. T. (1986a). Canine interstitial pneumonitis in a new endemic area of visceral leishmaniasis in western Brazil. *Transactions of the Royal Society of Tropical Medicine and Hygiene*, **80**, 992–993.

Duarte, M. I. S., Laurenti, M. D., Brandão Nunes, V. L., Rego, F. A. Jr, Oshiro, E. T. & Corbett, C. E. P. (1986b). Interstitial pneumonitis in canine visceral leishmaniasis. *Revista do Instituto de Medicina tropical de São Paulo*, **28**, 431–436.

Fendall, N. R. E. (1952). Kala-azar in East Africa, with particular reference to Kenya and the Kamba Country. IV. Clinical studies. *Journal of Tropical Medicine and Hygiene*, **55**, 245–256.

Hu, C. H. (1936). The pathological anatomy of human kala-azar with special reference to certain hitherto less well recognized changes. *Chinese Medical Journal*, Supplement, 1.

Junqueira, L. C. V., Bignolas, G. & Brentani, R. R. (1979). Picro-sirius staining plus polarization microscopy, a specific method for collagen detection in tissue sections. *Histochemical Journal*, **11**, 447–455.

Kager, P. A. & Rees, P. H. (1983). Clinical aspects of visceral leishmaniasis in Kenya: review of the literature until 1978. In: *Clinical Aspects of Kala-azar in Kenya*, Kager, P. A. & Rees, P. H. (editors). Dordrecht, Netherlands: I.C.G. Printing, p. 10.

Kager, P. A., Rees, P. H., Manguyu, F. M., Bhatt, K. M., Hockmeyer, W. T., Wellde, B. T. & Lyerly, W. H. Jr (1983). Clinical presentation of visceral leishmaniasis in Kenya: a prospective study of 64 patients. In: *Clinical Aspects of Kala-azar in Kenya*, Kager, P. A. & Rees, P. H. (editors). Dordrecht, Netherlands: I.C.G. Printing, p. 40.

Laveran, C. L. A. (1917). Leishmaniose. In: *Leishmaniose (Kala-azar, Bouton d'Orient, Leishmaniose Americaine)*, Laveran, C. L. A. (editor). Paris: Masson, p. 515.

Lipscomb, F. E. & Gibson, M. D. J. (1944). Visceral leishmaniasis (kala-azar in adult contracted in Malta). *British Medical Journal*, **i**, 492–493.

Lombardo, G. (1913). Contributto allo studio delle alterazioni anatomicha dell'anemia da leishmania. *Pathologica*, **5**, 292.

Manson-Bahr, P. E. C. & Heisch, R. B. (1956). Studies in leishmaniasis in East Africa. III. Clinical features and treatment. *Transactions of the Royal Society of Tropical Medicine and Hygiene*, **50**, 465–471.

Marsden, P. D. & Jones, T. C. (1985). Clinical manifestations, diagnosis and treatment of leishmaniasis. In: *Leishmaniasis*, Chang, K. P. & Bray, R. S. (editors). Amsterdam: Elsevier Science Publishers, p. 186.

Meleney, H. E. (1925). The histopahology of kala-azar in the hamster, monkey and man. *American Journal of Pathology*, **1**, 147–167.

Most, H. & Lavietes, M. C. (1947). Kala-azar in American military personnel. *Medicine*, **26**, 221–284.

Raso, P. & Siqueira, J. T. (1964). Subsidio ao conhecimento da anatomia patológica da leishmaniose visceral, com

especial referência às lesões pulmonares e cardíacas. *O Hospital*, **65**, 145–163.
Rees, P. H., Kager, P. A. & Bwibo, N. O. (1983). Clinical aspects and treatment of visceral leishmaniasis in Kenya: a retrospective study of 71 patients. In: *Clinical Aspects of Kala-azar in Kenya*, Kager, P. A. & Rees, P. H. (editors). Dordrecht, Netherlands: I.C.G. Printing, p. 31.
Sells, P. G. & Burton, M. (1981). Identification of *Leishmania* amastigotes and their antigens in formalin fixed tissue by immunoperoxidase staining. *Transactions of the Royal Society of Tropical Medicine and Hygiene*, **75**, 461–468.
Silva, J. R. (1957). *Leishmaniose visceral (calazar)*. Thesis, University of Rio de Janeiro, pp. 139 & 206.

Received 14 April 1988; revised 15 July 1988; accepted for publication 10 August 1988

TRANSACTIONS OF THE ROYAL SOCIETY OF TROPICAL MEDICINE AND HYGIENE (1989) **83**, 76

Short Report

Successful *in vitro* isolation and cultivation of Italian dermotropic strains of *Leishmania infantum sensu lato*

M. Gramiccia and **L. Gradoni** *Istituto Superiore di Sanitá, Laboratorio di Parassitologia, Viale Regina Elena 299, 00161 Rome, Italy*

Isolating and culturing leishmanial parasites from Italian cases of human cutaneous leishmaniasis (CL) in conventional blood-agar and liquid media has proved difficult (GRAMICCIA *et al.*, 1986). Therefore, an *in vivo* method was used for the primary isolation of these parasites employing LHC inbred hamsters treated with cortisone (POZIO *et al.*, 1985). Promastigotes 'transiently grown' in Schneider's medium seeded with heavily infected spleen of LHC hamsters were subsequently used for the isoenzyme characterization of the stocks. Using this technique it was shown that the agent of CL in Italy is *Leishmania infantum* s.l., and not *L. tropica* (GRAMICCIA *et al.*, 1987, 1988).

Unfortunately, the LHC inbred hamster strain is no longer available, so we had to redirect our attention to an *in vitro* method for isolating *Leishmania*. An unconventional semi-solid blood-agar medium, 'sloppy Evans' (EVANS *et al.*, 1984; EVANS & SMITH, 1987) was tested. Parasite isolation has been attempted from 3 patients with CL acquired in Abruzzi (2) and Sicily (1). Biopsy material was homogenized in a solution containing EMTM liquid phase (EVANS, 1978), foetal calf serum (10%), gentamicin (250 μg/ml) and 5-fluorocytosine (250 μg/ml). The suspension was placed in 5 ml screw-cap plastic vials containing 'sloppy Evans' medium. Incubation temperature was 22°C. Cultures were examined from day 7. Viable promastigotes were seen from day 9 in 2 cultures and from day 30 in one. 18–30 d after inoculation, the cultures were sub-inoculated into both 'sloppy Evans' medium and EMTM, but promastigotes grew only in the former. However, parasites were gradually adapted to EMTM during subsequent passages, and satisfactory promastigote growth in this medium was obtained 2–5 months after primary isolation. Since then it has been possible to prepare mass cultures for isoenzyme characterization of the stocks. Starch gel electrophoresis was carried out on 12 enzymes (PGM, GPI, ASAT, G6PD, 6PGD, ME, MDH, NH_1, NH_2, HK, FH, IDH) using the following reference strains: MHOM/TN/80/IPT1 for *L. infantum* zymodeme Montpellier 1 (=ZLON49), MHOM/DZ/82/LIPA59 for *L. infantum* ZMON24 (dermotropic) and MHOM/SU/74/K27 for *L. tropica* ZMON6(=ZLON12). All 3 stocks (MHOM/IT/87/ISS320, MHOM/IT/87/ISS346 and MHOM/IT/88/ISS388) were indistinguishable from *L. infantum* ZMON24. This zymodeme is responsible for about 70% of CL cases in Italy (GRAMICCIA *et al.*, 1988).

References

Evans, D. A. (1978). Kinetoplastida. In: *Methods of Cultivating Parasites* in vitro, Taylor, A. E. R. & Baker, J. R. (editors). London: Academic Press, pp. 55-88.
Evans, D. A. & Smith, V. (1987). Prolonged *in vitro* cultivation of *Leishmania mexicana venezuelensis*. *Transactions of the Royal Society of Tropical Medicine and Hygiene*, **80**, 493.
Evans, D. A., Lanham, S. M., Baldwin, C. I. & Peters, W. (1984). The isolation and isoenzyme characterization of *Leishmania braziliensis* subsp. from patients with cutaneous leishmaniasis acquired in Belize. *Transactions of the Royal Society of Tropical Medicine and Hygiene*, **78**, 35-42.
Gramiccia, M., Gradoni, L. & Pozio, E. (1986). Caractérisation biochimique de souches du complex *Leishmania infantum* isolées en Italie. In: Leishmania. *Taxonomie et Phylogenèse. Applications Éco-épidémiologiques (Coll. Int. CNRS/INSERM, 1984)*. Montpellier: I.M.E.E.E., pp. 445-454.
Gramiccia, M., Gradoni, L. & Pozio, E. (1987). *Leishmania infantum sensu lato* as an agent of cutaneous leishmaniasis in Abruzzi region (Italy). *Transactions of the Royal Society of Tropical Medicine and Hygiene*, **81**, 235-237.
Gramiccia, M., Gradoni, L. & Angelici, M. C. (1988). Epidemiology of Mediterranean leishmaniasis by *Leishmania infantum*: isoenzyme and kDNA analysis for the identification of parasites from man, vectors and reservoirs. In: *NATO-ASI Monograph on Leishmaniasis*, Hart, D. J. (editor). New York: Plenum Press (in press).
Pozio, E., Gramiccia, M., Gradoni, L. & Amerio, P. (1985). Isolation of the agent causing cutaneous leishmaniasis in Italy and its visceralization in inbred hamsters. *Transactions of the Royal Society of Tropical Medicine and Hygiene*, **79**, 260-261.

Received 18 May 1988; accepted for publication 5 July 1988

ANEXO-24

Canine interstitial pneumonitis in a new endemic area of visceral leishmaniasis in western Brazil

Duarte, M.I.S.; Corbett, C.E.P.; **Laurenti, M.D.;** Nunes, V.L.B.; Rego Jr, F.A.; Oshiro, E.T.

Transactions of the Royal Tropical Medicine and Hygiene 1986; 80: 992-993

the analysis is defensible, but I think that exclusion of cases with negative faecal examinations is not. Singer, Lumey and Vermund (submitted for publication) have recently re-analysed data from the asymptomatic Brazilian cases using the exploratory strategy of EMERSON & STOTO (1982) and STOTO & EMERSON (1983) to determine whether the data fitted a power function. They found a virtually linear relationship between worm pairs and the number of eggs in the faeces, i.e., they found no density-dependent trend.

I would add that technical inadequacies of perfusion in man or other animals will probably have a much greater effect on faecal or tissue eggs per worm pair in lightly infected individuals than in those heavily infected, and failing to find worm pairs will increase the apparent number of eggs per worm pair. Although all the objective criteria I could think of indicated nearly complete recovery of worms from human cadavers (CHEEVER, 1968) there have been only rare moments when I believed in my heart that I found every last worm in the several pounds of human tissues examined.

The rate of deposition of schistosome eggs in the tissues is commonly assumed to parallel the passage of eggs in the excreta. Although this generally appears to be the case, clear differences between faecal egg excretion and accumulation of eggs in the tissues were reported for rabbits infected with different strains of *S. japonicum* (CHEEVER *et al.*, 1980). Regression of tissue eggs per worm pair against worm pairs in the 38 Brazilian cases (CHEEVER, 1968) having values for tissue eggs per worm pairs gives the following results: In tissue eggs per worm pair = 3·5886-0·2474 In worm pairs ($r = -\cdot 39$, $p < \cdot 02$, natural logarithms) so that the number of tissue eggs per worm pair is calculated to decrease about 3-fold for each 10-fold increase in worm pairs. The number of eggs per worm pair found in the tissues is influenced by egg passage in the excreta and by rates of oviposition and egg destruction, so the correct interpretation of this trend is unclear. A similar regression using 58 Egyptian cases with *S. mansoni* worm pairs (CHEEVER *et al.*, 1977) did not give a significant slope ($r = -\cdot 20$, $p > \cdot 1$).

Density-dependent modulation of pathological changes in the host also needs to be considered. In *S. japonicum* infected mice, the more heavily infected animals have smaller circumoval granulomas and less hepatic fibrosis per egg or per worm pair than do lightly infected mice, but these trends are not consistent in other host species or in *S. mansoni* or *S. haematobium* infections in mice (CHEEVER, 1986).

The overall issue of density-dependent phenomena in the schistosome infected host is complex and little clarified by the present communication. I think, however, that it is evident that the basis of selection of data from the Brazilian cases by Medley and Anderson needs reconsideration.

ALLEN W. CHEEVER
National Institutes of Health
National Institute of Allergy and Infectious Diseases,
Bethesda, MD 20892, USA

References

Cheever, A. W. (1968). A quantitative post mortem study of schistosomiasis mansoni in man. *American Journal of Tropical Medicine and Hygiene*, **17**, 38-64.

Cheever, A. W. (1986). The intensity of experimental schistosome infections modulates hepatic pathology. *American Journal of Tropical Medicine and Hygiene*, **35** 124-133.

Cheever, A. W., Duvall, R. H. & Minker, R. G. (1980). Quantitative parasitologic findings in rabbits infected with Japanese and Philippine strains of *Schistosoma japonicum*. *American Journal of Tropical Medicine and Hygiene*, **29**, 1307-1315.

Cheever, A. W., Kamel, I. A., Elwi, A. M., Mosimann, J. E. & Danner, R. (1977). *Schistosoma mansoni* and *S. haematobium* infections in Egypt. II. Quantitative parasitological findings at necropsy. *American Journal of Tropical Medicine and Hygiene*, **26**, 702-716.

Emerson, J. D. & Stoto, M. A. (1982). Exploratory methods for choosing power transformations. *Journal of the American Statistical Association*, **77**, 102-108.

Medley, G. & Anderson, R. M. (1985). Density-dependent fecundity in *Schistosoma mansoni* infections in man. *Transactions of the Royal Society of Tropical Medicine and Hygiene*, **79**, 532-534.

Stoto, M. A. & Emerson, J. D. (1983). Power transformations for data analysis. In: *Sociological Methodology 1983-1984*. Leinhardt, S. (editor). San Francisco: Jossey-Bass, pp. 126-168.

Accepted for publication 21st December, 1985.

Canine interstitial pneumonitis in a new endemic area of visceral leishmaniasis in western Brazil

In western Brazil, Corumbá (MS), a new focus of human visceral leishmaniasis (1 Reunião Nacional sobre Pesquisa em Leishmaniose, 1984) has been detected together with a high incidence of the disease in domestic dogs. The domestic dog, in Brazil, has been considered as a possible important source of visceral leishmaniasis since 1937 (CHAGAS *et al.*, 1937), an hypothesis that was well discussed in 1955 by DEANE & DEANE. There are only a few references to canine histopathology especially related to lung involvement (GEORGE *et al.*, 1976; TRYPHONAS *et al.*, 1977; ANDERSON *et al.*, 1980). Interstitial pneumonitis has already been described in experimental animals (hamster) and is characterized by three evolutive phases: exudative, cellular and fibrotic (DUARTE & CORBETT, 1984).

Studying the lung of 37 naturally infected dogs from Corumbá (MS) we found interstitial pneumonitis in 30.

The main lesion was a septal thickening due to mononuclear cell infiltrate (lymphocytes, plasma cells, macrophages and vacuolated cells containing fat) sometimes together with fibrosis. The intensity and distribution of these changes varied from area to area with no preference for any specific region. The relationship between cellular and fibrotic elements varied from case to case ranging from a more cellular involvement to septal fibrosis. The changes found in dogs were similar to the experimental interstitial pneumonitis described in hamsters (DUARTE & CORBETT, 1984) but only the cellular and fibrotic types were seen in dogs. Leishmaniae were rarely found in pulmonary tissue but easily found in liver, spleen, lymph nodes and skin. No other pulmonary change such as bronchopneumonia or any other alveolar lumen pathology was seen. No other pathological

cause affecting the dogs' pulmonary interstitium was recognized that could account for fibrosis; four dogs from the same place, with no clinical signs of visceral leishmaniasis, showed no changes in the lung or in any other organs. We believe that visceral leishmaniasis is responsible for an interstitial pathology, also seen in other organs such as liver and kidneys, which could evolve to fibrosis. Pneumonitis found in naturally infected dogs seems to be similar to the one found in experimentally infected hamsters (DUARTE & CORBETT, 1984) and in man (ANDRADE, 1959; RASO & SIQUEIRA, 1964; Duarte *et al.*, unpublished data).

Fibrosis represents a chronic response to the disease and the interstitium is the main structure where the changes occur. Interstitial pneumonitis is demonstrative of the visceral leishmaniasis pathology in naturally infected dogs and it can be reproduced in experimental animals which show similar changes.

This work was supported by FINEP: 43/83/0006.

M. I. S. DUARTE[1]
C. E. P. CORBETT[1]
M. D. LAURENTI[1]
V. L. B. NUNES[2]
F. A. REGO, Jr.[3]
E. T. OSHIRO[2]

[1]*Dept. of Pathology, University of São Paulo Medical School, S. Paulo, Brazil.*
[2]*Dept. of Pathology, Federal University of Mato Grosso do Sul, Brazil.*
[3]*IAGRO, Corumbá, MS, Brazil.*

References

Anderson, D. C., Buckner, R. G., Glen, B. L. & MacVean, D. W. (1980). Endemic canine leishmaniasis. *Veterinary Pathology*, **17**, 94-96.

Andrade, Z. A. (1959). Pneumonite intersticial no calazar. *O Hospital*, **55**, 71.

Chagas, E., Cunha, A. M., Castro, G. O., Ferreira, L. C. & Romana, C. (1937). Leishmaniose visceral americana. Relatório dos trabalhos realizados pela comissão encarregada de estudos de leishmaniose visceral americana em 1936. *Memórias do Instituto Oswaldo Cruz*, **32**, 321-385.

Deane, L. M. & Deane, M. P. (1955). Observações preliminares sobre a importância comparativa do homem, do cão e da raposa (*Lycalopex vetulus*) como reservatórios da *Leishmania donovani*, am área endêmica de calazar, no Ceará. *O Hospital*, **48**, 61-76.

Duarte, M. I. S. & Corbett, C. E. P. (1984). Histopathological and ultrastructural aspects of interstitial pneumonitis of experimental visceral leishmaniasis. *Transactions of the Royal Society of Tropical Medicine and Hygiene*, **78**, 683-688.

George, J. W., Nielsen, S. W., Shively, J. N., Hopek, S. & Mroz, S. (1976). Canine leishmaniasis with amyloidosis. *Veterinary Pathology*, **13**, 365-373.

Raso, P. & Siqueira, J. T. (1964). Subsídio ao conhecimento da anatomia patológica da leishmaniose visceral, com especial referência as lesões pulmonares e cardíacas. *O Hospital*, **65**, 144-163.

1 Reunião Nacional sobre Pesquisa em Leishmaniose (1984). Faculdade de Medicina da Universidade de São Paulo, Departmento de Patologia, São Paulo, Brazil.

Tryphonas, L., Zawdska, Z., Bernard, M. A. & Janzen, E. A. (1977). Visceral leishmaniasis in a dog: clinical hematological and pathological observations. *Canadian Journal of Comparative Medicine*, **41**, 1-12.

Accepted for publication 7th January, 1986.

Serodiagnosis of ocular toxocariasis: a comparison of specific IgE and IgG

Human toxocariasis is caused by accidental ingestion of infective eggs of *Toxocara canis*, the common roundworm of the dog. Two distinct clinical syndromes are observed: *visceral larva migrans* (VLM) and *ocular larva migrans* (OLM).

Specific serological tests are an important complement for diagnosis, which is often complicated by polymorphic clinical pictures of the syndromes. At present the enzyme-linked immunosorbent assay (ELISA) with secretory-excretory antigen, or exoantigen (TEX), is considered to be the most sensitive and specific for detection of IgG in the sera of patients with VLM (GLICKMAN *et al.*, 1985). Patients with OLM are instead reported to have specific serum IgG titres that are significantly lower than those of patients with VLM (GLICKMAN & SCHANTZ, 1981). Recently GLICKMAN *et al.* (1985) have emphasized that TEX-ELISA results in better discrimination between positive and negative sera than ELISA with embryonated egg antigen, but the problem of diagnosis from sera with low IgG antibodies is not completely solved.

In 1982 we used the radio-allergosorbent-test (RAST) to detect specific IgE in sera of patients with VLM syndrome; a blind comparison was performed with TEX-ELISA (BRUNELLO *et al.*, 1982). The results showed good qualitative agreement in the two classes of immunoglobulins IgE and IgG. IgE was detectable in sera of patients with OLM syndrome also (GENCHI *et al.*, 1983).

A batch of 12 sera from patients with clinical diagnosis of OLM was then tested with TEX-ELISA for larva specific IgG and with TEX-RAST for larva specific IgE. IgG and IgE were also determined in the vitreous humor of three patients (3, 5, 6); in vitreous of patients 1 and 4 we have determined the IgE antibody levels only.

The results are shown in Table 1. IgG values are expressed in optical density (o.d.), IgE in percentage of bound radioactivity and positivity classes referred to four reference sera commercially available (Sferikit-Lofarma).

It has been suggested that OLM syndrome is caused by a lower number of larvae than visceral

Table 1—IgG and IgE values in sera and vitreous of patients with OLM syndrome

	Sera		Vitreous	
Patients	IgG TEX-ELISA o.d.	IgE TEX-RAST % bound radioactivity	IgG TEX-ELISA o.d.	IgE TEX-RAST % bound radioactivity
1	0·03	2·4 (cl*1)	n.t.	23.2 (cl 4)
2	0·50	6·3 (cl 2)	n.t.	n.t.
3	1·00	15·0 (cl 3)	1·20	15·2 (cl 3)
4	1·13	24·8 (cl 4)	n.t.	12·4 (cl 2)
5	0·60	11·2 (cl 3)	1·40	25·5 (cl 4)
6	0·75	17·5 (cl 3)	1·00	18·3 (cl 3)
7	0·45	6·0 (cl 2)	n.t.	n.t.
8	0·60	18·5 (cl 2)	n.t.	n.t.
9	1·53	19·1 (cl 3)	n.t.	n.t.
10	0·06	6·2 (cl 2)	n.t.	n.t.
11	0·50	5·2 (cl 2)	n.t.	n.t.
12	0·45	8·3 (cl 2)	n.t.	n.t.

TEX-ELISA cut off 0·45
n.t.: not tested
*cl: class

ANEXO-25

Interstitial pneumonitis in canine visceral leishmaniasis

Duarte, M.I.S.; **Laurenti, M.D.;** Nunes, V.L.B.; Rego Jr, F.A.; Oshiro, E.T; Corbett, C.E.P.

Revista do Instituto de Medicina Tropical de São Paulo 1986, 28(6): 431-436

Rev. Inst. Med. trop. São Paulo
28(6):431-436, *novembro-dezembro*, 1986

INTERSTITIAL PNEUMONITIS IN CANINE VISCERAL LEISHMANIASIS

M. I. S. DUARTE (1), M. D. LAURENTI (2), V. L. BRANDAO NUNES (3), A. F. REGO JR. (4), E. T. OSHIRO (5) & C. E. P. CORBETT (1)

SUMMARY

Forty-one naturally infected dogs with visceral leishmaniasis from an urban area of Corumbá (Mato Grosso do Sul-BRAZIL) were studied and three types of lung involvement due to visceral leishmaniasis were characterized; a cellular, a cellular-fibrotic and a fibrotic type. These types seem to represent a sequential evolutive process. Visceral leishmaniasis frequently causes an interstitial pneumonitis in naturally infected dogs (80.5%) as well as in man and experimentally infected hamsters

KEY WORDS: Visceral leishmaniasis; Interstitital pneumonitis; Canine pathology.

INTRODUCTION

Foci of canine visceral leishmaniasis in Brazil, together with human cases, suggest that the dog is an important host of this protozoan disease. In the Northeast of Brazil the disease is endemic (ALENCAR, 1959 [3]; ALENCAR & CUNHA, 1983 [4]; BRENER, 1957 [10]; DEANE & DEANE, 1954 [16]; DEANE & DEANE, 1955 [17]; ESPINOLA GUEDES et al., 1974 [22] and SHERLOCK & ALMEIDA, 1969 [33]). Nevertheless, outbreaks of the disease have also been well characterized in other regions (I Reunião Nacional sobre Pesquisa em Leishmaniose, 1984 [32]). Nowadays new human cases have been reported in Brazil. New cases have been reported in São Luis (Maranhão), in the outskirts of Maceió (Alagoas), in Paraíba, in Rio de Janeiro and in Corumbá (Mato Grosso do Sul) (I Reunião Nacional sobre Pesquisa em Leishmaniose, 1984 [34]).

The histopathology of canine visceral leishmaniasis has not been well characterized so far. Few references have been reported on the identification of parasites in the tissue along with infiltrates of mononuclear inflammatory cells in different organs (ADLER & TCHERMONORETZ, 1946 [2]; ALENCAR, 1959 [3]; ALVARENGA, 1960 [5]; ANDERSON et al. 1980 [6]; BRENER, 1957 [10]; CORBIEL et al, 1976 [13]; GEORGE et al, 1976 [24]). Interstitial pneumonitis and considered to be highly suggestive of visceral leishmaniasis (DUARTE et al, 1985 [21]) described in man (ANDRADE, 1959 [8] and RASO & SIQUEIRA, 1964 [31]) has been found in 62.5% of the autopsy material (CHASSOT et al, 1983 [11]).

The histopathology of the lung has not been characterized so far in canine visceral

(1) Professor Assistente Doutor do Departamento de Patologia da Faculdade de Medicina da Universidade de São Paulo, Av. Dr. Arnaldo, 455, 01246, São Paulo, Brasil
(2) Biomédica — Laboratório de Patologia de Moléstias Infecciosas da Faculdade de Medicina da Universidade de São Paulo
(3) Professora Titular de Parasiotlogia e Parasitologia Clínica do Departamento de Patologia do Centro de Ciências Biológicas e da Saúde da Universidade Federal do Mato Grosso do Sul.
(4) Médico Veterinário — IAGRO — Departamento de Vigilância Agropecuária de Corumbá, Mato Grosso do Sul, Brasil
(5) Médica Veterinária da Universidade Federal do Mato Grosso do Sul, Brasil

leishmaniasis. Rare cases of lung involvement were described stressing mainly the parasite's identification and concomitant secondary infections. TRYPHONAS, 1977 [34], described a marked septal thickening characterizing an interstitial pneumonitis in the lungs of a dog living in Spain for two years together with other visceral changes. In this case no parasites were found. In 1980, ANDERSON [6], found a diffuse multifocal septal thickening in the lungs of a dog from Texas with infiltration of plasma cells and histiocytes, some of which containing leishmania.

An outbreak of visceral leishmaniasis in Corumbá involving both men and dogs stimulated us to study the lungs of naturally infected dogs in order to characterize the histopathological changes due to the disease. Efforts were also directed to identify a possible relation between lesions found in dogs and those seen in man and hamsters.

MATERIAL AND METHODS

Forty-one dogs from Corumbá, presenting the usual clinical picture of the chronic phase of visceral leishmaniasis (ADLER & THEODOR, 1931 [1]; ALENCAR, 1959 [3]; ANOSA, 1983 [9]; BRENER, 1957 [10]; COVALEDA, HIVES & SOLER DURALL, 1951 [14]; CUNHA, 1938 [15]; DONATIEN & LESTOQUARD, 1935 [18]; FAURE-BROC, 1936 [23]; JOYEX & SANDET, 1938 [25]; KEENAN et al, 1984 [26]; LANNOTTE et al, 1979 [27]; LENNOX, SMART & LITTLE, 1972 [28]; MENDONZA et al, 1983 [29]; QUEIROZ, 1959 [30] and SHERLOCK & ALMEIDA, 1969 [33]) were studied. The animals presented wide-spread alopecia and furfuraceous scaling mainly around the nose and eyes, cutaneous ulcers, keratitis, long nails, low weight, high body temperatures, adenomegaly, arthritis and sometimes paralysis of the hind-legs. Identification of the agent was done by examination of skin lesions, spleen and liver smears; by parasite isolation in culture medium (NNN); by inoculation in hamsters followed in some cases by leishmania typing (isoenzymes and monoclonal antibodies — J. J. SHAW — The Wellcome Parasitology Unit. Belém, Pará, BR). Parasites were also found in histopathological specimens from liver, spleen, lymph nodes and skin. All organs showed histopathological changes compatible with visceral leishmaniasis.

Fragments from lungs and other organs were collected through autopsy of the dogs and fixed in phosphate buffered saline containing 10% formalin.

Lung fragments (4 μ thick) were stained by the hematoxylin-eosin, Masson's and Picro-sirius methods (CONSTANTINE & MOURAY, 1968 [12]). The picro-sirius stained slides were observed under polarized light in an optical microscope.

Four dogs from the same place, without clinical signs of visceral leishmaniasis, showed neither lung nor any other organ changes which could be related to the infection. These dogs were used is controls.

RESULTS

Histopathological pulmonary changes were found in 33 out of 41 cases. The main lesion was septal thickening which intensity and distribution varied from case to case with no preference for any specific area of the lung.

Based on the characteristics of the septal thickening changes were classified in three types:

1. "Cellular" (Figure 1): in which the septal thickening was due mainly to a mononuclear cells infiltrate (lymphocytes, plasma cells, macrophages and cells with fat-containing vacuolated cytoplasm). The septal capillaries showed congestion with no endothelial changes. Pneumocytes I and II of the alveolar lining were preserved. The intensity of the mononuclear cell infiltrate varied from area to area in the same cases and no correlation with any region was seen. There was at least one area of preserved parenchyma in all cases even in those with large involvement. Vicariant emphysema was found in the most severe cases.

2. "Fibrotic-cellular" (Figure 2): in which septal changes resulted from infiltration of mononuclear cells, as in the cellular type, associated with small bands of fibrous tissue. Septal capillaries and alveolar lining showed no changes. Vicariant emphysema was present in areas of higher involvement.

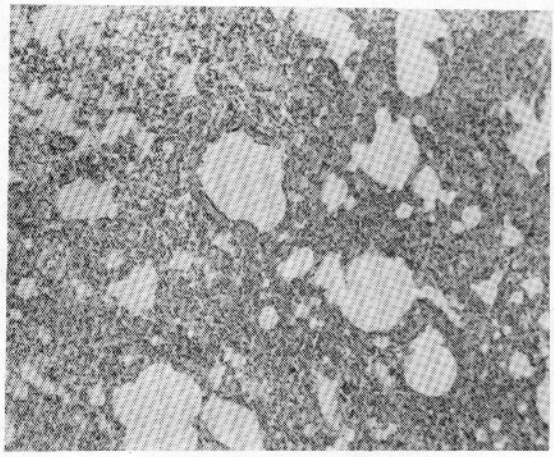

Fig. 1 — Cellular type: septal thickening by mononuclear cell infiltrate. HE X 100.

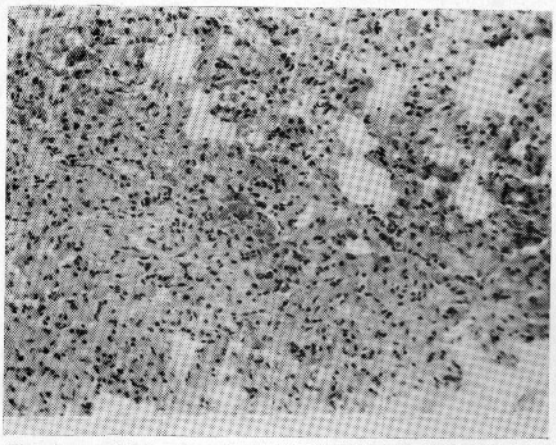

Fig. 2 — Cellular-fibrotic type: detail of the mononuclear cells infiltrate together with delicate bands of fibrous tissue within the septum. HE X 460.

3. "Fibrotic": bands of fibrous tissue thickening the intra-alveolar septum and involving large areas of the lung parenchyma were characteristic of this type. The alveolar lumen was preserved. Fibrosis was accompanied by discrete mononuclear cell infiltrate without alterations of capillaries and pneumocytes. Vicariant emphysema was related with the more fibrotic areas. Fibrosis, even thinner ones, could be demonstrated through the Picrosirius stain method when examined under polarized ligh (Figure 3 and 4).

In the whole there were no epithelial bronchial changes but in 2 cases there were discrete mononuclear cells infiltrate in the corium.

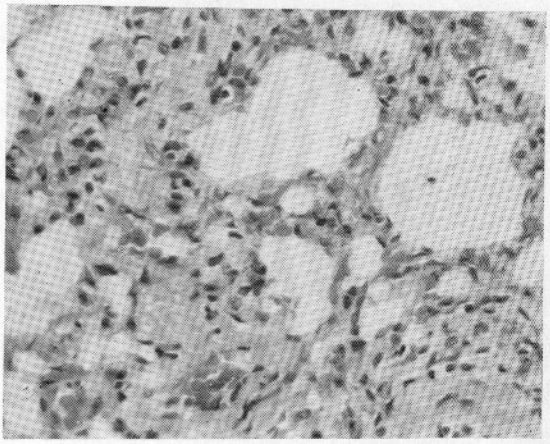

Fig. 3 — Fibrotic type: the fibrous tissue is much more evident than the mononuclear cell infiltrate. HE X 640.



Fig. 4 — Lung tissue treated with Picro-sirius stain and absorved under polarized light, showing septal thickening due to collagen fibers. X 100.

The alveolar lumen had neither edema or exsudation.

Amastigotes were found within the cytoplasma of either septal or alveolar macrophages only in the lungs of 3 of the cases with interstitial pneumonitis. However, numerous amastigotes were found in other tissues examined (skin, lymph nodes, spleen and liver). Eight of the cases showed no pulmonary histopathological changes.

DISCUSSION

No systematical reference on the pulmonary involvement in dogs with visceral leishmaniasis was found in the literature. There

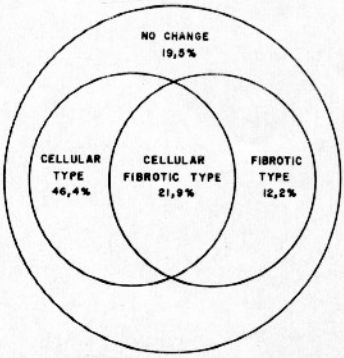

Fig. 5 — Distribution of the histopathological types of the septal thickening of the lung in 41 visceral leishmaniasis dogs.

are few reports describing bronchopneumonia as secondary infections and also few references on other pulmonary changes concurrent with this protozoan disease. GEORGE, in 1976 [24], related "focal interstitial thickening" in one dog, TRYPHONAS, in 1977 [34] and ANDERSON in 1980 [6], also described an "interstitial pneumonitis" in a dog, evading to suggest any relation to visceral leishmaniasis in spite of the identification of leishmania done by Anderson in the lung.

In this work we tried to define the pulmonary changes possible to occur in visceral leismaniasis by studying naturally infected dogs, caught during an urban epidemic outbreak of visceral leishmaniasis in Corumbá (Mato Grosso do Sul, BR). All animals had clinical signs of the disease and parasites were identified either in smears and histological tissue sections from their organs, by isolation in culture medium or by inoculation in hamsters.

It is important to point out that all animals had histopathological characteristics of visceral leishmaniasis showing no other pulmonary changes as bronchopneumonia or any other alveolar lumen involvement.

The pulmonary changes found in naturally infected dogs were frequent (80,5%) and characterized by an interstitial pneumonitis which we believe to be related to visceral leishmaniasis.

The different patterns of septal thickening were described according to the prominence of elements participating in each case. The cellular type (46,49%) is due mainly to a mononuclear cell infiltrate in the septum. The cellular-fibrotic type (21,9%) presents both mononuclear cell infiltrate and fibrosis. Finally, in the fibrotic type (12,2%), the septal changes originate from fibrosis. We believe that all three types represent evolutive phases of the same process. The fibrotic phase is subsequent to a previous septal inflammatory process.

In man, ANDRADE, 1958 [7] and 1959 [8], found interstitial pneumonitis in 3 out of 5 autopsies of patients with visceral leishmaniasis and considered it as part of the disease. RASO and SIQUEIRA, 1964 [31], described one more case of interstitial pneumonitis. Interstitial pneumonitis was found in 62,5% of autopsies and foci of septal fibrosis in 30% (DUARTE, M.I.S. -unpublished data). Amastigotes were rarelly found (CHASSOT et al, 1983 [11]) in lungs. Using an immunoenzimatic method (PAP- peroxidase anti-peroxidase) and specific antibodies, particulate antigenic material and/or amastigotes was found in the interalveolar septum, whenever interstitial pneumonitis was present (DUARTE et al, 1985 [21]). This fact confirms that septal changes are due to the disease. A few PAP tests in dog lung performed in our laboratory, showed the same results.

We have already demonstrated an interstitial pneumonitis developing in distinct stages in hamsters experimentally infected with **L. donovani** (DUARTE, 1979 [19]; DUARTE e CORBETT, 1984 [20]). There was a exsudative stage of short duration followed by cellular proliferation and later on, by fibrosis. All sequential changes between cellular proliferation and fibrosis could be characterized as part of the same process.

Therefore visceral leishmaniasis often determines an interstitial pneumonitis, either in man, or in naturally infected dogs, or even experimentally infected hamsters. The histopatological changes seen in each case depend on the evolution of the process. There is also a similarity of histopathological changes in the three species: man, dog and hamster. Interstitial pneumonitis seems to be the pulmonary representation of an interstitial pathology of visceral leishmaniasis, also seen in others organs with interstitial lesions such as liver and kidneys.

DUARTE, M. I. S.; LAURENTI, M. D.; BRANDÃO NUNES, V. L.; REGO JR., A. F.; OSHIRO, E. T. & CORBETT, C. E. P. — Interstitial pneumonitis in canine visceral leishmaniasis. **Rev. Inst. Med. trop. São Paulo, 28:**431-436, 1986. 1986.

RESUMO

Pneumonia intersticial na leishmaniose visceral canina

Estudamos 41 cães naturalmente infectados com leishmaniose visceral, provenientes da área urbana de Corumbá (Mato Grosso do Sul, BR) e caracterizamos 3 tipos de acometimento pulmonar devido à leishmaniose visceral: celular, fibrótico-celular e fibrótico. Estes tipos parecem representar um processo evolutivo seqüencial. A leishmaniose visceral causa uma pneumonite intersticial em 80.5% dos cães naturalmente infectados à semelhança do que ocorre no homem e em hamsteres experimentalmente infectados.

ACKNOWLEDGEMENTS

This work was supported by FINEP: 43/83/0006/00.

REFERENCES

1. ADLER, S. & THEODOR, O. — Skin infection in canine visceral leishmaniasis. **Brit. med. J., 2:** 1179, 1931

2. ADLER, S. & TCHERNOMRETZ, I. — Failure to cure natural canine visceral leishmaniasis. **Ann. trop. Med. Parasit., 40:** 320-324, 1946.

3. ALENCAR, I. E. — **Calazar canino.** Contribuição para o estudo da epidemiologia do calazar no Brasil. Fortaleza. Imprensa Oficial, 1959.

4. ALENCAR, J. E. & CUNHA, R. B. — Survey of canine Kala-azar in Ceará. Latest results. **Rev. bras. Malar., 15:** 391-403, 1963.

5. ALVARENGA, R. J. — Histopathology of Chagas disease and of Kala-azar in naturally infected dogs. **Hospital (Rio de J.), 57:** 23-40, 1960.

6. ANDERSON, D. C.; BUCKNER, R. G.; GLENN, B. L. & MacVEAN, D. W. — Endemic canine leishmaniasis. **Vet. Path., 17:** 94-96, 1980.

7. ANDRADE, Z. A. — A patologia da leishmaniose visceral (Kala-azar). Salvador, 1958. (Tese — Faculdade de Medicina da Universidade da Bahia).

8. ANDRADE, Z. A. — Pneumonite intersticial no calazar. **Hospital (Rio de J.), 55:** 71, 1959.

9. ANOSA, V. O. & IDOWU, A. L. — The clinico-haematological features and pathology of leishmaniasis in a dog in Nigeria. **Zbl. Vet. Med. B., 30:** 600-608, 1983.

10. BRENER, Z. — Calazar canino em Minas Gerais. Belo Horizonte, 1957. (Tese de doutoramento — Faculdade de Mediicna da Universidade de Minas Gerais).

11. CHASSOT, C. A.; MORAIS, C. F.; DUARTE, M. I. S. & AMATO NETO, V. — Pneumonite intersticial da leishmaniose visceral: estudo histopatológico em necrópsias. In: CONGRESSO DA SOCIEDADE BRASILEIRA DE MEDICINA TROPICAL, 19., Rio de Janeiro, 1983. **Programa e resumos.** Rio de Janeiro, Imprina, 1983. p. 63.

12. CONSTANTINE, V. S. & MOWRY, R. W. — Selective staining of human dermall collagen. II. The use of picrosirius red F3BA with polarization microscopy. **J. invest. Derm., 50:** 419-423, 1968.

13. CORBIEL, L. B.; WRIGHT-GEORGE, J.; SHIVELY, J. N.; DUNCAN, J. R.; LA MOTTE, G. B. & SCHULTZ, R. D. — Canine visceral leishmaniasis with amyloidosis: an immunopathological case study. **Clin. Immunol. Immunopath., 6:** 165-173, 1976.

14. COVALEDA, J.; HIVES, J. & SOLER DURALL, C. — Canine leishmaniasis in Barcelona; preliminary report. **Rev. Sanid. Hig. Públ., 25:** 710-712, 1951.

15. CUNHA, A. M. — Infecção da pele na leishmaniose visceral experimental do cão. **Brasil-méd., 52:** 1071-1072, 1938.

16. DEANE, L. M. & DEANE, M. P. — Finding of dogs naturally infected with **Leishmania donovani** in Ceará. **Hospital (Rio de J.), 45:** 703-707, 1954.

17. DEANE, L. M. & DEANE, M. P. — Urban visceral leishmaniasis in dog and man in Sobral, Ceará. **Hospital (Rio de J.), 47:** 75-87, 1955.

18. DONATIEN, A. & LESTOQUARD, F. — Notes sur la leishmaniose viscérále canine. **Bull. Soc. Path. exot., 6:** 426-431, 1935.

19. DUARTE, M. I. S. — Pneumonite intersticial no calazar. São Paulo, 1979. (Tese de doutoramento — Faculdade de Medicina da Universidade de São Paulo).

20. DUARTE, M. I. S. & CORBETT, C. E. P. — Histopathological and ultrastructural aspects of intestitial pneumonitis of experimental visceral leishmaniasis. **Trans. roy. Soc. trop. Med. Hyg., 78:** 683-688, 1984.

21. DUARTE, M. I. S.; MATTA, V. L. R.; GOTO, H.; ALVES, V. A. F. & CORBETT, C. E. P. — Pneumopatia na leishmaniose visceral humana: detecção de amastigotas e seus produtos em pulmão por método imunoenzimático. In: CONGRESSO DA SOCIEDADE BRASILEIRA DE MEDICINA TROPICAL, 21., São Paulo, 1985. **Programa e resumos.** São Paulo, Balleiro Editores, 1985. p. 106-107.

22. ESPINOLA GUEDES, G.; MAROYA, A.; CHAVES, E.; ESTÉLIO, .; CUNHA, M. J. & ARCOVERDE, S. — Calazar no litoral do Estado da Paraíba, Brasil. Encontro de 70 casos humanos e 16 caninos. **Rev. Inst. Med. trop. S. Pulo, 16:** 265-269, 1974.

23. FAURE, B. G. — La Leishmaniose canine (Sa fréquence son diagnostic clinique et biologique, son traitment). **Biol. méd. (Paris), 26:** 113-158, 1936.

24. GEORGE, J. W.; NIELSEN, S. W.; SHIVELY, J. N.; HOPES, S. & MROZ, S. — Canine leishmaniasis with amyloidosis. **Vet. Path., 13:** 365-373, 1976.

25. JOYEUX, C. & SANDET, J. — Observations sur la leishmaniose canine méditerranéenne. **Bull. Soc. Path. exot., 31:** 487, 1938.

26. KEENA, C. M.; HENRICKS, L. D.; LIGHTNER, L.; WEBSTER, J. K. & JOHNSON, A. J. — Visceral leishmaniasis in the germann shepherd dog. I — Infection clinical disease and clinical pathology. II — Pathology. **Vet. Path., 21:** 74-86, 1984.

27. LANNOSTTE, G.; RIOUX, J. A.; PERIERES, J. & VOLLHARDT, Y. — Developmental stages and clinical characterization of canine leishmaniasis in relation to epidemiology **Ann. Parasit. hum. comp., 54:** 277-295, 1979.

28. LENNOX, W. J.; SMART, M. E. & LITTLE, P. B. — Case report. Canine leishmaniasis in Canada. **Canad. vet. J., 13:** 188-190, 1972.

29. MENDONZA, L.; PODETTI, M.; CHAVEZ, F. & ZELEDÓN, R. — Visceral leishmaniasis in a dog introduced into Rosta Rica. **Trans. roy. Soc. trop. Med. Hyg., 77:** 283-284, 1983.

30. QUEIROZ, J. M. — Lesions of the eyeball and adnexa in canine Kala-azar. **Rev. Ass. med. bras., 5:** 304-309, 1959.

31. RASO, P. & SIQUEIRA, J. T. — Subsídio ao conhecimento da anatomia patológica da leishmaniose visceral, com especial referência às lesões pulmonares e cardíacas. **Hospital (Rio de J.), 65:** 144-163, 1964.

32. REUNIÃO NACIONAL SOBRE PESQUISA EM LEISHMANIOSE, I. — Faculdade de Medicina da Universidade de São Paulo, Departamento de Patologia, São Paulo, Brasil, 1984.

33. SHERLOCK, J. A. & ALMEIDA, S. P. — Findings on Kala-azar in Jacobina, Bahia. II — Canine leishmaniasis. **Rev. bras. Malar., 21:** 535-539, 1969.

34. TRYPHONAS, L.; ZAWDZKA, Z.; BERNARD, M. A. & JANZEN, E. A. — Visceral leishmaniasis in a dog: clinical hematological and pathological observations. **Canad. J. comp. Med., 41:** 1-12, 1977.

Recebido para publicação em 4/12/85.

ANEXO-26

Comparison of parasitological, immunological and molecular methods for the diagnosis of leishmaniasis in dogs with different clinical signs

Moreira, M.A.B.; Luvizotto, M.C.R.; Garcia, J.F.; Corbett, C.E.P.; **Laurenti, M.D.**

Veterinary Parasitology 2007; 145: 245-252

Available online at www.sciencedirect.com
ScienceDirect
Veterinary Parasitology 145 (2007) 245–252
veterinary parasitology
www.elsevier.com/locate/vetpar

Comparison of parasitological, immunological and molecular methods for the diagnosis of leishmaniasis in dogs with different clinical signs

M.A.B. Moreira [a,b], M.C.R. Luvizotto [b], J.F. Garcia [c], C.E.P. Corbett [a], M.D. Laurenti [a,*]

[a] *Laboratory of Infectious Diseases Pathology, Department of Pathology, Medical School, University of São Paulo (USP), São Paulo, Brazil*
[b] *Laboratory of Pathology, Department of Animal Clinic, Surgery and Reproduction, School of Veterinary Medicine, São Paulo State University (UNESP), Araçatuba, Brazil*
[c] *Department of Animal Production and Health, School of Veterinary Medicine, São Paulo State University (UNESP), Araçatuba, Brazil*

Received 13 March 2006; received in revised form 23 November 2006; accepted 18 December 2006

Abstract

Aiming to improve the diagnosis of canine leishmaniasis (CanL) in an endemic area of the Northwest region of São Paulo State, Brazil, the efficacy of parasitological, immunological and molecular diagnostic methods were studied. Dogs with and without clinical signs of the disease and positive for *Leishmania*, by direct parasite identification on lymph node smears and/or specific antibody detection by ELISA, were selected for the study. According to the clinical signs, 89 dogs attending the Veterinary Hospital of UNESP in Araçatuba (SP, Brazil) were divided into three groups: symptomatic (36%), oligosymptomatic (22%) and asymptomatic (22%). Twenty-six dogs from an area non-endemic for CanL were used as negative controls (20%). Fine-needle aspiration biopsies (FNA) of popliteal lymph nodes were collected and Diff-Quick®-stained for optical microscopy. Direct immunofluorescence, immunocytochemistry and parasite DNA amplification by PCR were also performed. After euthanasia, fragments of popliteal lymph nodes, spleen, bone marrow and liver were collected and processed for HE and immunohistochemistry. Parasite detection by both HE and immunohistochemistry was specifically more effective in lymph nodes, when compared with the other organs. Immunolabeling provided higher sensitivity for parasite detection in the tissues. In the symptomatic group, assay sensitivity was 75.61% for direct parasite search on Diff-Quick®-stained FNAs, 92.68% for direct immunofluorescence, 92.68% for immunocytochemistry and 100% for PCR; the corresponding values in the other clinical groups were: 32, 60, 76 and 96% (oligosymptomatic), and 39.13, 73.91, 100 and 95.65% (asymptomatic). Results of the control animals from the CanL non-endemic area were all negative, indicating that the methods used were 100% specific.

Keywords: Canine leishmaniasis; *Leishmania* (*Leishmania*) *infantum chagasi*; Diagnosis; Enzyme-linked immunosorbent assay (ELISA); Polymerase chain reaction (PCR); Immunohistochemistry

1. Introduction

American Visceral Leishmaniasis (AVL) is an infectious disease of chronic evolution caused by the protozoan *Leishmania* (*Leishmania*) *infantum chagasi*,

* Corresponding author at: Faculdade de Medicina, USP, Departamento de Patologia, Av. Dr. Arnaldo 455, 1º andar, sala 1209, 01246-903-Cerqueira César, São Paulo (SP), Brazil.
Tel.: +55 11 3081 7799; fax: +55 11 3081 7799.
E-mail address: mdlauren@usp.br (M.D. Laurenti).

0304-4017/$ – see front matter
doi:10.1016/j.vetpar.2006.12.012

which is transmitted mainly by the vector *Lutzomyia longipalpis*, with incrimination of *Lutzomyia evansi* in parts of Colombia and Venezuela and *Lutzomyia cruzi* in Mato Grosso State in Brazil (Santos et al., 1998).

Dogs are considered the main domestic reservoir of the parasite, constituting part of the epidemiological cycle of human transmission (Deane and Deane, 1955a,b; Laison and Shaw, 1987), with Brazil accounting for more than 90% of VL cases described in the New World (Grimaldi and Tesh, 1993). Canine leishmaniasis (CanL) and human visceral leishmaniasis (VL) occur endemically in many states of the North, Northeast and Mid-West regions of Brazil. They are also found in the Southeast states of Minas Gerais, Rio de Janeiro and, more recently, in the Northwest area of São Paulo State (Yamamoto et al., 1988; Evans et al., 1990; Costa et al., 1991; Paranhos-Silva et al., 1996; Tafuri et al., 1996; Feitosa et al., 2000).

According to the clinical signs, Mancianti et al., 1988 classified dogs infected with *L. infantum* as: symptomatic, those presenting more than three clinical signs; oligosymptomatic, from one to three clinical signs; and asymptomatic dogs, with no clinical signs. The most frequent clinical signs found were lymphadenomegaly, weight loss, dermatological changes and onychogryphosis. However, CanL is considered to have an extraordinary pleomorphism of clinical signs and mimesis with other diseases, showing nonspecific microscopic lesions similar to those observed in other infectious and immunomediated disorders (Ferrer, 1999).

The classic methodology for leishmaniasis diagnosis includes direct microscopic identification of the parasites on Diff-Quick®-stained preparations, parasite isolation in culture medium and parasite inoculation in experimental animals. In endemic areas, serological tests are used for diagnosis and also as tools in epidemiological studies, the most employed techniques being complement fixation (Costa et al., 1991), indirect immunofluorescence (Vexenat et al., 1993) and ELISA (Mukerji et al., 1991). Recently, immunohistochemistry for specific identification of the parasite (Ferrer et al., 1988), and polymerase chain reaction (PCR) for the detection of *Leishmania* DNA (Harris et al., 1998), have been used with high sensitivity.

Increasing numbers of VL cases have been detected in the Northwest area of São Paulo State. Considering the involvement of dogs as a reservoir of the disease, the present study regarding the sensitivity and specificity of parasitological, immunological and molecular diagnostic methods was undertaken with the aim of improving disease diagnosis in dogs. To this end, both direct parasite exposure by conventional staining or specific parasite immunolabeling, as well as parasite DNA detection by PCR, were applied to fine-needle aspirate (FNA) biopsies of popliteal lymph nodes and samples of lymph node, spleen, bone marrow and liver fragments from dogs naturally infected with *L.* (*L.*) *infantum chagasi*.

2. Materials and methods

2.1. Animals

Dogs with or without clinical signs of the disease and showing parasites in lymph nodes smears and/or positive ELISA tests were selected for the study. According to clinical signs, 89 dogs attending the Veterinary Hospital of UNESP in Araçatuba (SP), Brazil were divided into three groups: symptomatic dogs, >3 clinical signs ($n = 41$); oligosymptomatic dogs, one to three clinical signs ($n = 25$), and asymptomatic dogs, with no clinical signs ($n = 23$) (Mancianti et al., 1988). Lymphadenomegaly, weight lost, skin changes, onychogryphosis and apathy were the main clinical signs observed. Dogs from the kennel of the Medical School of São Paulo University recovered from areas with no records of autochthonous cases of leishmaniasis ($n = 26$), were used as negative controls. The dogs were anesthetized with sodium thiopental 25 mg/kg; blood samples were drawn by jugular puncture. Euthanasia was performed by intravenous injection of 19.1% potassium chloride. The sera were stored at −20 °C for enzyme-linked immunosorbent assay (ELISA).

2.2. Tissue fragments

After euthanasia, fragments of popliteal lymph nodes, spleen, bone marrow and liver were collected and fixed in 0.01 M phosphate buffered 10% formaldehyde solution, pH 7.4. Paraffin embedded sections were stained with hematoxylin and eosin (HE), or processed for immunohistochemistry (IHC), in order to evaluate tissue parasitism.

2.3. Fine-needle aspiration of lymph node

Samples of popliteal lymph nodes were aspirated with a thin needle, transferred to polypropylene tubes and stored at −20 °C for PCR. Slide smears were also prepared, stained with Diff-Quick® and examined by optical microscopy, for parasitism evaluation. Additional smears were fixed in acetone/alcohol solution and

stored at −20 °C for direct immunofluorescence (DIF) and immunocytochemistry (ICC).

2.4. Enzyme-linked immunosorbent assay (ELISA)

Microplates were sensitized with 10 μl/well of *L.* (*L.*) *infantum chagasi* total antigen (20 μg/ml) in 0.05 M carbonate buffer pH 9.6, at 4 °C overnight (Riera et al., 1999). After blocking for 2 h with 200 μl/well of 0.01 M phosphate buffered saline (PBS) with 10% fetal calf serum (FCS), 100 μl/well of samples diluted at 1:400 in 0.01 M PBS with 0.05% Tween and 10% FCS were incubated at room temperature for 3 h. The microplates were then washed three times with 0.01 M PBS containing 0.05% Tween. Next, 100 μl of peroxidase labeled secondary antibody was added to each well and incubated at room temperature for 1 h. After further washing, 100 μl/well of 0.4 mg/ml *o*-phenylenediamine (OPD) and 0.4 μl/ml hydrogen peroxide was added. Color development was carried out in a dark chamber for 5 min at room temperature; the reaction was interrupted with 50 μl/well of 1 M H_2SO_4, and absorbance was measured at 492 nm using an ELISA reader. The reaction cut-off was determined as previously reported by Voller et al. (1980).

2.5. Direct immunofluorescence

Smears of popliteal lymph nodes previously fixed and stored at −20 °C were incubated with fluorescein-conjugated hamster anti-*L.* (*L.*) *infantum chagasi* polyclonal antibody (Moreira et al., 2002) diluted 1:250 in Evans Blue solution; incubation was carried out in a humid chamber at 37 °C for 30 min. After this period, the slides were washed three times in 0.01 M PBS, mounted with cover slips using glycerine as a mounting medium and observed under a fluorescence microscope. The reactions were compared against both positive (lymph nodes smears with high numbers of amastigotes, as revealed by Diff-Quick®) and negative (lymph nodes smears of dogs from a non-endemic area) controls.

2.6. Immunohistochemistry

Paraffin-embedded sections were dewaxed and rehydrated. The antigen was retrieved by steaming in 10 mM citric acid solution pH 6.0 for 3 min in a pressure cooker. Endogenous peroxidase activity was blocked with 3% hydrogen peroxide (H_2O_2) in water (three changes, 10 min each) followed by 2.5% hydrogen peroxide in methanol (three changes, 10 min each). Nonspecific interactions of secondary antibody were blocked with 1.5% normal swine serum in 0.01 M PBS with incubation for 1 h in a humid chamber at 37 °C. Nonspecific ionic interactions were blocked with a solution of powdered skimmed milk, 60 g/L diluted in distilled water and incubated for 30 min at room temperature.

Immunolabeling was performed with mouse anti-*Leishmania* polyclonal antibody diluted 1/3000 in 0.01 M PBS containing 1% bovine serum albumin; incubation was carried out in a humid chamber, first at 37 °C for 1 h and then at 4 °C overnight. After washing, the sections were incubated with biotinylated secondary antibody and then with streptavidin–peroxidase complex from LSAB kit (Dako, USA), both incubations were performed at 37 °C for 30 min. Color reaction was developed for 5 min at room temperature using as substrate 3-3-diamenobenzidine (Sigma, USA) at 60 mg/100 ml 0.01 M PBS containing 1% hydrogen peroxide. The sections were counterstained with hematoxylin, dehydrated and mounted in resin.

For immunocytochemistry reaction, the smears of popliteal lymph nodes previously fixed and stored at −20 °C, were directly incubated with 3% hydrogen peroxide to block the endogenous peroxidase and the reaction followed the same steps as immunohistochemistry.

2.7. Polymerase chain reaction (PCR)

2.7.1. DNA purification of parasites in culture and clinical samples

Promastigotes of *L.* (*L.*) *infantum chagasi*, *L.* (*V.*) *braziliensis* and *L.* (*L.*) *amazonensis* obtained from culture were used as positive controls for the reaction. Samples of FNA popliteal lymph node and controls were washed by centrifugation in sodium citrate (SSC) buffer at 1400 rpm for 5 min. Lysis buffer (375 μl of 0.2 M sodium acetate, 25 μl of 10% sodium dodecyl-sulfate and 5 μl of 20 mg/ml K proteinase) was added to the pellets, followed by incubation at 37 °C overnight. The lysates were treated with phenol/chloroform/isoamyl alcohol (25:24:1); DNA was precipitated with ethanol, dried and resuspended in 200 μl of TE buffer.

2.7.2. Primers

The pair of primers was prepared according to Rodgers et al. (1990), with initiators (13A and 13B) that amplify the DNA fragments of kinetoplast minicircles; this region is preserved in the different species of *Leishmania*.

2.7.3. DNA amplification

PCR consisted of: Taq buffer (50 mM KCl, 10 mM Tris pH 8.4), $MgCl_2$ standardized concentration of 1.5 mM, dNTPs (dATP, dCTP, dGTP and dTTP), initiators 13A and 13B, Taq DNA polymerase and DNA, in a final volume of 50 μl.

The samples were amplified in a thermocycler (PTC-100 MJ-Research) using an initial denaturation step of 95 °C for 5 min, followed by 30 cycles of 94 °C for 30 s, 54 °C for 45 s, and 72 °C for 30 s, with a final extension at 72 °C for 5 min; the samples were then kept at 4 °C until the next step. Amplification with primers 13A and 13B resulted in products of 120 base pairs (bp). Negative (tube without DNA) and positive (DNA from *Leishmania* culture) controls were performed for each experiment. After amplification, the PCR products were subjected to 2% agarose gel electrophoresis, stained with ethidium bromide and photographed under ultraviolet light.

2.8. Statistical analysis

The results of the different diagnostic methods were submitted to statistical analysis using the SPSS software (version 8.0) for Windows to determine the sensitivity and specificity of each test. The gold standard test was considered the direct search for parasites in fine-needle aspiration of popliteal lymph nodes.

In order to evaluate the of concordance index between two diagnostic methods, Kappa measurement was employed, where 0 indicates no concordance and 1 total concordance. Clinical status was compared based on the results from the different diagnostic methods using the Pearson chi square test. The Fisher test was applied when the expected values were below 5 and the results were considered significant, showing at p value <0.05.

3. Results

3.1. Enzyme-linked immunosorbent assay (ELISA)

The detection of anti-*Leishmania* antibodies in serum by ELISA was positive in 37/41, 17/25 and 22/23 dogs of the symptomatic, oligosymptomatic, and asymptomatic group, respectively. All 26 control dogs were negative. Thus, ELISA test sensitivity for each clinical group was 87.80%, symptomatic; 68.00%, oligosymptomatic; and 95.65%, asymptomatic; assay specificity was 100% (Table 1).

Table 1
Sensitivity of enzyme-linked immunosorbent assay (ELISA), cytology, direct immunofluorescence (DIF), immunocytochemistry (ICC) and polymerase chain reaction (PCR) of lymph node FNA biopsies of dogs with different clinical signs

Diagnostic method	Clinical signs		
	Symptomatic (%)	Oligosymptomatic (%)	Asymptomatic (%)
ELISA	87.80	68.00	95.65
Cytology	75.61	32.00	39.13
DIF	92.68	60.00	73.91
ICC	92.68	76.00	100.00
PCR	100.00	96.00	95.65

Assay specificity was 100% for all the diagnostic methods in all the clinical groups.

3.2. Tissue fragments

3.2.1. Popliteal lymph nodes

Optical microscopy of lymph node sections stained with HE showed *Leishmania* amastigotes in macrophage cytoplasm in 18/41 (43.90% sensitivity), 10/25 (40.00% sensitivity) and 9/23 (39.13% sensitivity) dogs of the symptomatic, oligosymptomatic and asymptomatic groups, respectively. In contrast, immunohistochemistry presented higher sensitivity, revealing parasite presence in 27/41 (65.85% sensitivity), 17/25 (68.00% sensitivity), 17/23 (72.73% sensitivity) dogs of the symptomatic, oligosymptomatic and asymptomatic groups, respectively. For both assays specificity was 100% (Table 2).

3.2.2. Spleen

HE from spleen samples showed positivity in 11/41, 7/25 and 8/23 dogs of the symptomatic, oligosymptomatic and asymptomatic groups, respectively, with corresponding sensitivities of 43.90, 40.00 and 38.13%. Immunohistochemistry of samples indicated positive diagnosis in 25/41, 16/25 and 16/23 dogs, respectively, and assay sensitivities of 60.98, 64.00 and 69.57%. For both assays specificity was 100% (Table 2).

3.2.3. Bone marrow

HE stained tissue revealed the presence of amastigotes in symptomatic, oligosymptomatic and asymptomatic dogs at ratios of 11/41, 3/25 and 5/23, with assay sensitivities of 26.83, 12.00, and 21.74%. Immunohistochemistry permitted the identification of amastigote parasites in 24/41 symptomatic, 8/25 oligosymptomatic and 11/23 asymptomatic dogs, with assay sensitivities of 58.54, 32.00 and 47.83%. For both assays specificity was 100% (Table 2).

Table 2
Sensitivity of hematoxylin and eosin (HE) and immunohistochemistry (IHC) methods in lymph node, spleen, bone marrow and liver of dogs with different clinical signs

Organs	Diagnostic method	Clinical signs		
		Symptomatic (%)	Oligosymptomatic (%)	Asymptomatic (%)
Lymph node	HE	43.90	40.00	39.13
	IHC	65.85	68.00	72.73
Spleen	HE	36.59	28.00	34.78
	IHC	60.98	64.00	69.57
Bone marrow	HE	26.83	12.00	21.74
	IHC	58.54	32.00	47.83
Liver	HE	26.83	12.00	13.04
	IHC	53.66	40.00	56.52

Assay specificity was 100% for all the diagnostic methods in all the clinical groups.

3.2.4. Liver

HE staining of liver samples revealed the presence of *Leishmania* amastigotes in 11/41 symptomatic, 3/25 oligosymptomatic and 3/23 asymptomatic dogs, with corresponding sensitivities of 26.83, 12.00 and 13.04%, and 100% assay specificity. Immunohistochemistry of liver identified amastigotes in 22/41 symptomatic, 10/25 oligosymptomatic and 13/23 asymptomatic dogs, with corresponding sensitivities of 53.66, 40.00 and 56.52%; the assay specificity was also 100% (Table 2).

3.3. FNA of popliteal lymph node

3.3.1. Cytological examination

Diff-Quick® staining of popliteal lymph node FNA revealed the presence of typical *Leishmania* amastigotes in 34/41 symptomatic, 8/25 oligosymptomatic and 9/23 asymptomatic dogs, with assay sensitivities of 75.61, 32.00 and 39.13%, respectively; assay specificity was 100% (Table 1).

3.3.2. Direct immunofluorescence (DIF)

Parasite search by direct immunofluorescence in popliteal lymph node smears showed positive reaction in 38/41 symptomatic, 15/25 oligosymptomatic and 17/23 asymptomatic dogs. All the controls showed negative results. DIF sensitivities for the symptomatic, oligosymptomatic and asymptomatic groups were thus 92.68, 60.00 and 73.91%, respectively, and assay specificity was 100% (Table 1).

3.3.3. Immunocytochemistry (ICC)

Immunolabeling of *Leishmania* amastigotes by immunocytochemistry was positive in 38/41, 19/25 and 23/23 dogs of the symptomatic, oligosymptomatic and asymptomatic group, with assay sensitivities of 92.68, 76 and 100%, respectively. No reaction was observed in the control group, demonstrating 100% assay specificity (Table 1).

3.3.4. Polymerase chain reaction (PCR)

For the standardization of PCR, samples of *L.* (*L.*) *infantum chagasi*, *L.* (*L.*) *braziliensis e L.* (*L.*) *amazonensis* were utilized. Agarose gel electrophoresis revealed DNA amplification of a 120 bp from all species. DNA samples from popliteal lymph node FNA subjected to PCR demonstrated that 41/41 of the samples were positive in the symptomatic group (Table 1). In the oligosymptomatic and asymptomatic groups, PCR showed positive reactions in 24/25 and 22/23 of the samples, respectively. The presence of the 120 pb band was not found in any of the control samples. These results show that PCR sensitivity was 100.00, 96.00 and 95.65% for the symptomatic, oligosymptomatic and asymptomatic groups, respectively, and that assay specificity was 100%.

Comparative analysis of assay performance for the various diagnostic methods showed that ELISA and immunocytochemistry were most efficient in samples of asymptomatic dogs ($p < 0.05$). Direct identification of parasites by Diff-Quick® staining and direct immunofluorescence were more efficient in smears from symptomatic dogs, followed by asymptomatic and oligosymptomatic dogs ($p < 0.05$). PCR was found to be highly efficient for all the clinical manifestations of CanL.

4. Discussion

Of the 89 dogs studied, 41 (46.1%) were diagnosed as symptomatic, 25 (28.1%) as oligosymptomatic and 23 (25.8%) as asymptomatic, according to the

classification of Mancianti et al. (1988). According to the present results, the most frequent clinical signs found for both symptomatic and oligosymptomatic dogs were lymphadenomegaly, weight loss, dermatological changes and onychogryphosis.

Serum testing for anti-*Leishmania* antibodies by indirect immunofluorescence (IF) and ELISA coupled with clinical evaluation, is a widely used strategy for CanL diagnosis. ELISA shows higher sensitivity and specificity in comparison with IF (Evans et al., 1990; Mancianti et al., 1995). In the present study, ELISA was employed in conjunction with routine histological parasite detection, as part of the procedure used to define symptomatic, oligosymptomatic and asymptomatic dogs. The reaction cut-off was based on the arithmetic mean of OD values from 26 healthy dog sera, plus three standard deviations (Voller et al., 1980). Since a CanL-positive serological test implied euthanasia of the canine in question and in view of the fact that contact with the parasite and the subsequent humoral response does not necessarily indicate active infection, a high cut-off value was selected in order to avoid false positives. In the present work, ELISA assay sensitivity indicated a more pronounced anti-*Leishmania* humoral response with specific antibody production among the asymptomatic dogs, followed by symptomatic and oligosymptomatic dogs. The between-group variation regarding the frequency of positive results in the ELISA assay presented here, agrees with observations reported by Pinelli et al. (1994), who detected the immunosuppression of antibody production by *Leishmania* antigen in symptomatic dogs. Serological results at variance with direct parasite evidence have been discussed by Lanotte et al. (1979) and Slappendel (1988), who observed that *Leishmania*-positive dogs, as defined by direct cytological evaluation, were negative for IF.

With respect to the etiological diagnosis of the disease, direct parasite detection in HE stained paraffin-embedded sections of lymphoid organs was more effective in popliteal lymph nodes, regardless of the clinical group analyzed, followed by the spleen and bone marrow. Such results agree with the findings of Keenan et al. (1984), who reported the identification of amastigote forms within lymphoid organ macrophages. However, immunohistochemistry proved to be a more sensitive assay for parasite detection when compared with the routine histological evaluation, especially in lymph nodes (Ferrer et al., 1988; Ramos et al., 1994; Azedeh et al., 1994; Ferrer, 1999).

Several authors pointed out that microscopic evaluation of liver sections stained with HE is not very sensitive for parasite detection (Keenan et al., 1984; Duarte et al., 1989). In the present study, immunolabeling of liver samples showed improved sensitivity in comparison with routine histological evaluation in all the clinical groups studied. Analyzing the present data regarding sensitivity, it is possible to conclude that immunohistochemistry provided improved diagnosis, especially for asymptomatic dogs. Sotto et al. (1989), while comparing the histopathology and immunohistochemistry of human skin biopsies for cutaneous leishmaniasis diagnosis, found 16% positivity by direct examination of skin scrapings from cutaneous lesions, 20% by histopathological evaluation and 64.5% by immunohistochemical evaluation, thus demonstrating that the last method presented far greater sensitivity than the others.

Present data on parasite identification by HE or immunohistochemical staining of paraffin-embedded tissue sections indicate that popliteal lymph nodes were the most suitable for a clearer etiological diagnosis of CanL, among the organs tested. Having established this, aspirates of popliteal lymph nodes from naturally infected dogs were used as a target to test additional methodologies, studied with the aim of facilitating and accelerating disease diagnosis.

Direct parasite search by cytological analysis of lymph node smears was more sensitive in the symptomatic group, possibly because in this case the immune response triggered by infection may not have been sufficient to control parasite burden, as mentioned by Ferrer (1999) and Pinelli et al. (1999), thus facilitating detection due to the large number of intact parasites displayed in the tissue. In contrast, the lower sensitivity indexes found for this technique in the asymptomatic and oligosymptomatic groups, may reflect a large destruction of amastigote forms as a consequence of a more effective immune response (Pinelli et al., 1999).

Direct immunofluorescence evaluation of lymph node smears resulted in sensitivity values of 92.68, 73.91 and 60.00% for the symptomatic, oligosymptomatic and asymptomatic clinical groups, respectively, thus indicating improved diagnostic performance when compared with direct cytological evaluation. This was also observed by Moreira et al. (2002) in a comparative study of lymph node aspirates from dogs with negative, suspected or positive CanL diagnosis; and by Sotto et al. (1989) in tissue samples from patients with cutaneous leishmaniasis.

In the present study, immunohistochemistry proved to be highly efficient at revealing the presence of intact parasites in lymph node smears, as it gave positivity indexes of 100, 92.98 and 76.00% in the asymptomatic,

symptomatic and oligosymptomatic groups, respectively, with 100% specificity. Not only was its overall sensitivity high, but it specifically allowed for 100% correct diagnosis of asymptomatic dogs and should, therefore, be considered an important tool for inclusion in routine diagnostic practices. According to Ferrer (1999) and Gradoni (2002), the ideal diagnostic method for CanL should be low-cost, fast, and show high sensitivity and specificity ratios. Although immunohistochemistry is not considered a low-cost assay and requires considerable time to perform, its excellent diagnostic performance both in terms of specificity and sensitivity is a sound argument to grant its use as a routine diagnostic assay.

PCR applied to lymph node aspirates presented sensitivity indexes of 100, 96 and 95.65% in the symptomatic, oligosymptomatic and asymptomatic groups, respectively. This method did not show significant sensitivity differences between the clinical groups of dogs from the Araçatuba (SP) region, where CanL is endemic. Ashford et al. (1995) reported 100% sensitivity for PCR in dogs diagnosed by positive parasite culture, as did Reale et al. (1999), in a group of dogs that were serum-positive and -negative for CanL. These data might suggest that PCR should be considered a golden diagnostic test. However, according to the study performed by Berrahal et al. (1996) in Marseille, France, which is a CanL endemic region, the detection of *Leishmania* DNA in skin samples by PCR was efficient in 89% dogs with clinical and biological signs of the disease, in 63% with a history of leishmaniasis and diagnosed as clinically cured after treatment and in 80% of asymptomatic dogs, of which 56% were serum-positive for anti-*Leishmania* antibodies by immunoblotting. The primers described by Rodgers et al. (1990) and synthesized for the present analysis amplify regions of kinetoplast DNA that are considered efficient for the characterization of the *Leishmania* genus, as they contain multiple copies of minicircles common to all *Leishmania* species. High PCR sensitivity when amplifying *Leishmania* kinetoplast DNA was mentioned by Lachaud et al. (2002) in their work on symptomatic and asymptomatic dogs.

The comparative analysis of the diagnostic performance of cytological evaluation, direct immunofluorescence (DIF), immunocytochemistry (ICC) and PCR applied to lymph node aspirate showed that parasite detection by direct cytological examination, despite being a fast, low-cost method that does not require sophisticated equipment, presented low sensitivity. Greater sensitivity indexes were obtained with the immunolabeling methods DIF and ICC, especially with the latter (Sotto et al., 1989; Ferrer et al., 1988; Moreira et al., 2002). The best sensitivity results were obtained with PCR, showing that it is a very efficient method for CanL diagnosis. However, this test requires sophisticated equipment and well-trained laboratory personnel, particularly in order to avoid sample contamination, since this technique is able to detect small amounts of parasite DNA (Roura et al., 1999). Additionally, this method detects amplified parasite DNA and not the intact parasite and does not reflect the severity of the infection nor the disease stage.

Acknowledgements

This work was supported by LIM50-HCFMUSP, UNESP, FAPESP 00/10430-2 and 00/02768-3.

References

Ashford, D.A., Bozz, M., Freire, M., 1995. Comparison of the polymerase chain reaction and serology for the detection of canine visceral leishmaniasis. Am. J. Trop. Med. Hyg. 50, 251–255.

Azedeh, B., Sells, P.G., Ejeckam, G.C., Rampling, D., 1994. Localized *Leishmania* lymphadenitis. Immunohistochemical studies. Am. J. Clin. Pathol. 102, 11–15.

Berrahal, F., Mary, C., Roze, M., Berenger, A., Escoffier, K., Lamouroux, D., Dunan, S., 1996. Canine leishmaniasis: Identification of asymptomatic carriers by polymerase chain reaction and immunoblotting. Am. J. Trop. Med. Hyg. 55, 273–277.

Costa, C.A., Genaro, O., Lana, M., Magalhães, P.A., Dias, M., Michalick, S.M., Melo, M.N., Costa, R.T., Magalhães Rocha, N.M., Mayrink, W., 1991. Leishmaniose visceral canina: avaliação da metodologia sorológica utilizada em inquéritos epidemiológicos. Rev. Soc. Bras. Med. Trop. 24, 21–25.

Deane, L.M., Deane, M.P., 1955a. Leishmaniose visceral urbana (no cão e no homem) em Sobral Ceará, 1955. O Hosp. 47, 75–87.

Deane, L.M., Deane, M.P., 1955b. Observações preliminares sobre a importância comparativa do homem, do cão e da raposa (*Lycalopex vetulus*) como reservatório da *Leishmania donovani* em área endemica de calazar, no Ceará. O Hosp. 48, 1–76.

Duarte, M.I.S., Mariano, O.N., Corbett, C.E.P., 1989. Liver parenchimal cell parasitism in human visceral leishmaniasis. Virchows Arch. A: Pathol. Anat. 415, 1–6.

Evans, T.G., Vasconcelos, I.A.B., Lima, J.W., Teixeira, J.M., McAullife, I.T., Lopes, U.G., Pearson, R.D., Vasconcelos, A.W., 1990. Canine visceral leishmamasis in northeast Brazil: assessment of serodiagnostíc methods. Am. J. Trop. Med. Hyg. 42, 118–123.

Ferrer, L., Rabanal, R., Fondevila, D., Ramos, J.A., Domingo, M., 1988. Skin-lesions in canine leishmaniasis. J. Small Anim. Pract. 29, 381–388.

Ferrer, L.M., 1999. Clinical aspects of canine leishmaniasis. Canine leishmaniasis: an update. In: Proceeding of the International Canine Leishmaniasis Forum, Barcelona, Spain, pp. 6–10.

Feitosa, M.M., Ikeda, F.A., Luvizotto, M.C.R., Perri, S.H.V., 2000. Aspectos clínicos de cães com leishmaniose visceral no município de Araçatuba – São Paulo (Brasil). Clin. Vet. 28, 36–44.

Gradoni, L., 2002. The diagnosis of canine leishmaniasis. In: Proceedings of the Second International Canine Leishmaniasis Forum, Sevilla, Spain, pp. 7–14.

Grimaldi Jr., G., Tesh, R.B., 1993. Leishmaniasis of the New World: current concepts and implications for future research. Clin. Microbiol. Rev. 6, 230–250.

Harris, E., Kropp, G., Belli, A., Rodriguez, B., Agabian, N., 1998. Single-step multiplex PCR assay for characterization of New World *Leishmania* complexes. J. Clin. Microb. 36, 1989–1995.

Keenan, C.M., Hendricks, L.D., Lightner, L., Johnson, A.J., 1984. Visceral leishmaniasis in the German Shepherd dog. II. Pathology. Vet. Pathol. 21, 80–86.

Lachaud, L., Marchergui-Hammami, S., Chabbert, E., Dereure, J., Dedet, J.P., Bastien, P., 2002. Comparason of six PCR methods using peripherical blood for detection of canine visceral leishmaniasis. J. Clin. Microbiol. 40, 210–215.

Laison, R., Shaw, J.J., 1987. Ecology and epidemiology: New World. In: Peters, W., Killick-Kendrick, R. (Eds.), The leishmaniasis in biology and medicine, vol. 1. Biology and Epidemiology. Academic Press Inc., London, pp. 291–363.

Lanotte, G., Rioux, J.A., Perieres, J., Volhardt, J., 1979. Ecologie des leishmaniose viscerale canine. Elaboration d'une typologie bioclinique a finalite epidemiologique. Ann. Parasitol. Hum. Comp. 54, 277–295.

Mancianti, F., Gramiccia, M., Gradoni, L., Pieri, S., 1988. Studies on canine control. 1. Evolution of infection of different clinical forms of canine leishmaniasis following antimonial treatment. Trans. R. Soc. Trop. Med. Hyg. 82, 566–567.

Mancianti, F., Falcone, M.L., Giannelli, C., Polli, A., 1995. Comparison between an enzyme-linked immunosorbent assay using a detergent-soluble *Leishmania infantum* antigen and indirect immunofluorescence for the diagnosis of canine leishmaniosis. Vet. Parasitol. 59, 13–21.

Moreira, M.A.B., Luvizotto, M.C.R., Nunes, C.M., Silva, T.C.C., Laurenti, M.D., Corbett, C.E.P., 2002. Application of direct immunofluorescence technic for the diagnosis of canine visceral leishmaniasis in lymph nodes aspirate. Braz. J. Vet. Res. Anim. Sci. 39, 103–106.

Mukerji, K., Pal, A., Basu, D., Naskar, K., Mallick, K.K., Ghosh, D.K., 1991. Direct enzyme-linked immunosorbent assay: a simple immunoassay using *Leishmania donovani* promastigote for diagnosis of kala-azar. J. Clin. Lab. Anal. 5, 299–301.

Paranhos-Silva, M., Freitas, L.A.R., Santos, W.C., Grimaldi Jr., G., Potes de Carvalho, L.C., Oliveira dos Santos, A.J., 1996. Across-sectional serodiagnostic survey of canine leishmaniasis due to *Leishmama chagasi*. Am. J. Trop. Med. Hyg. 55, 39–44.

Pinelli, E., Killick-Kedrick, R., Wagenaar, J., Bernardina, W., Del Real, G., Ruitenberg, E.J., 1994. Cellular and humoral immune response in dogs experimentally and naturally infected with *Leishmania infantum*. Infect. Immun. 62, 229–335.

Pinelli, E., Rutten, V.P.M.G., Ruitenberg, E.J., 1999. Cellular immune responses in canine leishmaniasis. In: Proceedings of the International Canine Leishmaniosis, Barcelona, Spain, pp. 60–64.

Ramos, C.C., Duarte, M.I.S., Ramos, A.M., 1994. Fatal visceral leishmaniasis associated with acquired imnmnodeficiency syndrome: report of a case with necropsy findings and immunohistochemical study. Rev. Soc. Bras. Med. Trop. 27, 245–250.

Reale, S., Maxia, L., Vitale, F., Glorioso, N.S., Caracappa, S., Vesco, G., 1999. Detection of *Leishmania infantum* in dogs by PCR with lymph node aspirates and blood. J. Clin. Microbiol. 37, 293–295.

Riera, C., Valladares, J.E., Gallego, M., Aisa, M.J., Castillejo, S., Fisa, R., Ribas, N., Carrió, J., Alberola, J., Arboix, M., 1999. Serological and parasitological follow-up in dogs experimentally infected with *Leishmania infantum* and treated with meglumine antimoniate. Vet. Parasitol. 84, 33–47.

Rodgers, M.R., Popper, S.J., Wirth, D.F., 1990. Amplification of kinetoplast DNA as a tool in the detection diagnosis of *Leishmania*. Exp. Parasitol. 71, 267–275.

Roura, X., Sanchez, A., Ferrer, L., 1999. Diagnosis of canine leishmaniasis by a polymerase chain reaction technique. Vet. Rec. 144, 262–264.

Santos, S.O., Arias, J., Ribeiro, A.A., Hoffmann, M.P., Freitas, R.A., Malacco, M.A.F., 1998. Incrimination of *Lutzomyia cruzi* as a vector of American Visceral Leishmaniasis. Med. Vet. Ent. 12, 315–317.

Slappendel, R.J., 1988. Canine leishmaniasis. A review based on 95 cases in The Netherlands. Vet. Q. 10, 1–16.

Sotto, M.N., Yamashiro-Kanashiro, E.H., Matta, V.L.R., Brito, T., 1989. Cutaneous leishmamasis of the New World: diagnostic immunopathology and antigen pathways in skin and mucosa. Acta Trop. 46, 121–130.

Tafuri, W.L., Tafuri, W.L., Barbosa, A.J.A., Michalick, M.S.M., Genaro, O., França-Silva, J.C., Mayrink, W., Nascimento, E., 1996. Histopathology and immunocytochemical study of type 3 and type 4 complement receptors in the liver and spleen of dogs naturally and experimentally infected with *Leishmania* (*Leishmania*) *chagasi*. Rev. Inst. Med. Trop. São Paulo 38, 81–89.

Vexenat, J.A., Fonseca de Castro, J.A., Cavalcate, R., da Silva, M.R., Batista, W.H., Campos, J.H., Pereira, F.C., Tavares, J.P., Miles, M.A., 1993. Preliminary observations on the diagnosis and transmissibility of canine visceral leishmaniasis, n.e., Brazil. Arch. Inst. Pasteur Tunis. 70, 467–472.

Voller, A., Bidwell, D.E., Bartlett, A., 1980. Enzyme immunoasorbent assay. In: Rose, N.R., Friedman, H. (Eds.), Manual of Clinical Immunology. second ed. American Society for Microbiology, Washington, pp. 359–371.

Yamamoto, Y.I., Nunes, V.L.B., Junior, F.A.R., Oshiro, E.T., Dorval, M.E.M.C., 1988. Estudo da eficiência das reações de imunofluorescência e de hemaglutinação passiva no diagnóstico da leishmaniose visceral em cães. Rev. Fac. Med. Vet. Zootec. Univ. Sao Paulo 25, 143–152.

ANEXO-27

Aplicação da técnica de imunofluorescência direta para o diagnóstico da leishmaniose visceral canina em aspirado de linfonodo

Moreira, M.A.B.; Luvizotto, M.C.R.; Nunes, C.M.; Silva, T.C. C.; **Laurenti, M.D.;** Corbett, C.E.P.

Brazilian Journal of Veterinary Research and Animal Science 2002; 39(2): 103-106

Braz. J. vet. Res.anim.Sci.,
São Paulo, v. 39, n. 2, p. 103-106, 2002.

Aplicação da técnica de imunofluorescência direta para o diagnóstico da leishmaniose visceral canina em aspirado de linfonodo

Application of direct immunofluorescence technic for the diagnosis of canine visceral leishmaniasis in lymph nodes aspirate

CORRESPONDÊNCIA PARA:
MÁRCIA DALASTRA LAURENTI
Departamento de Patologia
Faculdade de Medicina da USP
Av. Dr. Arnaldo, 455 - Cerqueira César
1º andar – sala 1209
01246-903 – São Paulo – SP
e-mail: mdlauren@usp.br

1- Laboratório de Patologia do Departamento de Clínica, Cirurgia e Reprodução Animal do Curso de Medicina Veterinária da UNESP, Araçatuba - SP
2- Laboratório de Patologia de Moléstias Infecciosas (LIM-50) do Departamento de Patologia da Faculdade de Medicina da USP, São Paulo – SP

Marcio Antônio Batistela MOREIRA[1]; Maria Cecília Rui LUVIZOTTO[1]; Cáris Marone NUNES[1]; Tereza Cristina Cardoso da SILVA[1]; Márcia Dalastra LAURENTI[2]; Carlos Eduardo Pereira CORBETT[2]

RESUMO

Recentemente, foco de leishmaniose visceral canina (CVL) foi descrito na região noroeste do Estado de São Paulo - Brasil. O Hospital Veterinário - UNESP - Araçatuba, no ano de 2.000, desenvolveu 60 testes citopatológicos de casos suspeitos de leishmaniose usando aspirado por agulha fina (FNA). Os esfregaços de linfonodo foram corados pelo método de Romanowsky (Diff-Quik®) e observados em microscopia de luz. Os casos positivos mostraram formas amastigotas típicas de Leishmania livres ou em vacúolos de macrófagos. Sinais citopatológicos de reatividade do sistema linfo-histiocitário com ausência de parasitos foram também observados. Com o objetivo de implementar o diagnóstico da CVL, detectando parasitos e material antigênico nos esfregaços, aplicou-se a reação de imunofluorescência direta (IFD) usando anticorpo policlonal anti-Leishmania produzido em camundongo. Comparamos o método de IFD com a pesquisa direta do parasito em esfregaços corados pelo método de Romanowsky. Dos 60 cães com sinais clínicos da doença, o exame direto foi positivo em 50% (n=30), duvidoso em 36,7% (n=22) e negativo com reatividade do linfonodo em 13,3% (n=8). Quando os linfonodos foram submetidos a reação de IFD observamos reação positiva em 93,3% (n=56) e reação negativa em 6,7% (n=4). Nossos resultados mostraram que a reação de IFD apresentou alta sensibilidade quando comparada a pesquisa direta do parasito pela coloração de Romanowsky. A reação de IFD pode ser um método útil para confirmar os casos duvidosos da doença, onde as formas amastigotas não são identificadas com facilidade.

PALAVRAS-CHAVE: Imunofluorescência. Leishmaniose visceral. Linfonodos de animal. Cães.

INTRODUÇÃO

A leishmaniose visceral é uma importante endemia brasileira causada pela Leishmania (Leishmania) chagasi. É transmitida ao homem por picada do mosquito Lutzomyia longipalpis, e tem como reservatório canídeos silvestres e domésticos.

O diagnóstico indireto da doença, como a pesquisa de anticorpos em soro, tem sido bastante empregado em inquéritos epidemiológicos e pode ser feito por diferentes métodos como o de imunofluorescência indireta[8,12,14], ELISA[8,9,11,14], aglutinação direta[4,5] e fixação do complemento [3,5]. Dentre os métodos utilizados no diagnóstico etiológico da leishmaniose visceral canina (LVC), a identificação microscópica dos parasitos em esfregaços obtidos por punção de linfonodo, baço e medula óssea constitui-se num método eletivo, podendo-se utilizar o cultivo deste material em diferentes meios de cultura para isolamento dos parasitos[6]. A reação em cadeia pela polimerase (PCR) tem sido recentemente utilizada como um método de alta especificidade e sensibilidade na identificação de DNA parasitário em tecidos e fluidos provenientes de casos humanos e caninos[1].

O diagnóstico da LVC realizado a partir de esfregaços de punção de linfonodo poplíteo corados pelo método de Romanowsky (Diff-Quik®), tem mostrado, nos casos tipicamente positivos, a presença de formas amastigotas de Leishmania livres ou dentro de vacúolos de macrófagos com identificação bem definida de núcleo e cinetoplasto do parasito. Porém, em alguns casos observa-se sinais citopatológicos de reatividade do sistema linfo-histiocitário com ausência de formas amastigotas típicas. Com o objetivo de aprimorar o diagnóstico da LVC em regiões endêmicas, aplicamos o método de imunofluorescência direta para a pesquisa de parasitos e seus produtos antigênicos nos esfregaços de biópsia aspirativa de linfonodos de cães com sinais clínicos da doença.

MATERIAIS E MÉTODOS

Amostras biológicas

As amostras biológicas foram provenientes de cães atendidos no Hospital Veterinário do Curso de Medicina Veterinária da UNESP, Araçatuba no ano de 2000. Os animais foram examinados clinicamente e aqueles com suspeita de LVC foram submetidos à punção aspirativa com agulha fina (PAAF) de linfonodo poplíteo. Foram colhidas 60 amostras, das quais, esfregaços pareados em lâminas de vidros eram submetidos à coloração de Romanowsky (Diff-Quik®) e fixados em álcool/éter volume a volume para a reação de imunofluorescência direta.

Preparo do conjugado

Camundongos BALB/c foram inoculados com 10^7 formas promastigotas de Leishmania amazonensis (cepa HSJD-1) pela via subcutânea de inoculação. Após 60 a 90 dias de infecção, quando os animais já mostravam sinais clínicos da doença, caracterizados por lesões infiltrativas no coxim plantar traseiro, o sangue foi colhido através de punção do seio retro-orbitário para obtenção de soro imune. O título de anticorpos reagentes para antígenos de Leishmania neste soro imune foi testado por imunofluorescência indireta (IFD) utilizando-se anti-imunoglobulina de camundongo conjugada a fluoresceína (SIGMA, nº cat. F-8646) na diluição de 1/20, e resultou em um título reagente de 128. Este soro imune foi posteriormente conjugado com fluoresceína de acordo com Camargo[2] e estocado até o uso em freezer –20°C.

Reação de Imunofluorescência Direta

O anticorpo anti-Leishmania após conjugação com a fluoresceína foi titulado para a reação de imunofluorescência direta utilizando-se lâminas preparadas com promastigotas de *L. chagasi* e resultou em um tilulo reagente de 200.

Os esfregaços de linfonodo fixados em álcool/éter por 30 minutos foram incubados com o anticorpo policlonal anti-Leishmania na diluição de 1/200 em Azul de Evans a 37°C por 60 minutos em câmara úmida. Após o período de incubação as lâminas foram lavadas com PBS 0,01M pH 7,2 por 10 minutos com três trocas, montadas com lamínulas utilizando-se glicerina tamponada com carbonato-bicarbonato de sódio pH 9,0 e observadas em microscópio de fluorescência (ZEISS). Como controle positivo da reação foi utilizado esfregaço de linfonodo de cão que apresentava grande quantidade de parasitos nos esfregaços corados pelo Romanowsky (Diff-Quik®) e lâminas preparadas com promastigotas de L. (L.) chagasi. Como controle negativo, utilizaram-se esfregaços de linfonodo de cães sadios de área sem ocorrência de LVC.

RESULTADOS

Do total das amostras de punção de linfonodos corados pelo método de Romanowsky (Diff-Quik®) e

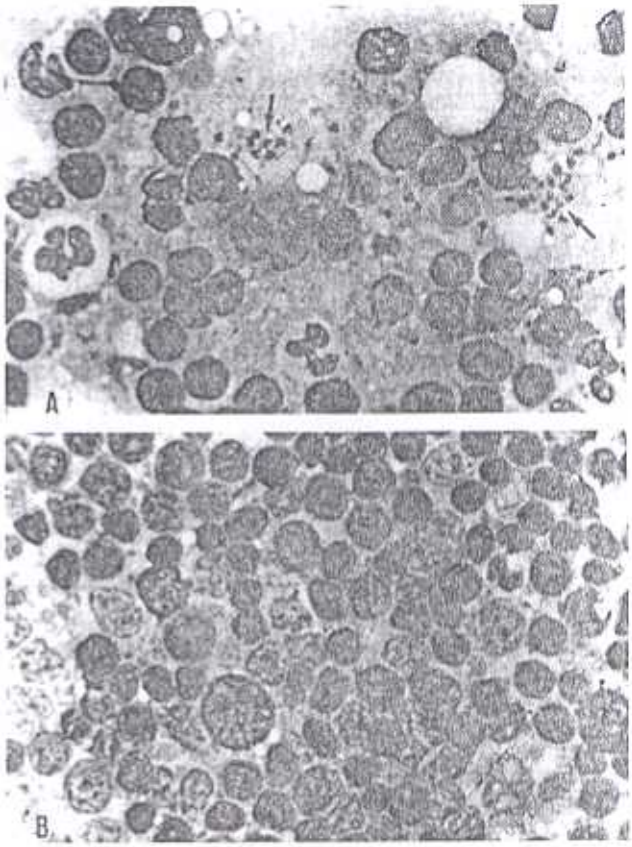

Figura 1
Esfregaço de aspirado de linfonodo poplíteo de cão com suspeita clínica de leishmaniose visceral. A – Presença de linfócitos, macrófagos, poucos neutrófilos e inúmeras formas amastigotas do parasito. B – Presença de células mononucleares, linfócitos, macrófagos e plasmócitos sem evidência de formas amastigotas do parasito (Método de Romanowsky - A.O. 100X).



Figura 2
Esfregaço de aspirado de linfonodo poplíteo de cão com suspeita clínica de leishmaniose visceral, e com diagnóstico não confirmados pelo método de Romanowsky. Presença de formas amastigotas do parasito positivas para o anticorpo policlonal anti-Leishmania conjugado a fluoresceína (IFD - A.O. 63X).

Tabela 1

Distribuição de resultados, em número absoluto e porcentagem, de 60 esfregaços de aspirado de linfonodo poplíteo de cães com suspeita clínica de leishmaniose visceral no município de Araçatuba (SP) no ano de 2000, de acordo com o método de Romanowsky (Diff-Quik®) e a imunomarcação utilizando-se anticorpo policlonal anti-Leishmania conjugado a fluoresceína pelo método de imunofluorescência direta (IFD).

Metodologia \ Número de casos	Positivo	Suspeito	Negativo	Total
Romanowsky	30 (50%)	22 (36,7%)	8 (13,3%)	60 (100%)
IFD	56 (93,3%)	0 (0%)	4 (6,7%)	60 (100%)

examinados em microscopia de luz convencional para a pesquisa de formas amastigotas de Leishmania, 50% mostraram positividade (30/60) (Fig. 1A). Nestes casos foi possível observar formas amastigotas típicas medindo aproximadamente 5 mm, com núcleo e cinetoplasto característicos. O diagnóstico suspeito da doença foi atribuído a 22 amostras (36,7%), as quais mostraram macrófagos vacuolizados, proliferação linfoblástica, plasmocitose moderada e muitas vezes a presença de eosinófilos, sem no entanto, serem observadas formas amastigotas típicas do parasito (Fig. 1B). Oito casos (13,4%) apresentaram discreta reação linfocitária sem parasitismo, portanto, foram considerados negativos para leishmaniose. O método de imunofluorescência direta (IFD) mostrou positividade em 56 amostras (93,3%), com a observação de estruturas elípticas fluorescentes e a presença de cinetoplasto visível em alguns casos (Fig. 2). Em 4 casos (6,7%) a reação de imunofluorescência foi negativa (Tab. 1).

DISCUSSÃO

No presente estudo, os esfregaços de punção de linfonodo poplíteo de cães com suspeita clínica de leishmaniose visceral foram primeiramente examinados em microscopia de luz e em seguida em microscopia de fluorescência. Ao diagnóstico citopatológico encontraram-se formas amastigotas típicas do parasito em 50% dos casos, sendo que esta metodologia foi realizado de modo rápido e mostrou alta especificidade. As amostras em que foram observadas reação celular pronunciada, com macrófagos e linfócitos, sem a presença evidente de formas amastigotas, resultaram em diagnóstico suspeito de LVC, pois mesmo sem a presença de formas amastigotas típicas a reação celular encontrada é característica da doença[10]. Somente para as amostras em que foram observadas reatividade discreta e nenhuma estrutura sugestiva de formas amastigotas é que foi atribuído o diagnóstico de linfonodo reativo e negativo para leishmaniose. Desta maneira, 50% dos casos foram considerados positivos, 36,7% suspeitos e 13,3% receberam o diagnóstico de linfonodo reativo e negativo para leishmaniose, de acordo com o exame direto nos esfregaços citológicos corado pelo Romanowsky. Quando estas amostras foram submetidas ao método de IFD, observou-se um maior índice de positividade (93,36%) com a presença de pontilhados e formas elípticas fluorescentes, sendo que em algumas amostras foi possível a observação de estruturas intracelulares do parasito como o cinetoplasto. Essas estavam em maior freqüência livres pelo esfregaço, entretanto, próximo as células linfóides e raramente no interior de células fagocíticas. Em 6,7% (4/60) dos casos observou-se reação totalmente negativa sem nenhuma estrutura fluorescente.

A pesquisa direta positiva de parasitos em lesão de pele e em vísceras tem sido considerada como diagnóstico de certeza para a leishmaniose tegumentar e visceral, respectivamente. Na leishmaniose visceral canina, a pesquisa direta de parasitos pelo método de Romanowsky em punção aspirativa de linfonodo tem sido utilizada com relativa eficiência[7], porém não há relatos no que se refere à pesquisa do parasito por técnicas de imunomarcação. Em 40 biópsias de pacientes com lesão cutânea causada pela LTA, 20% apresentaram pesquisa positiva do parasito por técnicas de rotina histopatológicas (H&E), enquanto que 64,51% por imunoperoxidase e 89,28%por imunofluorescência indireta. Estes resultados mostram maior índice de positividade para a pesquisa de parasitos quando utilizados métodos de imunomarcação, sendo a imunofluorescência de maior sensibilidade quando comparada à imunoperoxidase[13].

Nossos resultados mostraram que o método de imunofluorescência direta (IFD) apresentou maior sensibilidade quando comparado a pesquisa direta do parasito pela coloração de Romanowsky. Desta forma, o método de IFD deve ser utilizado para confirmação dos casos suspeitos de leishmaniose visceral canina em regiões endêmicas, onde o encontro de formas amastigotas do parasito pode não ser freqüente, face ao sensível incremento de sensibilidade quando comparado ao exame microscópico de rotina.

MOREIRA, M.A.B.; LUVIZOTTO, M.C.R.; NUNES, C.M.; SILVA, T.C.C.; LAURENTI, M.D.; CORBETT, C.E.P. Aplicação da técnica de imunofluorescência direta para o diagnóstico da leishmaniose visceral canina em aspirado de linfonodo. **Braz. J. vet. Res. anim. Sci.**, São Paulo, v.39, n.2, p. 103-106, 2002.

SUMMARY

Recently, canine visceral leishmaniasis (CVL) was detected in the northwest of São Paulo State - Brazil. The Veterinary Hospital - UNESP - Araçatuba, in 2.000, carried out 60 cytopathological test of suspected cases of leishmaniasis using the fine-needle aspiration (FNA). The smears of the FNA popliteal lymph nodes were stained by the Romanowsky stain (Diff-Quik®) and observed using a light microscope. The positive cases showed typical amastigotes forms of Leishmania either free or in macrophage vacuoles. Cytopathological signs of reactivity of the lymph-hystiocitary system with the absence of parasites were also detected. In order to improve the diagnosis of CVL, looking for parasites and antigenic material detection in smears, we standardized the direct immunofluorescence assay (IFD) using mouse anti-Leishmania policlonal antibodies. We compared the IFD assay with the direct search of parasites in smears stained by Romanowsky stain. From the 60 dogs with clinical signs of the disease, the direct exam was positive in 50% (n=30), uncertain in 36,7% (n=22) and negative with lymph node reativity in 13,3% (n=8). When the lymph node smears were submitted to IFD assay we observed positive reaction in 93,3% (n=56) and negative reaction in 6,7% (n=4). Our results showed that IFD assay presented a high sensibility compared to parasite direct search by Romanowsky stain. The IFD assay could be useful method to confirm the uncertain cases of the disease, where amastigotes forms were not clearly identified.

KEY-WORDS: Immunofluorescence. Visceral leishmaniasis. Lymph nodes. Dogs.

REFERÊNCIAS

1- AVILES, H.; BELLI, A.; ARMIJOS, R.; MONROY, F. P.; HARRIS, E. PCR detection and identification of Leishmania parasites in clinical specimes in Ecuador: A comparison with classical diagnostic methods. **Journal of Parasitology**, v. 85, n. 2, p. 181-187, 1999.

2- CAMARGO, M. **Introdução às técnicas de imunofluorescência**. São Paulo: Instituto de Medicina Tropical de São Paulo, 1973. Apostila.

3 - COSTA, C. A.; GENARO, O.; LANA, M.; MAGALHÃES, P. A.; DIAS, M.; MICHALICK, S. M.; MELO, M. N.; COSTA, R. T.; MAGALHÃES ROCHA, N. M.; MYRINK, W. Leishmaniose visceral canina: avaliação da metodologia sorológica utilizada em inquéritos epidemiológicos. **Revista da Sociedade Brasileira de Medicina Tropical**, v. 24, n. 1, p. 21-25, 1991.

4 - DE KORTE, P. M.; HARITH, A. E.; DEREURE, J.; HUIGEN, E.; FAUCHERRE, V.; VAN DER KAAY, H. J. Introduction of an improved direct agglutination test for the detection of Leishmania infantum infection in southern France. **Parasitology Research**, v. 76, n. 6, p. 526-530, 1990.

5 - HARITH, A.; SLAPPENDEL, R. J.; REITER, I.; VAN KNAPEN, F.; DE KORTE, P.; HUIGEN, E.; KOLK, A. H. Application of a direct agglutination test for detection of specific anti-Leishmania antibodies in the canine reservoir. **Journal of Clinical Microbiology**, v. 27, n. 10, p. 2252-2257, 1989.

6 - HERWALDT, B. L. Leishmaniasis. **The Lancet**, v. 354, n. 9185, p. 1191-1199, 1999.

7 - LUVIZOTTO, M. C. R.; MOREIRA, M. A. B.; FEITOSA, M. M.; IKEDA, F. Cytopathologic analysis of fine-needle aspiration biopsy of lymph node in dogs with visceral leishmaniasis in evolutive stage of the disease: clinical and pathological correlation. **Memórias do Instituto Oswaldo Cruz, Rio de Janeiro**, v. 95, p. 141-142, 2000. Supplement II.

8 - MILLESIMO, M.; ZUCCA, M.; CARAMELLO, P.; SAVOIA, D. Evaluation of the immune response in visceral leishmaniasis. **Diagnostic microbiology and infectious diseases**, v. 26, n. 1, p. 7-11, 1996.

9 - MUKERJI, K.; PAL, A.; BASU, D.; NASKAR, K.; MALLICK, K. K.; GHOSH, D. K. Direct enzyme-linked immunosorbent assay: a simple immunoassay using Leishmania donovani promastigote for diagnosis of kala-azar. **Journal of Clinical Laboratory Analysis**, v. 5, n. 4, p. 299-301, 1991.

10 - PAIVA, M. C.; ANDRADE, H. M.; COSTA-VAL, A. P.; CARNEIRO, C. M.; CHIARELLI, I. M.; TAFURI, W. L. Some clinical and histopathological aspects of dogs naturally infected with Leishmania (Leishmania) chagasi in Belo Horizonte, MG, Brazil. **Memórias do Instituto Oswaldo Cruz, Rio de Janeiro**, v. 93, p. 276-277, 1998. Supplement II.

11 - RACHAMIM, N.; JAFFE, C. L.; ABRANCHES, P.; SILVA PEREIRA, M. C.; SCHNUR, L. F.; JACOBSON, R. L. Serodiagnosis of canine visceral leishmaniasis in Portugal: Comparison of three methods. **Annals of tropical medicine and parasitology**, v. 85, n. 5, p. 503-508, 1991.

12 - SOLEIMANZADEH, G.; EDRISSIAN, G. H.; MOVAHHED-DANESH, A. M.; NADIM, A. Epidemiological aspects of kala-azar in Meshkin-Shahr, Iran: human infection. **Bulletin of the world health organization**, v. 71, n. 6, p. 759-762, 1993.

13 – SOTTO, M. N.; YAMASHIRO KANASHIRO, E. H.; DA MATTA, V. L. R.; DE BRITO, T. Cutaneous leishmaniasis of the New World: Diagnostic, immunopathology and antigen pathway in skin and mucosa. **Acta Tropica**, v. 46, n. 2, p. 121-130, 1989.

14 - VEXENAT, J. A.; FONSECA DE CASTRO, J. A.; CAVALCANTE, R.; DA SILVA, M. R.; BATISTA, W. H.; CAMPOS, J. H.; PEREIRA, F. C.; TAVARES, J. P.; MILES, M. A. Preliminary observations on the diagnosis and transmissibility of canine visceral leishmaniasis in Teresina, Brazil. **Archives de Institut Pasteur de Tunis**, v. 70, n. 3-4, p. 467-472, 1993.

Recebido para publicação: 03/09/2001
Aprovado para publicação: 27/02/2002

ANEXO-28

Canine visceral leishmaniasis: Performance of a rapid diagnostic test (Kalazar Detect^{TM}) in dogs with and without signs of the desease.

Lemos, E.M.; **Laurenti, M.D.;** Moreira, M.A.B.; Reis, A.B.; Giunchetti, R.C.; Raychaudhuri, S.; Dietze, R.

Acta Tropica 2008; 107: 205-207

Acta Tropica 107 (2008) 205–207

Contents lists available at ScienceDirect

Acta Tropica

journal homepage: www.elsevier.com/locate/actatropica

Short communication

Canine visceral leishmaniasis: Performance of a rapid diagnostic test (Kalazar Detect™) in dogs with and without signs of the disease

Elenice Moreira Lemos[a], Márcia Dalastra Laurenti[b], Márcio Antônio Batistela Moreira[b], Alexandre Barbosa Reis[c], Rodolfo Cordeiro Giunchetti[c], Syamal Raychaudhuri[d], Reynaldo Dietze[a,*]

[a] Núcleo de Doenças Infecciosas, Universidade Federal do Espírito Santo, Vitória, ES, Brazil
[b] Laboratório de Patologia de Moléstias Infecciosas (LIM-50), Faculdade de Medicina, Universidade de São Paulo, São Paulo, SP, Brazil
[c] Laboratório de Imunopatologia, Universidade Federal de Ouro Preto, Ouro Preto, MG, Brazil
[d] Inbios International, Inc. Seattle, WA, USA

ARTICLE INFO

Article history:
Received 1 June 2007
Received in revised form 24 April 2008
Accepted 28 April 2008
Available online 3 May 2008

Keywords:
Canine visceral leishmaniasis
Leishmania chagasi
Diagnosis
Rapid test
rK39

ABSTRACT

Current visceral leishmaniasis (VL) control programs in Brazil include the infected dog elimination but, despite this strategy, the incidence of human VL is still increasing. One of the reasons is the long delay between sample collection, analysis, control implementation and the low sensitivity of diagnostic tests. Due to the high prevalence of asymptomatic dogs, the diagnosis of these animals is important considering their vector infection capacity. Hence, a rapid and accurate diagnosis of canine visceral leishmaniasis is essential for an efficient surveillance program. In this study we evaluated the performance of rK39 antigen in an immunochromatographic format to detect symptomatic and asymptomatic *Leishmania chagasi* infection in dogs and compared the results with those using a crude antigen ELISA. The sensitivity of rK39 dipstick and ELISA were 83% vs. 95%, respectively, while the specificity was both 100%. Our results also demonstrated that the dipstick test was able to detect infected dogs presenting different clinical forms.

1. Introduction

Leishmania (*Leishmania*) *chagasi* is the etiologic agent of visceral leishmaniasis (VL) in Brazil and dogs are the major domestic reservoirs of this protozoan disease (Deane and Deane, 1962). Due to its anthropozoonotic characteristic, the Brazilian VL control program emphasizes serologic surveys with elimination of seropositive dogs as an attempt to reduce human disease (Vieira and Coelho, 1998; Palatinik-de-Souza et al., 2001). In the past 5 years, more than two million dogs were screened and more than 160,000 seropositive dogs were eliminated. Despite this effort, the Ministry of Health has not been able to reduce the incidence of human disease to an acceptable level. One of the alleged reasons for that is the long delay between sample collection, sample analysis, and culling of infected dogs (as long as 80 days). In addition, the current diagnosis method adopted by the Ministry of Health as the gold standard for VL screening surveillance (immunofluorescence antibody test) lacks sensitivity and specificity, requires well trained lab technician, a fluorescent microscopy, and is labor-intensive and time-consuming. Hence, a rapid, sensitive and accurate diagnostic test would represent an essential tool in mass-screening survey for interventional programs.

A rapid immunochromatographic test for qualitative detection of anti-*Leishmania* antibodies has recently become available. This test is based on a recombinant *Leishmania* K39 antigen (rK39), a repetitive immunodominant epitope in a kinesin-related protein that is highly conserved among viscerotropic *Leishmania* species: *L.* (*L.*) *donovani*, *L.* (*L.*) *infantum* and *L.* (*L.*) *chagasi* (Burns et al., 1993). This dipstick test has been shown to be very sensitive and specific for human VL diagnosis (Sundar et al., 1998; Jelinik et al., 1999; Bern et al., 2000; Zijlstra et al., 2001; Carvalho et al., 2003) and there are also some publications using it for the diagnosis of VL in dogs (Mohebali et al., 2004; Otranto et al., 2004; Toz et al., 2004; Mettler et al., 2005). In Brazil there are only two publications about this issue with conflicting results and none of them included dogs in different stages of the disease: asymptomatic, oligosymptomatic and with full blown disease (Reithinger et al., 2002; Da Costa et al., 2003).

Symptomatic dogs usually produce high levels of specific antibodies which can be easily detected (Deplazes et al., 1995). However, the sensitivity of antibody detection is generally lower in early or in asymptomatic canine infections (Leontides et al., 2002).

* Corresponding author at: Núcleo de Doenças Infecciosas, Universidade Federal do Espírito Santo, Av. Marechal Campos 1468, Maruípe, Vitória, ES, CEP: 29040-091, Brazil. Tel.: +55 27 3335 7204; fax: +55 27 3335 7204.
E-mail address: rdietze@ndi.ufes.br (R. Dietze).

0001-706X/$ – see front matter © 2008 Elsevier B.V. All rights reserved.
doi:10.1016/j.actatropica.2008.04.023

Due to the high prevalence of asymptomatic dogs in endemic areas of VL, the diagnosis of these animals is very important considering their vector infectivity capacity (Molina et al., 1994; Guarga et al., 2000). Here in, we evaluated the performance of a commercially available rK39 dipstick test (Kalazar Detect™) for the detection of specific anti-*L.* (*L.*) *chagasi* antibodies in dogs with and without signs of VL. We also compared the results with those obtained by ELISA using crude antigen.

2. Materials and methods

2.1. Samples

Blood samples were taken from 76 infected dogs from two different VL endemic areas in Brazil, Araçatuba, São Paulo and Belo Horizonte, Minas Gerais. The diagnosis of VL was based on the presence of *Leishmania* amastigotes in bone marrow aspirates. Animals were classified clinically according to the presence/absence of signs of VL as follows: asymptomatic—without signs of disease; oligosymptomatic—with at most three clinical signs including opaque bristles, localized alopecia and moderate weight loss; symptomatic—with the following signs of disease: opaque bristles, severe weight loss, onychogriphosis, cutaneous lesions, apathy and keratoconjunctivitis (Mancianti et al., 1998). As controls, we tested serum from 33 clinically healthy animals from a non-endemic area. All control animals were also negative by both parasitological and serological methods (ELISA).

All procedures described in the present work were carried out in compliance with current Brazilian regulations relating to Experimental Biology and Medicine as described in the guidelines issued by the Colégio Brasileiro de Experimentação Animal (COBEA).

2.2. Kalazar Detect test

The Kalazar Detect™ (InBios International, Seattle, WA, USA) is an immunochromatographic qualitative antibody assay against *L.* (*L.*) *chagasi* rK39 antigen. Twenty microliters of serum mixed with two drops of buffer was placed on the pad of the dipstick. Following the manufacture's instructions, a test was positive when two bands, a control and a positive test bands, appeared within 10 min. The test was negative if only the control band appeared. The test is qualitative and the manufacturer indicates that a faint band should be considered positive. The result of a dipstick was considered not valid if the internal control was not stained. An investigator blinded to the dogs underlying disease evaluated all tests.

2.3. ELISA

L. (*L.*) *chagasi* (MHOM/BR/1070/BH46) parasites were cultivated in LIT medium supplemented with 10% fetal calf serum at 26 °C. The promastigotes pellet was collected by centrifugation, washed three times with phosphate-buffered saline (PBS) and lysed by freeze thawing. The parasite suspension was homogenized using a tissue grinder in an ice bath. The homogenized material was centrifuged at 10,000 × *g* for 20 min at 4 °C. The supernatant was collected and used as crude soluble antigen.

Briefly, MaxiSorp plates (Nalge Nunc Intl., USA) were coated with 10 mg/ml of *L.* (*L.*) *chagasi* crude antigen and held overnight at 4 °C. Plates were washed three times with PBS and blocked with 100 μl of PBS containing 10% fetal bovine serum (FBS) for 2 h at 37 °C. After washed three times, the serum samples diluted 1/80 in PBS-T containing 10% of FBS were added to wells and incubated for 3 h at room temperature. The well was washed three times and bound antibodies were detected using canine anti-IgG peroxidase conjugated (Sigma Co., USA) diluted 1/5000 after incubation, for 1 h at room temperature. Plates were then washed three times and incubated with *o*-phenylenediamine (OPD)–H_2o_2 in citrate buffer for 5 min. The reaction was stopped with 50 μl of 1 M H_2SO_4, and the optical density (OD) was read at 492 nm. Positive and negative controls sera were run in each plate to standardize the readings and plate variations. The cut-off point between negative and positive results was calculated as the mean of the negative controls plus 3 standard deviations.

Table 1
Performance of rK39 dipstick and ELISA using crude antigen in the diagnosis of canine visceral leishmaniasis

	CVL ($n = 76$)[a]	Controls ($n = 33$)[b]	Sensitivity (95% CI)	Specificity (95% CI)
rK39 dipstick				
Positive	63	00	83% (72.2–90.2)	100% (87.0–100)
Negative	13	33		
ELISA test				
Positive	72	00	95% (86.4–98.3)	100% (87.0–100)
Negative	04	33		

[a] Dogs with parasitological proven infection.
[b] Healthy dogs with both negative parasitological test and ELISA serology.

2.4. Statistical analysis

The sensitivity and specificity for each test were calculated by using the formulas: sensitivity = True positive/(True positive + False negative) × 100% and specificity = True negative/(True negative/False positive) × 100%. In addition, the degree of agreement between the evaluated tests was determined by calculating κ value. κ Value express the agreement beyond chance; a κ value of 0.60–0.80 represents substantial agreement, whereas κ value of >0.80 represents almost perfect agreement beyond chance (Altman, 1991).

3. Results

We compared the sensitivity of the rK39 dipstick and ELISA using crude antigen in two different scenarios: in the first one the sera of all positives dogs were tested regardless their clinical forms of the disease. The sensitivity was 83% and 95% for rK39 and ELISA, respectively (Table 1). The specificity for both tests was 100% and the agreement between the tests was high, demonstrated by a κ value of 0.81.

In the second scenario the sera was stratified according to the clinical forms of the disease (asymptomatic, oligosymptomatic and symptomatic). In this condition the ELISA presented higher sensitivity in all groups of animals compared to the dipstick. In the asymptomatic group the dipstick was able to detect 12 out of 16 (75%), whereas ELISA detected 15 out of 16 (94%). In the oligosymptomatic group, 15 and 16 out of 17 animals were positive in the dipstick (88%) and ELISA (94%) test, respectively. For symptomatic dogs, the dipstick detected 36 out of 43 animals (84%) and the ELISA detected 41 of out 43 dogs (95%) (Table 2).

In order to evaluate the rK39 dipstick cross-reactivity, it was also analyzed 25 sera from dogs presenting different parasitic diseases

Table 2
Performance of rK39 dipstick and ELISA in the diagnosis of canine visceral leishmaniasis according to the clinical forms of the disease

	Number of positive dogs/total (%)		
	Asymptomatic	Oligosymptomatic	Symptomatic
rK39 dipstick	12/16 (75%)	15/17 (88%)	36/43 (84%)
ELISA test	15/16 (94%)	16/17 (94%)	41/43 (95%)

such as cutaneous leishmaniasis (5), ehrlichiosis (3), toxoplasmosis (5) and Chagas disease (12). The rapid test showed cross-reactivity with ehrlichiosis (1 out of 3 sera) and Chagas disease (3 out of 12 sera) altering the specificity from 100% to 93%.

4. Discussion

In the present study we evaluated the performance of dipstick rK39 for diagnosis of dogs presenting different clinical forms of VL. Our results showed that the rK39 was able to detect 83% of VL dogs regardless the clinical form of the disease. These findings were similar to those obtained by Reithinger et al. (2002) which demonstrated that the sensitivity of rK39 dipstick varied from 72% to 77% in the VL diagnosis in dogs. However, Da Costa et al. (2003) described a better performance of rK39 test showing a sensitivity of 96%.

Concerning the different clinical forms, the ELISA presented a higher sensitivity to detect VL dogs despite the presence of symptoms. On the other hand, the dipstick showed lower sensitivity for diagnosis of asymptomatic compared to oligo- and symptomatic dogs. Our results corroborate those reported by Mettler et al. (2005) that demonstrated low sensitivity of rK39 test in detecting asymptomatic dogs naturally infected by *L.* (*L.*) *infantum*.

Although the ELISA demonstrated a better performance compared to rK39 in the diagnosis of infected dogs, the technological expertise (i.e. training personnel) necessary to perform the dipstick tests and the requirement for specialized laboratory equipment are minimal compared to ELISA. Another advantage of dipstick tests is that the dog owners can see the results by themselves, which will contribute to a better working relationship between local communities and people carrying out the surveys. In addition, from the epidemiological point of view, a rapid test allows interventions to be implemented in real time. Furthermore, it can be used to confirm VL in dogs at veterinary clinics.

Finally, we believe that, even being less sensitive than the ELISA, the rK39 dipstick could be used as a screening tool by the Brazilian VL control program due to its simplicity and the possibility of eliminating infected dogs without any further delay.

References

Altman, D.G., 1991. Practical Statistics Approach for Medical Research. Chapman & Hall, London, United Kingdom.

Bern, C., Jha, S.N., Joshi, A.B., Thakur, G.D., Bista, M.B., 2000. Use of a recombinant [39K] dipstick test and the direct agglutination test in a setting endemic for leishmaniasis in Nepal. Am. J. Trop. Med. Hyg. 63, 153–157.

Burns, J.M., Shreffler, W.G., Benson, D.R., Ghalib, H.W., Badaró, R., Reed, S.G., 1993. Molecular characterization of a kinesin-related antigen of *Leishmania chagasi* that detects specific antibody in African and American visceral leishmaniasis. Proc. Natl. Acad. Sci. U.S.A. 90, 775–779.

Carvalho, S.F., Lemos, E.M., Corey, R., Dietze, R., 2003. Performance of recombinant [39K] antigen in the diagnosis of Brazilian visceral leishmaniasis. Am. J. Trop. Med. Hyg. 68, 321–324.

Da Costa, R.T., França, J.C., Mayrink, W., Nascimento, E., Genaro, O., Campos-Neto, A., 2003. Standardization of a rapid immunochromatographic test with the recombinant antigens K39 and K26 for the diagnosis of canine visceral leishmaniasis. Trans. R. Soc. Trop. Med. Hyg. 97, 678–682.

Deane, L.M., Deane, M.P., 1962. Visceral leishmaniasis in Brazil. Geographical distribution and transmition. Rev. Inst. Med. Trop. São Paulo 4, 149–212.

Deplazes, P., Smith, N.C., Arnold, P., Lutz, H., Eckert, J., 1995. Specific IgG1 and IgG2 antibody responses of dogs to Leismania infantum and other parasites. Parasite Immunol. 17, 451–458.

Guarga, J.L., Lucientes, J., Peirbáñez, M.A., Molina, R., Gracia, M.J., Castilho, J.A., 2000. Experimental infection of *Phlebotumus perniciosus* and determination of the natural infection rates of *Leishmania infantum* in dogs. Acta Tropica 77, 203–207.

Jelinik, T., Eichenlaub, S., Löscher, T., 1999. Sensitivity and specificity of a rapid immunochromatographic test for diagnosis of visceral leishmaniasis. Eur. J. Microbiol. Infect. Dis. 18, 669–670.

Leontides, L.S., Saridomichelakis, M.N., Billinis, C., Kontos, V., Koutinas, A.F., Galatos, A.D., Mylonakis, M., 2002. A cross-sectional study of Leismania spp. Infection in clinically healthy dogs with polymerase chain reaction and serology in Greece. Vet. Parasitol. 109, 19–27.

Mancianti, F., Gramiccia, M., Gradoni, L., Pieri, S., 1998. Studies on canine leishmaniasis control. 1. Evolution of infection of different clinical forms of canine leishmaniasis following antimonial treatment. Trans. R. Soc. Trop. Med. Hyg. 82, 566–567.

Mettler, M., Grimm, F., Capelli, G., Camp, H., Deplazes, P., 2005. Evaluation of enzyme linked immunosorbent assays, an immunofluorescent-antibody test, and two rapid tests (immunochromatographic-dipstick and gel tests) for serological diagnosis of symptomatic and asymptomatic *Leishmania* infections in dogs. J. Clin. Microbiol. 43, 5515–5519.

Mohebali, M., Taran, M., Zarei, Z., 2004. Rapid detection of *Leishmania infantum* infection in dogs: comparative study using an immunochromatographic dipstick [39rK] test and direct agglutination. Vet. Parasitol. 121, 239–245.

Molina, R., Amela, C., Nieto, J., San-Andres, M., Gonzalez, F., Castillo, J.A., Lucientes, J., Alvar, J., 1994. Infectivity of dogs naturally infected with *Leishmania infantum* to colonized *Phlebotomus perniciosus*. Trans. R. Soc. Trop. Med. Hyg. 88, 491–493.

Otranto, D., Paradies, P., Sasanelli, M., Spinelli, R., Brandonisio, O., 2004. Rapid immunochromatographic test for serodiagnosis of canine leishmaniasis. J. Clin. Microbiol. 42, 2769–2770.

Palatinik-de-Souza, C.B., dos Santos, W.R., França-Silva, J.C., Da Costa, R.T., Reis, A.B., Palatinik, M., Mayrink, W., Genaro, O., 2001. Impact of canine control on the epidemiology of canine and human visceral leishmaniasis in Brazil. Am. J. Trop. Med. Hyg. 65, 510–517.

Reithinger, R., Quinnell, R., Alexander, B., Davies, C.R., 2002. Rapid detection of *Leishmania infantum* infection in dogs: comparative study using an immunochromatographic dipstick test, enzyme-linked immunosorbent assay, and PCR. J. Clin. Microbiol. 40, 2352–2356.

Sundar, S., Reed, S.G., Singh, V.P., Kumar, P.C., Murray, H.W., 1998. Rapid accurate field diagnosis of Indian visceral leishmaniasis. Lancet 351, 563–565.

Toz, S.O., Chang, K.P., Ozbel, Y., Alkan, M.Z., 2004. Diagnostic value of rK39 dipstick in zoonotic visceral leishmaniasis in Turkey. J. Parasitol. 90, 1484–1486.

Vieira, J.B.F., Coelho, G.E., 1998. Leishmaniose visceral ou calazar: aspectos epidemiológicos e de controle. Rev. Soc. Brás. Med. Trop. 31 (Suppl. II), 85–92.

Zijlstra, E.E., Daifalla, N.S., Kager, P.A., Khalil, E.A., El-Hassan, A.M., Reed, S.G., Ghalib, H.W., 2001. Diagnosing visceral leishmaniasis with the recombinant K39 strip test: experience from Sudan. Trop. Med. Int. Health 6, 108–113.

ANEXO-29

TG-ROC analysis of immunofluorescence assays in canine visceral leishmaniasis diagnosis

Silva, R.M.; **Laurenti, M.D.;** de Castro Gomes, A.; Nogueira, Y.L.

Revista de Saúde Pública 2009; 43(6): 1-9

Rev Saúde Pública 2009;43(6)

Rita Maria da Silva[I]

Márcia Dalastra Laurenti[II]

Almério de Castro Gomes[III]

Yeda Lopes Nogueira[IV]

TG-ROC analysis of immunofluorescence assays in canine visceral leishmaniasis diagnosis

ABSTRACT

OBJECTIVE: To analyze the accuracy of the diagnosis of two protocols of indirect immunofluorescence assays for canine visceral leishmaniasis.

METHODS: Dogs from the seroepidemiological survey conducted in an endemic area of the cities of Araçatuba and Andradina, in Northwestern São Paulo state, in 2003, and in a non-endemic area of the metropolitan region of São Paulo, were used to assess two protocols of indirect immunofluorescence assay (IFA) for leishmaniasis: one using a *Leishmania major* heterologous antigen (IFA-BM) and another using a *Leishmania chagasi* homologous antigen (IFA-CH). Two-graph receiver operating characteristic (TG-ROC) analysis was used to estimate accuracy. TG-ROC analysis compared 1:20 dilution readings of the homologous antigen (IFA-CH), considered as reference test, with IFA-BM dilutions (heterologous antigen).

RESULTS: The 1:20 dilution used in the IFA-CH test showed the best contingency coefficient (0.755) and the highest strength of association between the two variables studied (chi-square=124.3). Thus, it was considered the test reference dilution in comparisons with different IFA-BM test dilutions. The best IFA-BM results were obtained from 1:40 dilutions with the best contingency coefficient (0.680) and highest strength of association (chi-square=80.8). With the change in the cut-off point, recommended for the IFA-BM 1:40 dilution in this analysis, the specificity parameter value rose from 57.5% to 97.7%, even though the 1:80 dilution showed the best sensitivity estimate (80.2%), with the new cut-off point.

CONCLUSIONS: TG-ROC analysis can provide important information about diagnostic tests, in addition to offering suggestions on cut-off points that can improve test sensitivity and specificity estimates and assessing these tests in terms of the best cost-benefit ratio.

DESCRIPTORS: Leishmaniasis, Visceral, diagnosis. Dogs. Fluorescent Antibody Technique. Diagnostic Techniques and Procedures. Sensitivity and Specificity. Seroepidemiologic Studies.

[I] Seção de Parasitologia. Divisão de Laboratórios Regionais. Instituto Adolfo Lutz. Rio Claro, SP, Brasil

[II] Departamento de Patologia. Faculdade de Medicina. Universidade São Paulo (USP). São Paulo, SP, Brasil

[III] Departamento de Epidemiologia. Faculdade de Saúde Pública. USP. São Paulo, SP, Brasil

[IV] Seção de Sorologia. Divisão de Biologia Médica. Instituto Adolfo Lutz. São Paulo, SP, Brasil

Correspondence:
Rita Maria da Silva
Instituto Adolfo Lutz – Rio Claro
Rua Dez, 152 – Consolação
13500-090 Rio Claro, SP, Brasil
E-mail: ritsilva@terra.com.br

Received: 4/22/2008
Revised: 10/1/2008
Approved: 2/4/2009

INTRODUCTION

American visceral leishmaniasis (AVL) affects 88 countries, with 90% of cases occurring in India, Bangladesh, Nepal, Sudan and Brazil.[a]

In Brazil, AVL is considered endemic in 19 states, especially in the Northeast region, where a higher number of cases are reported and transmission patterns have changed.

At first, this disease was considered predominantly rural and peri-urban. Nowadays, it has been recorded in major urban centers such as Rio de Janeiro, Belo Horizonte, Araçatuba, Southeastern Brazil, and Corumbá, Central-West Brazil.[10,b,c]

In the state of São Paulo, the first report of the human disease's autochthony was made in the metropolitan area of São Paulo, in 1978.[10] However, at that time, it was not possible to identify the reservoir and vector in the links of transmission chain. In 1998, in the city of Araçatuba, the presence of *Leishmania sp.* was detected in direct parasitological examination of dogs with clinical suspicion of canine visceral leishmaniasis (CVL), subsequently identified as *Leishmania chagasi.* These facts, in addition to the presence of the vector insect, *Lutzomyia longipalpis*, notified in 1997, confirmed the autochthony of CVL in dogs living in the urban area of Araçatuba. In 1999, in this same city, the first autochthonous human case was reported.[b]

In general, official CVL surveillance and control programs recommend canine serological surveys should be made, aiming to know the disease's epidemiological situation in areas with active transmission or with potential transmission, with the concomitant identification of serologically positive dogs for subsequent destruction.[b,c] Studies emphasize the importance of test sensitivity and specificity parameters to assess the impact of destroying dogs, when compared to the serological methodology employed.[3] Studies assessing the results obtained from epidemiological surveys performed in Belo Horizonte,[1,2] using a kit obtained from the *Leishmania major* antigen, suggest that the use of indirect immunofluorescence assay (IFA) could compromise the effectiveness of the CVL Control Program. This is because IFA does not detect infected animals, due to false negative results, while it identifies non-infected dogs (false positive) with the resulting recommendation for destruction, according to the disease's Control Program.

The present study aimed to analyze the accuracy of two protocols of indirect immunofluorescence assays for canine visceral leishmaniasis.

METHODS

Tests were performed in two sample groups.

Group A was comprised of 94 serum samples of male and female dogs of different ages and breeds, of which 74 came from a seroepidemiological survey conducted in the cities of Araçatuba and Andradina, an endemic area in Northwestern São Paulo state.

A total of 20 seronegative dog samples from the city of São Paulo were added, an area considered to be without transmission at the time of collection (2003).

All dogs were assessed in terms of their clinical status, in addition to their having been serologically assessed for CVL diagnosis using IFA and direct parasitological examination. In this way, group A dogs were considered the reference population, of which 50 showed positive diagnosis, clinically classified as: symptomatic (30 dogs), oligosymptomatic (18 dogs) and asymptomatic (two dogs). There were 24 dogs with negative diagnosis that belonged to the endemic area and 20 that belonged to the non-endemic area.

Group B was comprised of 160 paired samples of serum and blood, collected on filter paper, from dogs belonging to the same cities and participating in the AVL serological surveys. A total of two IFAs were compared: one using promastigote *Leishmania major* forms (heterologous antigen), (IFA-BM, *Biomanguinhos, Fiocruz* – Oswaldo Cruz Foundation Immunobiological Technology Institute), and the other using promastigote *Leishmania chagasi* forms (homologous antigen) (IFA-CH, *Laboratório de Patologia de Doenças Infecciosas, Faculdade de Medicina da USP* – São Paulo University School of Medicine Laboratory of Infectious Disease Pathology). In both assays, samples were assessed semi-quantitatively, in 1:20, 1:40, 1:80 and 1:160 dilutions. Assays were performed in duplicate and samples were re-numbered, so that readings could be made as a blind test.

IFA readings were made in a fluorescence microscope with a magnification of x400, with the reading criterion adopted according to the density of fluorescent parasites and defined by a number of plus signs: 1+,

[a] World Health Organization. Tropical disease research: progress 2003-2004. Seventeenth Programme Report of the UNICEF/UNDP/World Bank/WHO Special Programme for Research & Training in Tropical Diseases. TDR 2005. Geneva; 2005. (Programme Report, 17). Disponível em: http://www.who.int/tdrold/publications/publications/pr17.htm

[b] Camargo-Neves VLF, Glasser CM, Cruz LL, Almeida RG. Manual de Vigilância e Controle de Leishmaniose Visceral Americana do Estado de São Paulo. São Paulo: Ministério da Saúde. Secretaria de Estado da Saúde; 2006.

[c] Ministério da Saúde. Departamento de Vigilância Epidemiológica. Secretaria de Vigilância em Saúde. Manual de Vigilância e Controle de Leishmaniose Visceral; 2006.

2+, 3+ and 4+, resulting in a score. This score was converted into percentages, so that the quantitative variable became continuous, thus enabling the use of the Two-Graph Receiver Operating Characteristics (TG-ROC) technique.[7] The reading[a] made with IFA-CH, which served as parameter for comparison: as a general rule, the microscope visual field was divided into four quadrants, each filled with fluorescent parasites equivalent to 25% fluorescence or 1+. Frequency distribution analyses for each serum dilution versus clinical forms, calculating chi-square and contingency coefficients extracted from contingency tables, were made for each set of results obtained from IFA-BM and IFA-CH readings. MedCalc statistical package[b] was used for this analysis.

Cut-off point estimates, in addition to sensitivity and specificity parameters, positive and negative predictive values and effectiveness were obtained using graphic analysis, created by the CMDT statistical package[8]'s TG-ROC technique.[7]

RESULTS

The readings of the IFA-CH and IFA-BM[a] indicate the immunofluorescence reaction with the IFA-CH homologous antigen is more specific than that with the IFA-BM heterologous antigen, which shows a non-specific background reaction that usually prevents a correct reading.

Results found on Tables 1 and 2, referring to group A samples, show the distributions of readings of the clinical diagnosis variable versus the serum dilution variable in the different categories, in both assays (IFA-CH and IFA-BM).

Of all the samples analyzed from 94 group A serums, 95.4% (42/44) were non-reactive with IFA-CH, in 1:20, 1:40 and 1:80 dilutions, and 90.9% (40/44) in 1:160 dilution (Table 1), when results from both assays were compared. Yet, for IFA-BM, non-reactive results were: 36.3% (16/44) in 1:20 dilution, 50.0% (22/44) in 1:40 dilution, 56.8% (25/44) in 1:80 dilution, and 52.2% (23/41) in 1:160 dilution (Table 2). In addition, there was no specific correlation between the different stages of disease and distinct reaction reading fluorescence levels, once all clinical forms were distributed into all reading ranges, varying from < 25% (weakly positive) to 3+ (75%).

The IFA-CH 1:20 dilution (Table 1) showed the best contingency coefficient (0.755) and the highest strength of association between the two variables studied (chi-square = 124.3). In addition, it was considered the assay's reference dilution and used for the comparative study with different IFA-BM dilutions. For this assay, the best results were obtained with the 1:40 dilution, which showed the best contingency coefficient (0.680) and the highest strength of association (chi-square=80.8) (Table 2).

TG-ROC graphic analysis on Figure 1 shows the sensitivity and specificity parameter values, represented on the y axis, whereas the x axis shows the values of readings in plus signs, which were converted into percentages (values of cut-off points). TG-ROC graphic analysis compares the homologous antigen (IFA-CH) 1:20 dilution readings, considered as reference assay, with the readings of each heterologous antigen (IFA-BM) dilution (1:20, 1:40, 1:80 and 1:160) (Figure 1).

Figure 2 was constructed by applying the new cut-off point value of the 1:40 dilution (Figure 1B), established by the analysis of group A TG-ROC, to group B's canine population. All the 160 paired samples of serum and blood, collected on filter paper, had already been assessed in 1:40 dilution, once this dilution is recommended on the IFA-BM kit label. However, at this dilution, fluorescence-reactive results that showed 1+ or 25% fluorescence were not seen as positive, once the cut-off point considered was equal to 26.70%, thus >25%. Figure 2A shows that the estimates of sensitivity and specificity parameters were 98% and the new cut-off point was 39.5%. The same cut-off point procedure was performed with the same dogs, whose blood was collected on filter paper, with sensitivity and specificity values of 73% and new cut-off point value of 37.2% (Figure 2B).

Table 3 shows the new estimates of sensitivity and specificity values, positive and negative predictive values, effectiveness and IFA-BM incorrect classification, based on the cut-off point provided by the TG-ROC analysis and using the IFA-CH 1:20 dilution as reference. The new cut-off points shown on Figure 1 resulted from new values for sensitivity and specificity parameters.

DISCUSSION

The TG-ROC graphic analysis[7] enables the cut-off point value, associated with the combination of sensitivity and specificity parameters, to be found. In this way, the diagnostic assay accuracy allows the distinction between ill individuals and non-ill (healthy) individuals.

In the present study, the TG-ROC graphic analysis was applied to group A population, comparing two

[a] The readings of the immunoflorescence reaction on the microscope (x 400) can be seen in the online version of Revista de Saúde Pública, available from www.scielo.br/rsp

[b] Schoojans F. MedCalc statistic for biomedical research: software manual. Mariakerke: Medcalc Statistical Software; 1998.

diagnostic assays: one specific, using homologous antigens (IFA-CH), and the other using a heterologous antigen (IFA-BM). The best distinction between seronegative dogs (healthy) and seropositive dogs (probably ill) occurred with the IFA-CH 1:20 dilution, which showed the best contingency coefficient and chi-square (Table 1), whereas the 1:40 dilution was the one that best separated these two sub-populations for IFA-BM (Table 2).

In this way, the new cut-off point suggested at IFA-BM 1:20 and 1:40 dilutions (Figure 1), above 25% (1+), disregards 1+ results as positive, resulting in a negative character. In this case, with group A population, there is a significant difference between assays when their results are analyzed comparatively, without the cut-off point adjustment. This can be explained by the characteristics of cases near the cut-off point, which usually have low antibody titers and represents the range where cross-reactivity is usually observed. Studies that assessed the immunoenzymatic assay (ELISA), using different antigen extracts and including dogs from the CVL-endemic area, found the existence of cross-reactions with other parasitic diseases (Chagas' disease, dirofilariasis and babesiosis), with both *L. chagasi* homologous antigen and *L. amazonensis* heterologous antigen. However, when recombinant rk-39 and rk-26 antigens were used, no cross-reactivity was observed.[15] Another study[5] showed the occurrence of cross-reactions when three serological methods for CVL were compared: IFA, ELISA, and direct agglutination test (DAT). After analyzing 234 dog samples in the endemic area of Minas Gerais, IFA and ELISA specificity indices were low, 52% and 64% respectively, showing cross-reactions with dog serums infected with *T. cruzi*, *L. braziliensis* and *E. canis*, whereas DAT specificity was high, 95%, showing only one animal with *E. canis*, seropositive for CVL. Likewise, in other studies performed in Corsega, in the Mediterranean Sea, authors found 100% specificity for DAT.[5,13] In contrast, there were yet other studies, using serum samples from dogs infected with *Babesia sp.* and from a dog with ehrlichiosis, that did now show cross-reactivity when samples were submitted to IFA for CVL.[16]

The best estimate for the specificity parameter value was found in the 1:40 dilution (Sp=97.7%), even though the 1:80 dilution shows the best sensitivity parameter estimate (Se=80.2%) (Table 3). These results show the possibility of choosing dilution cut-offs and making more adequate decisions for the cut-off point. As an example, the 1:40 dilution with a cut-off point higher than 26.7% shows the best specificity estimates and positive predictive value, preventing truly negative dogs from being destroyed. On the other hand, when the 1:80 dilution is selected, with better sensitivity index (80.2%) and lower specificity (79.5%),

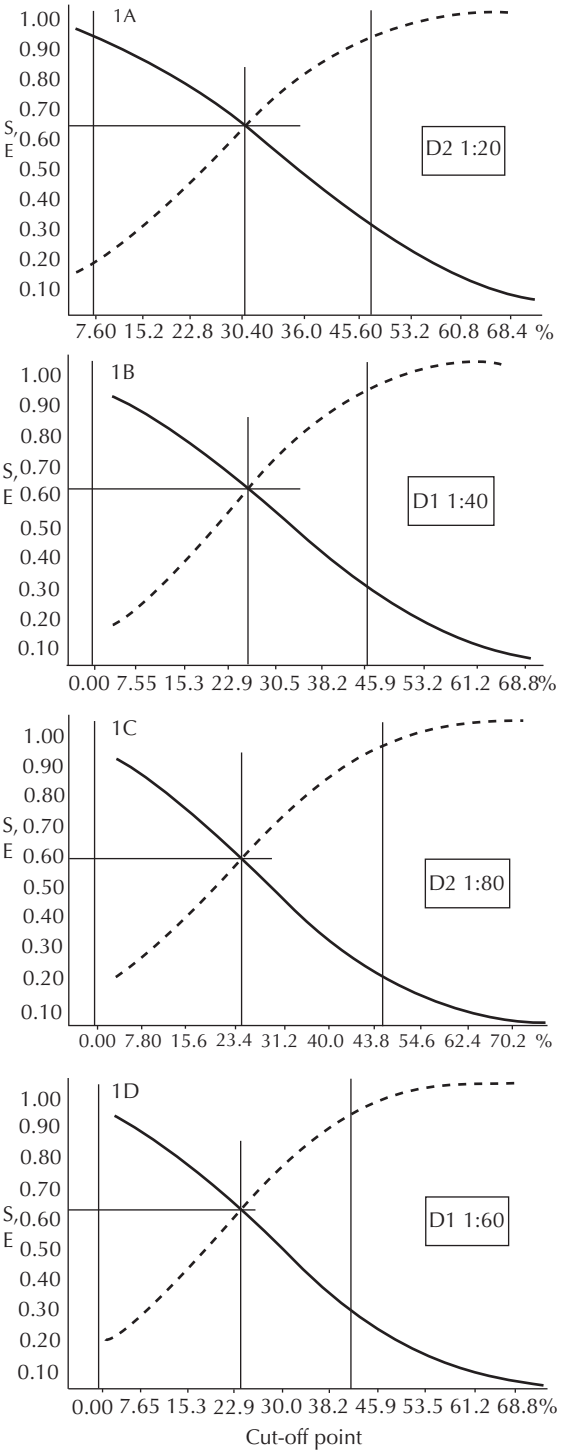

Figure 1. Sensitivity (- - -) and specificity (——) TG-ROC analysis after new cut-off point in IFA-CH and IFA-BM (group B samples). Andradina, Araçatuba and São Paulo, Southeastern Brazil, 2003.
Note: TG-ROC analysis was performed with a new standard of cut-off point found in the 1:40 dilution (cut-off point > 26.70%). 3A – Serum samples: cut-off point= 39.52% and values of Se=Sp= 98%. 3B – Blood samples collected on filter paper: Cut-off point= 37.20% and values of Se=Sp= 73%.

Table 1. Distribution of frequencies observed in the semi-quantitative IFA reading (1:20 to 1:160 dilutions) made with *L. chagasi* specific antigen, in group A dog serum samples, according to % of fluorescence and clinical diagnosis. Andradina, Araçatuba and São Paulo, Southeastern Brazil, 2003.

Clinical diagnosis	% of fluorescence																															
	1:20 dilution								1:40 dilution								1:80 dilution								1:160 dilution							
	0	<25	25	37	50	62	75	total	0	<25	25	37	50	62	75	total	0	<25	25	37	50	62	75	total	0	<25	25	37	50	62	75	total
Healthy	42	1	0	0	1	0	0	44	42	1	0	1	0	0	0	44	42	1	1	0	0	0	0	44	40	2	2	0	0	0	0	44
%	44,7	1,1	-	-	1,1	-	-	46,9	44,7	1,1	-	1,1	-	-	-	46,9	45,6	1,1	1,1	-	-	-	-	47,8	42,5	2,1	2,1	-	-	-	-	46,7
Symptomatic	0	3	9	3	12	2	1	30	0	5	9	3	12	0	1	30	2	8	7	5	5	0	2	29	4	13	2	4	6	1	0	30
%	-	3,2	9,6	3,2	12,8	2,1	1,1	33,0	-	5,3	9,6	3,2	12,8	-	1,1	32,0	2,1	8,6	7,5	5,4	5,4	-	2,1	31,1	4,2	13,8	2,1	4,2	6,4	1,1	-	31,9
Oligosymptomatic	0	3	4	2	8	1	0	18	1	4	2	4	6	1	0	18	2	6	4	2	3	1	0	18	5	2	6	3	2	0	0	18
%	-	3,2	4,2	2,1	8,5	1,1	-	19,1	1,1	4,2	2,1	4,2	6,4	1,1	-	19,1	2,1	6,4	4,3	2,1	3,2	1,1	-	19,2	5,3	2,1	6,4	3,2	2,1	-	-	19,1
Asymptomatic	0	0	0	0	0	2	0	2	0	0	0	0	1	1	0	2	0	0	0	0	2	0	0	2	0	0	1	0	1	0	0	2
%	-	-	-	-	-	2,1	-	2,1	-	-	-	-	1,1	1,1	-	2,2	-	-	-	-	2,1	-	-	2,1	-	-	1,1	-	1,1	-	-	2,2
Total	42	7	13	5	21	5	1	94	43	10	11	8	19	2	1	94	46	15	12	7	10	1	2	93	49	17	11	7	9	1	0	94
%	44,7	7,5	13,8	5,3	22,3	5,3	1,1	100,0	45,8	10,6	11,7	8,5	20,3	2,2	1,1	100,0	49,4	16,1	12,9	7,5	10,7	1,1	2,1	100,0	52,0	18,1	11,7	7,5	9,6	1,1	-	100,0
	p<0,0001								p<0,0001								p<0,0001								p<0,0001							
	Chi-square = 124,3								Chi-square = 114.7								Chi-square = 92.4								Chi-square = 72.7							
	Contingency coefficient = 0.755								Contingency coefficient = 0.741								Contingency coefficient = 0.706								Contingency coefficient = 0.660							

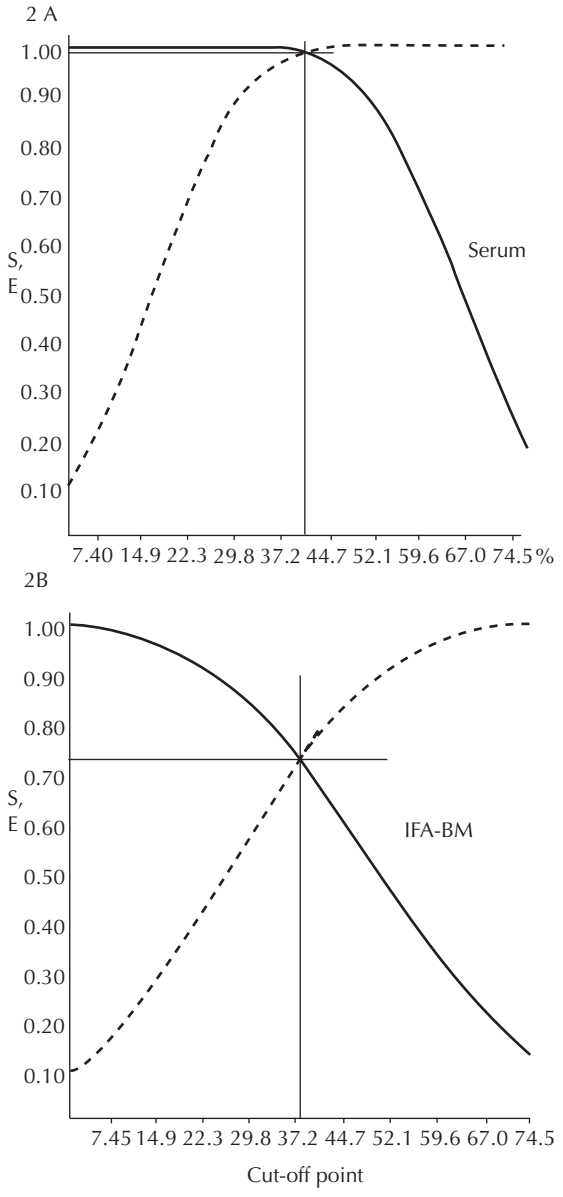

Figure 2. Sensitivity (- - -) and specificity (——) TG-ROC analysis after new cut-off point in IFA-CH and IFA-BM (group B samples). Andradina, Araçatuba and São Paulo, Southeastern Brazil, 2003.
Note: TG-ROC analysis was performed with a new standard of cut-off point found in the 1:40 dilution (cut-off point > 26.70%). 3A – Serum samples: cut-off point= 39.52% and values of Se=Sp= 98%. 3B – Blood samples collected on filter paper: Cut-off point= 37.20% and values of Se=Sp= 73%.

the positive predictive value also decreases (53.2%), increasing the possibility of healthy dogs being destroyed. Regardless, the decision to be made implies knowledge about the costs and benefits the selected cut-off point may offer.

Table 3 shows values for incorrect classification of about 20%, 18% and 17%, in 1:20, 1:40 and 1:80 dilutions, respectively, indicating that this parameter must also be assessed in combination with sensitivity and specificity. Comparison of results obtained in each of the IFA-BM dilutions with the IFA-CH (reference assay) 1:20 dilution shows that many serums did not show agreement, probably due to antigenic differences in the two antigens and the decrease in antibody avidity, or yet due to a question of equivalence zone of the antigen-antibody reaction between serums analyzed. Thus, a decrease in sensitivity in the 1:20 and 1:40 dilutions was observed, compared to 1:80 and 1:160 dilutions, which show the incorrect classification parameter of 11%. The choice of the 1:40 dilution with a cut-off point above 25% would be better, because, although the estimate of sensitivity is 68.3%, the confidence interval is within the 1:80 dilution confidence interval, which shows a specificity of 80.2%. In addition, in the 1:40 dilution, the specificity parameter estimate is the one that shows the highest value, 98.0%, and the incorrect classification varies very little between the two dilutions (0.18 and 0.17).

In the literature, some authors consider that the best IFA dilution cut-off is 1:80.[12,14,15] In the case of the IFA-BM, used in visceral leishmaniasis surveillance and control programs, the 1:40 dilution is usually recommended as dilution cut-off, although considering the 1+ reading as positive. Thus, the estimated sensitivity and specificity value of 57.50% results in a difference in specificity of almost 40% and, after reclassification, specificity was 97.50%.

Studies have observed high levels of sensitivity and specificity in serological tests used in canine surveys. Review studies[1] on CVL diagnosis with IFA show sensitivity values varying between 90% and 100% and specificity of 80% for serum samples. Other authors[12] indicated IFA sensitivity and specificity values of 98.4% and 100%, respectively.[11] Moreover, other studies compared serological sample results from 86 dogs with positive parasitological examination, in five laboratories that made CVL serological diagnosis, using IFA and ELISA. Sensitivity varied between 98.8% and 100% and specificity between 94.7% and 100% for IFA, while sensitivity varied between 98.8% and 100% and specificity between 96.5% and 100% for ELISA. Considering the similarity among the results of this study, there seems to be sampling bias, once test comparison is made using known serum panels, i.e. these studies do not use samples of populations from endemic and non-endemic areas, hindering the actual test assessment and causing an over-estimation of parameters.

However, actual sensitivity and specificity parameter values, observed on Figure 2 and Table 3, are closer to the values expected for dog populations that show the disease status homogenously distributed, i.e. ill individuals (symptomatic, oligosymptomatic and asymp-

Table 2. Distribution of frequencies observed in semi-quantitative IFA reading (1:20 and 1:160 dilutions) made with the kit, in group A dog serum samples, according to % of fluorescence and clinical diagnosis. Andradina, Araçatuba and São Paulo, SP, Brazil, 2003.

Clinical diagnosis	% of fluorescence																															
	1:20 dilution								1:40 dilution								1:80 dilution								1:160 dilution							
	0	<25	25	37	50	62	75	Total	0	<25	25	37	50	62	75	Total	0	<25	25	37	50	62	75	Total	0	<25	25	37	50	62	75	Total
Healthy	16	19	6	1	1	0	1	44	22	16	5	0	1	0	0	44	25	10	5	1	2	0	1	44	23	14	2	2	0	0	0	41
%	17,0	20,2	6,4	1,1	1,1	-	1,1	46,8	23,4	17,0	5,3	-	1,1	-	-	46,8	26,5	10,1	5,3	1,1	2,1	-	1,1	46,8	25,3	15,4	2,2	2,2	-	-	-	45,1
Symptomatic	0	1	9	6	9	2	3	30	0	1	10	7	7	1	4	30	1	3	12	4	7	1	2	30	0	5	12	2	7	1	3	30
%	-	1,1	9,6	6,4	9,6	2,1	3,2	32,0	-	1,1	10,6	7,5	7,5	1,1	4,2	32,0	1,6	3,2	12,8	4,2	7,5	1,1	2,1	32,0	-	5,5	13,2	2,2	7,2	1,1	3,3	33,0
Oligosymptomatic	0	0	4	3	6	2	3	18	0	1	4	4	6	1	2	18	0	4	6	2	5	1	0	18	0	2	6	4	4	1	1	18
%	-	-	4,2	3,2	6,4	2,1	3,2	19,1	-	1,1	4,2	4,2	6,4	1,1	2,1	19,1	-	4,2	6,4	2,1	5,3	1,1	-	19,1	-	2,2	6,6	4,4	4,4	1,1	1,1	19,8
Asymptomatic	0	0	0	0	1	0	1	2	0	0	0	2	0	0	0	2	0	0	0	2	0	0	0	2	0	0	1	1	0	0	0	2
%	-	-	-	-	1,1	-	1,1	2,2	-	-	-	2,1	-	-	-	2,1	-	-	-	2,1	-	-	-	2,1	-	-	1,1	1,1	-	-	-	2,2
Total	16	20	19	10	17	4	8	94	22	18	19	13	14	2	6	94	26	17	23	9	14	2	3	94	23	21	22	9	11	2	4	91
%	17,1	21,3	20,2	10,6	18,1	4,2	8,5	100,0	23,4	19,1	20,2	13,8	14,9	2,1	6,4	100,0	27,6	18,1	24,5	9,5	13,9	2,2	3,2	100,0	25,3	23,1	24,1	9,9	12,7	2,2	4,4	100,0
	p<0,0001								p<0,0001								p<0,0001								p<0,0001							
	Chi-square = 71.9								Chi-square = 80.8								Chi-square = 65.7								Chi-square = 66.8							
	Contingency coefficient = 0.654								Contingency coefficient = 0.680								Contingency coefficient = 0.641								Contingency coefficient = 0.651							

Table 3. IFA-BM results for dilutions with TG-ROC analysis cut-off points versus IFA-CH (group A samples) 1:20 dilution. Andradina, Araçatuba and São Paulo, SP, Brazil, 2003.

IFA-BM Cut-off points (x0)	Sensitivity	Specificity	Predictive value	Predictive value	Youden index	Incorrect classification
1:20 dilution	68.00	93.22	91.67	71.93	0.64	0.20
x0= 30.67%	(55.37;80.03)	(85.73;100.00)	(83.09;100.00)	(60.26;83.59)	(0.46;0.86)	
1:40 dilution	68.30	97.72	96.97	70.49	0.62	0.18
x0=26,70%	(55.37;80.03)	(93.32;100.00)	(91.12;100.00)	(59.04;81.93)	(0.47;0.76)	
1:80 dilution	80.20	79.54	53.19	77.77	0.60	0.17
x0= 24,17%	(68.91;91.08)	(67.62;91.46)	(43.10;63.27)	(65.63;89.92)	(0.44;0.76)	
1:160 dilution	88.46	47.61	72.64	76.92	0.36	0.11
x0=24,14%	(79.77;97.14)	(32.51;62.72)	(56.52;78.76)	(60.72;93.11)	(0.18;0.53)	

tomatic ones) and healthy individuals, as observed in group A population. On the other hand, group B population was comprised of a majority of truly positive dogs, showing sampling bias and, as a result, distorting sensitivity and specificity values. This fact usually occurs in studies performed with tests where non-random samples are used to assess diagnostic kits.

Another relevant question concerning the use of IFA-BM in serological surveys is their use in samples collected on filter paper. This assessment was made with group B serums (Figure 2). This group was comprised of paired samples of serum and filter paper, although the majority of cases showed strongly positive results, that is, IFA readings above 2+ (50%). In this way, TG-ROC analysis showed very high sensitivity and specificity estimate values (98%) for serum samples, whereas the referred values were 73% for blood samples on filter paper, indicating a 25% difference between serum use and filter paper. There are several studies comparing results of IFA performed in paired samples of serum and eluates. Some studies[2,4] report low values for the sensitivity parameter of IFA with eluate, when compared to the ELISA method with serum. On the other hand, different authors found high agreement of results of this assay in serum and eluate samples.[15]

These considerations are important when assessing diagnostic tests, especially as regards the sample used in the comparison. To avoid such bias, studies on validation of diagnostic tests[9] suggest guidelines on all variables that must be controlled to assess these tests.

In conclusion, the present study shows how TG-ROC analysis can provide important information about diagnostic tests, in addition to its offering suggestions on cut-off points that can improve the estimates of test specificity and sensitivity parameters and assess them in terms of the best cost and benefit. Finally, it provides more consistency when making decisions in the analyses of seroepidemiological survey results.

REFERENCES

1. Alves WA, Bevilacqua PD. Reflexões sobre a qualidade do diagnóstico da leishmaniose visceral canina em inquéritos epidemiológicos: o caso da epidemia de Belo Horizonte, Minas Gerais, Brasil, 1993-1997. *Cad Saude Publica*. 2004;20(1):259-65. DOI:10.1590/S0102-311X2004000100043
2. Ashford D, Badaro R, Eulalio C, Freire M, Miranda C, Zalis MG, et al. Studies on the control of visceral leishmaniasis: validation of the falcon assay screening test- enzyme-linked immunosorbent assay (FAST-ELISA) for field diagnosis of canine visceral leishmaniasis. *Am Soc Trop Med Hyg*. 2003;48(1):1-8.
3. Braga MDM, Coelho ICB, Pompeu MMLP, Evans TG, MacAullife IT, Teixeira MJ, et al Controle do calazar canino: comparação dos resultados de um programa de eliminação rápida de cães sororreagentes por ensaio imuno-enzimático com outro de eliminação tardia de cães sororreagentes por teste de imunofluorescência indireta de eluato de papel filtro. *Rev Soc Bras Med Trop*. 1998;31(4):419-24. DOI:10.1590/S0037-86821998000500001
4. Evans TG, Vasconcelos IA, Lima JW, Teixeira JM, Mc Auliffe IT, Lopes UG, et al. Canine visceral leishmaniasis in northeast Brazil: assessment of serodiagnosis methods. *Am J Trop Med Hyg*. 1990;42(2):118-23.
5. Ferreira EC, Lana M, Carneiro M, Reis AB, Paes DV, Silva ES, et al. Comparison of serological assays for the diagnosis of canine visceral leishmaniasis in animals presenting different clinical manifestations. *Vet Parasitol*. 2007;146(3-4):235-41.
6. Gontijo CMF, Melo MN. Leishmaniose visceral no Brasil: quadro atual, desafios e perspectivas. *Rev Bras Epidemiol*. 2004; 7(3):338-49. DOI:10.1590/S1415-90X2004000300011
7. Greiner M. Two-graph receiver operating characteristics (TG-ROC): a Microsoft-EXCEL template for the selection of cut off values in diagnostic tests. *J Immunol Methods*. 1995;185(1):145-6.
8. Greiner M. Two-graph receiver operating characteristics (TG-ROC): update version supports optimisation of cut-off vallues that minimise overall misclassification costs. *J Immunol Methods*. 1996;191(1):93-4.
9. Greiner M, Gardner IA. Epidemiologic issues in the validation dianostic tests. *Prev Vet* Med. 2000;45(1-2):3-22.
10. Iversson LB, Camargo ME, Rocha e Silva EO, Chieffi PP, Barros JAC. Investigação epidemiológica de um caso de leishmaniose visceral autóctone da Grande São Paulo, Brasil. *Rev Saude Publica*. 1979;13:159-67. DOI:10.1590/S0034-89101979000200012
11. Machado JG, Moraes JRC, Costa RT, Nascimento E, Moreira EC. Comparação dos resultados dos métodos de imunofluorescência indireta e ELISA indireto no diagnóstico sorológico da leishmaniose visceral canina realizado pelos laboratórios de Belo Horizonte, MG, Brasil. *Vet Zootec*. 2007;14(1):47-51.
12. Mancianti F, Falcone ML, Gianelli C, Poli A. Comparison between an enzyme-linked immunosorbent assay using a detergent-soluble Leishmania infantum antigen and indirect immunofluorescence for diagnosis of canine leishmaniasis. *Vet Parasitol*. 1995;59(1):13-21.
13. Neogy AB, Vouldoukis I, Silva AO, Tselentis Y, Lascombe JC, Segalen T, et al. Serodiagnosis and screening of canine visceral leishmaniasis in na endemic area of Corsica: applicability of a direct agglutination test and immunoblot analysis. *Am J Trop Med Hyg*. 1992;47(6):772-7.
14. Nogueira YL. Estimativa de validade de um novo método de isolamento de vírus rábico. *Rev Saude Publica*. 2004;38(2):315-22. DOI:10.1590/S0034-89102004000200023
15. Rosário EY, Genaro O, França-Silva JC, Costa RT, Mayrink W, Reis AB, et al. Evaluation of enzyme-linked immunosorbent assay using crude Leishmania and recombinant antigens as a diagnostic marker for canine for visceral leishmaniasis. *Mem Inst Oswaldo Cruz*. 2005;100(2):197-203. DOI:10.1590/S0074-02762005000200015
16. Vercammen F, Berkvens D, Le Ray D, Jacquet D, Vervoort T. Development of a slide ELISA for canine leishmaniasis and comparison with four serological tests. *Vet Rec*. 1997;141(13):328-30.

This article underwent the peer review process adopted for any other manuscript submitted to this journal, with anonymity guaranteed for both authors and reviewers. Editors and reviewers declare that there are no conflicts of interest that could affect their judgment with respect to this article.
The authors declare that there are no conflicts of interest.

ANEXO-30

Correlação entre o diagnóstico parasitológico e sorológico na leishmaniose visceral americana canina

Laurenti, M.D.

Boletim Epidemiológico Paulista - BEPA 2009; 6(67): 1-8

Bepa 2009;6(67):13-23

Artigo de revisão

Correlação entre o diagnóstico parasitológico e sorológico na leishmaniose visceral americana canina

Correlation between parasitological and serological diagnosis in canine american visceral leishamaniasis

Márcia Dalastra Laurenti

Laboratório de Patologia de Moléstias Infecciosas (LIM-50). Departamento de Patologia. Faculdade de Medicina da Universidade de São Paulo, SP, Brasil

RESUMO

Realizou-se uma minirrevisão sobre os estudos que correlacionam o diagnóstico parasitológico e sorológico para a leishmaniose visceral americana (LVA) canina, correlacionando também os achados diagnósticos com o estado clínico do reservatório doméstico. Além disso, discute-se a sensibilidade e especificidade de cada método e o antígeno utilizado; a aplicabilidade de cada técnica, em especial as sorológicas, para a utilização em programas de vigilância e controle da LVA.

PALAVRAS-CHAVE: diagnóstico laboratorial; leishmaniose visceral americana; reservatório doméstico; sorologia.

ABSTRCT

A brief revision on the studies that correlate parasitic and serologic diagnosis was performed for canine american visceral leishmaniasis (LVA), also correlating diagnostic findings with the clinic state of the domestic reservoir. More than that, the sensitiveness and the specificity of each method is discussed as well as the antigen employed; application of each technique, especially serologic ones, for use in the Surveillance and prevention control program for LVA.

KEY WORDS: laboratory diagnosis ; american visceral leishmaniasis; domestic reservoir; serology.

INTRODUÇÃO

Atualmente, no Brasil, a leishmaniose visceral americana (LVA) apresenta caráter endêmico-epidêmico, com média anual de 3 mil a 4 mil casos novos, distribuídos desde Roraima até o Paraná. Considerada doença predominantemente rural, nas últimas décadas a LVA vem sofrendo processo de urbanização, no qual cidades de médio ou grande porte têm sido acometidas por verdadeiras epidemias, como é o caso de Santarém (PA), São Luiz (MA), Teresina (PI), Natal (RN), Aracajú (SE), Montes Claros e Belo Horizonte (MG) e Corumbá (MS).[1] Essa mudança no padrão de transmissão da doença deve-se principalmente à urbanização do vetor, à participação do cão como reservatório doméstico da *L. (L.) chagasi* e à degradação ambiental, juntamente com o processo migratório da população para os grandes centros urbanos.

No Estado de São Paulo, a presença de *Leishmania sp* em exame parasitológico direto de cães com suspeita clínica de LVA foi detectada, em 1998, no município de Araçatuba, sendo posteriormente identificada como *L. (L.) chagasi*. Esse fato, aliado à presença do inseto transmissor, *Lutzomyia longipalpis*, detectado em 1997, confirmou a autoctonia de LVA em cães em território paulista.[2] Em 1999, no mesmo município, foi relatado o primeiro caso humano autóctone no Estado.[2]

Os programas de vigilância e controle de LVA[3,4] preconizam a realização de inquéritos sorológicos caninos, visando conhecer a situação epidemiológica da doença nas áreas com transmissão ativa ou com potencial de transmissão e, ao mesmo tempo, identificar os cães sorologicamente positivos para posterior eliminação. Entretanto, BRAGA e colaboradores[5] enfatizam a importância dos parâmetros sensibilidade e especificidade dos testes diagnósticos, quando avaliam o impacto da eliminação do cão frente à metodologia empregada.

A correlação entre o estado clínico do cão e sua infectividade para o flebotomídeo também deve ser considerada nas discussões para a adoção de medidas de controle da LVA canina, uma vez que PINELLI e colaboradores[6] observaram que animais assintomáticos e sintomáticos graves apresentavam respostas imunes, celulares e humorais bastantes distintas, favorecendo ou não a infecção do vetor. De qualquer forma, faz-se importante mencionar o trabalho de BARATA e colaboradores[7] que demonstraram a infecção do vetor, criado em laboratório, em cães soropositivos, apresentando diferentes formas clínicas da doença.

DIAGNÓSTICO PARASITOLÓGICO

O diagnóstico laboratorial da LVA canina baseia-se em métodos parasitológicos e sorológicos. Apesar de discordâncias entre alguns autores[8,9,10], o exame parasitológico é considerado, ainda, o teste ouro para o diagnóstico da doença. A observação direta de formas amastigotas do parasito em esfregaços de aspirado de linfonodo, medula óssea, baço, fígado, pele e sangue corados por Giemsa, Leishman ou Panótico® é uma forma segura, simples, rápida e pouco traumática para o diagnóstico da enfermidade (Figura 1).

A especificidade desse método é de 100%, mas a sensibilidade depende do grau do parasitismo, do tipo de material biológico coletado, do seu processamento e coloração, além do observador. A sensibilidade pode ser de 50% a 83% em amostras de medula óssea, entre 30% e 85% em amostras de linfonodo e

entre 71% a 91% quando ambos os tecidos estão combinados.[8,9] Quando o parasitismo é intenso não há problemas para um diagnóstico rápido e seguro; contudo, em muitos casos, especialmente em animais assintomáticos, nos quais apenas poucas formas amastigotas estão presentes nos tecidos, o diagnóstico parasitológico torna-se difícil e duvidoso. Esse problema pode ser solucionado com a utilização de técnicas mais sensíveis para a detecção de parasitos, tais como a imunofluorescência direta (RIFD) e a imunohistoquímica.

MOREIRA e colaboradores[10] compararam a RIFD com a pesquisa direta de parasitos em esfregaço de punção aspirativa de linfonodo poplíteo de cães de área endêmica de LVA. De 60 cães com sinais clínicos da doença, 30 foram positivos no exame direto, 22 suspeitos e 8 negativos; quando submetidos à RIFD, 56 mostraram-se positivos e 4 negativos. Os resultados mostraram que a RIFI apresentou alta sensibilidade quando comparada com a pesquisa direta de parasitos, sendo útil para confirmação dos casos suspeitos (Figura 2).

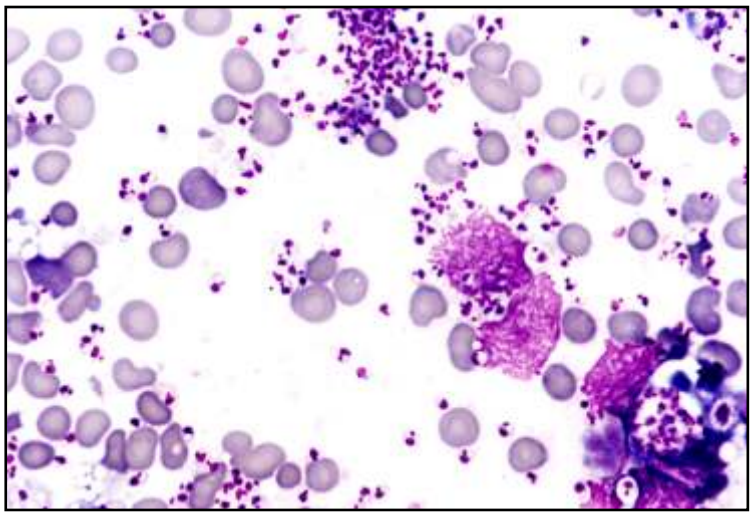

Figura 1. Esfregaço de material colhido por punção aspirativa em linfonodo poplíteo de cão sintomático, naturalmente acometido por leishmaniose visceral, mostrando formas amastigotas de *Leishmania* intracelulares e extracelulares coradas pelo Giemsa.

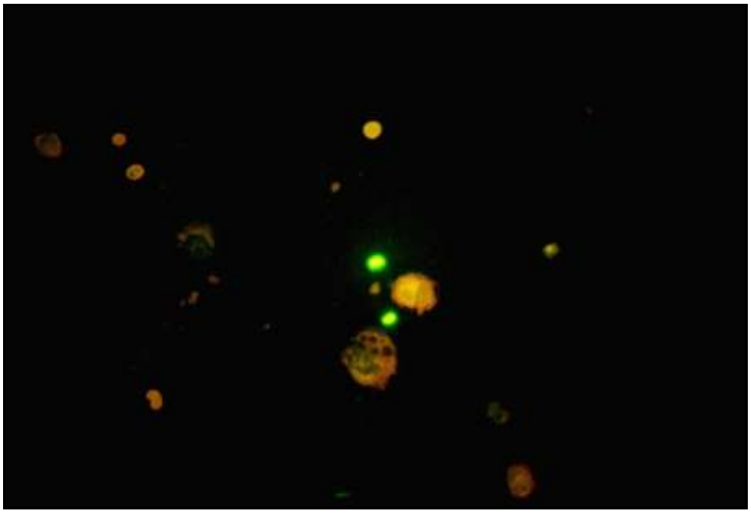

Figura 2. Reação de imunofluorescência direta positiva mostrando formas amastigotas do parasito em esfregaço de aspirado de linfonodo poplíteo de cão naturalmente acometido por leishmaniose visceral, marcadas pelo anticorpo policlonal anti-*Leishmania* conjugado com fluoresceína.

Técnicas de imunohistoquímica ou imunocitoquímica são métodos altamente sensíveis e específicos para a detecção de *Leishmania sp* em tecidos. Para tanto, pode-se utilizar qualquer tecido fixado e processado pelas técnicas usuais de microscopia, sendo que a pele, o fígado e os órgãos linfóides são os mais utilizados.

MOREIRA e colaboradores[10], trabalhando com cães com e sem sinais clínicos da doença e diagnóstico laboratorial positivo para LVA, mostraram que a detecção de parasitos por HE e imunohistoquímica foi mais eficiente em biópsias de linfonodo, quando comparado com os outros órgãos. Posteriormente, os autores, trabalhando com material obtido por meio de punção aspirativa de linfonodo poplíteo, mostraram que as técnicas de imunomarcação, tais como a imunofluorescência direta e a imunocitoquímica, aumentaram a sensibilidade para a detecção de parasitos e foram eficientes no diagnóstico de cães oligossintomáticos e assintomáticos (Figura 3).

O diagnóstico parasitológico pode também ser estabelecido por meio da detecção do parasito por cultivo em meios específicos. Biópsias ou punções aspirativas de diferentes órgãos ou tecidos são colocadas em meios de cultivo, em geral bifásicos (ágar sangue de coelho com LIT, RPMI ou Shineider), nos quais formas amastigotas do parasito, presentes no material biológico, transformam-se em formas promastigotas, podendo ser observadas em microscopia de contraste de fase (Figura 4).

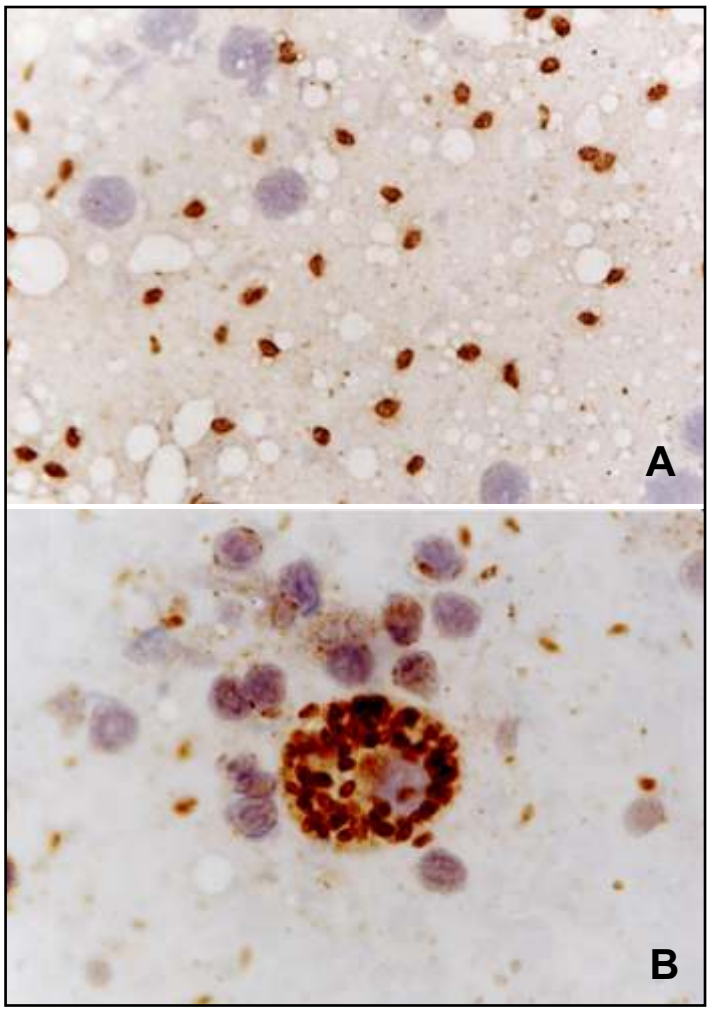

Figura 3. Reação de imunohistoquímica mostrando formas amastigotas de *Leishmania* extracelulares (A) e intracelulares (B) em esfregaço de aspirado de linfonodo poplíteo de cão naturalmente acometido por leishmaniose visceral.

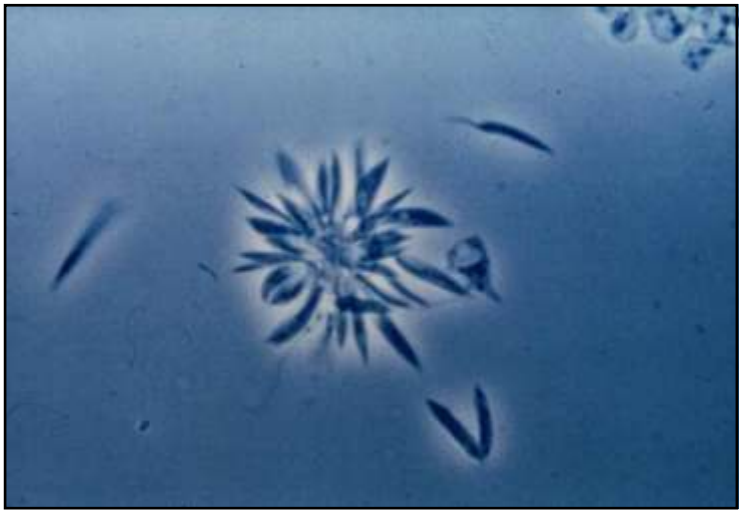

Figura 4. Formas promastigotas de *Leishmania* em meio de cultivo, observadas em contraste de fase.

O crescimento das formas promastigotas leva de 4 a 6 dias. Dessa forma, a leitura da cultura é feita semanalmente, sendo que após a terceira semana de observação o resultado final já é concluído. Como os meios de cultivo são ricos, a falta de adequação na esterilidade durante o processo da coleta de material e semeadura nos meios pode levar ao crescimento de bactérias e fungos que impedem o crescimento de *Leishmania*, diminuindo, assim, a sensibilidade do teste. Embora as culturas sejam úteis para o isolamento e identificação do parasito, são pouco utilizadas na rotina diagnóstica.

DIAGNÓSTICO SOROLÓGICO

A detecção de anticorpos circulantes anti-*Leishmania* utilizando técnicas sorológicas constitui um instrumento importante no diagnóstico da LVA canina. Animais doentes desenvolvem resposta imune humoral e produzem altos títulos de IgG anti-*Leishmania*.[8] A soroconversão ocorre aproximadamente três meses após a infecção.

Entretanto, os testes sorológicos devem ser interpretados com cautela, uma vez que não são 100% sensíveis e específicos e falham em detectar cães infectados no período pré-patente da doença.[11] Animais com menos de 3 meses de idade não devem ser avaliados por meio de métodos sorológicos, pois podem apresentar resultados positivos pela presença de anticorpos maternos.[5] Existem contradições na literatura quanto à possível correlação entre os títulos de anticorpos e a severidade dos sintomas.

Muitos testes sorológicos podem ser utilizados, tais como: fixação de complemento, aglutinação direta, imunofluorescência indireta (RIFI), imunoenzimático (Elisa) com diferentes modificações e western blot, entre outros.

Os testes sorológicos de RIFI e Elisa representam os principais instrumentos usados no sorodiagnóstico da LVA humana e canina, uma vez que são empregados nos programas nacional e estadual de vigilância e controle da LVA (PVCLVA)[3,4] para identificação de reservatórios infectados. Entretanto, apesar da doença estar associada, habitualmente, a apenas uma espécie de parasito, *L. (L.) chagasi* – o que, teoricamente, deveria facilitar a

padronização de um antígeno específico para ser usados nesses testes –, ainda hoje não existe um consenso na literatura especializada quanto ao emprego de um antígeno para o uso no sorodiagnóstico da LVA humana e canina.

Dependendo do antígeno empregado e das condições da RIFI, sua sensibilidade pode variar entre 90% e 100% e a especificidade, entre 80% a 100%[12,13] (Figura 5). A especificidade dessa prova, assim como de outras provas sorológicas, é prejudicada pela ocorrência de reações cruzadas com doenças, principalmente aquelas causadas por tripanosomatídeos, como o agente causador da doença de Chagas. Portanto, seus resultados não devem ser utilizados como indicadores de infecção leishmaniótica específica, particularmente em áreas onde a doença de Chagas é endêmica (Figura 5).

ZANETTE[14], trabalhando com 50 cães parasitologicamente positivos, mostrou sensibilidade de 98% e especificidade de 91% para a RIFI utilizando como antígeno promastigotas de *L. (L.) chagasi*, e ótima concordância com o diagnóstico parasitológico (Kappa=0,893). Com relação à ocorrência de reações cruzadas, o autor mostrou que 42,9% das amostras de soros de cães chagásicos foram reagentes para RIFI com antígeno de promastigotas de *L. (L.) chagasi*, assim como 50% das amostras de soros de cães com toxoplasmose. Não houve reação cruzada com erliquiose, babesiose e neosporose.

Na tentativa de otimizar os testes sorológicos empregados no programa de controle da leishmaniose visceral, SILVA[15] trabalhou com amostras de soro e papel de filtro colhidas de cães de área endêmica para LVA, com diagnóstico clínico e parasitológico positivo. A RIFI foi avaliada quantitativamente, pelo número de formas promastigotas marcadas, nas diluições de 1/20, 1/40, 1/80 e 1/160, utilizando-se o kit comercial produzindo por Biomanguinhos® e um ensaio *in house* utilizando promastigotas de *L. (L.) chagasi*. O ensaio *in house* com os soros mostrou-se capaz de separar todos os verdadeiros negativos dos verdadeiros positivos e apontou para uma eficiência de 60% a 76% para o kit comercial. Quando compadados os resultados da RIFI do kit comercial empregada em soros e papel de filtro, observou-se que o melhor ponto de corte para o papel de filtro seria a diluição de 1/80, o que seguramente diminuiria o número de falsos positivos.

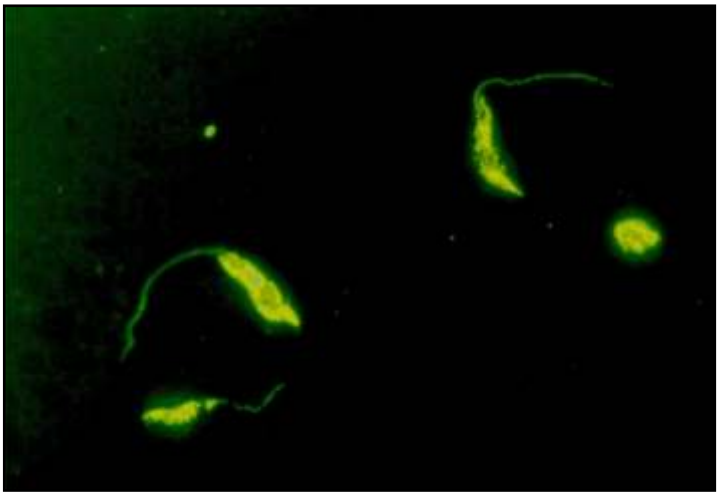

Figura 5. Reação de imunofluorescência indireta (RIFI) positiva mostrando formas promastigotas de *Leishmania* marcadas pela fluoresceína.

A comparação da reatividade entre as técnicas de RIFI e Elisa no sorodiagnóstico da LVA canina no Estado do Pará, utilizando amastigotas de *L. (L.) chagasi* preparadas no Instituto Evandro Chagas, por aposição de fragmentos de baço de hamster infectado cronicamente, e os kits da Biomanguinhos® mostrou soropositividade de 8,5% pela RIFI Biomanguinhos® e 0% pela RIFI com amastigotas, diferença estatisticamente significante. O Elisa Biomanguinhos® mostrou reação positiva em 4,2% das amostras ($p<0,05$). Considerando que na área estudada não há relatos da ocorrência de LVA humana e canina, ao contrário da situação da leishmaniose tegumentar americana, a qual tem elevada incidência, concluiu-se que o teste da RIFI utilizando amastigotas de *L. (L.) chagasi* como antígeno foi mais específico, pois não apresentou quaquer resultado falso positivo. É possível que as taxas de 8,5% e 4,2% de soropositividade obtidas com a RIFI e Elisa Biomanguinhos®, respectivamente, representem reações cruzadas de cães infectados com leishmânias dermatrópicas.[16]

O teste de Elisa pode apresentar, dependendo também do antígeno empregado, uma sensibilidade que varia entre 80% e 99,5% e uma especificidade entre 81% e 100%.[12,13] A sensibilidade e especificidade desse método dependem do tipo de antígeno empregado e de mudanças no protocolo. As técnicas que utilizam antígenos totais são limitadas em termos de especificidade, por apresentar reações cruzadas não somente com tripanosomatídeos, mas também com organismos filogeneticamente distantes.[14] A utilização de antígenos recombinantes ou purificados melhora a sensibilidade e a especificidade da técnica.[17]

MOREIRA e colaboradores[18], empregando antígeno específico, lisado total de formas promastigotas de *L. (L.) chagasi*, no ensaio de Elisa para o diagnóstico sorológico de cães positivos parasitologicamente, mostraram sensibilidade de 87,8% para cães sintomático, 68% para cães oligossintomáticos e 95,65% para assintomáticos, e especificidade de 100%. O Elisa mostrou boa correlação com o diagnóstico parasitológico, principalmente quando técnicas de imunomarcação foram utilizadas. Já ZANETE[14] mostrou sensibilidade de 94% e especificidade de 84,4% para o ensaio de Elisa, utilizando também antígeno específico em cães naturalmente infectados por *L. (L.) chagasi*, com boa concordância com o diagnóstico parasitológico (Kappa=0,788). Porém, prováveis reações cruzadas foram observadas com doença de Chagas (64,3%), erliquiose (7,7%) e co-infecção por erliquiose e babesiose (83,3%).

A utilização de antígenos recombinantes tem sido empregada por alguns grupos de pesquisa tanto no diagnóstico da leishmaniose visceral humana como canina. Há poucos estudos que relatam o uso de teste imunocromatográfico rápido anti-rK39 no diagnóstico da LVA canina em inquéritos caninos (Figura 6).

BADARÓ[19] mostrou sensibilidade de 99% com Elisa utilizando antígeno bruto e rK39 em soros de cães com LVA aguda. Em 467 soros coletados em inquérito canino realizado em área endêmica para LVA, somente os animais com rK39 positivo tinham evidência parasitológica de infecção por *Leishmania*. De acordo com os autores, esses resultados indicam que o antígeno rK39 pode ser usado como indicador da presença de LVA canina aguda.

Em estudo[20] realizado em Minas Gerais, com 1.798 cães, o desempenho do teste rápido anti-rK39 realizado em campo e no laboratório foi comparado. O TRALd em campo demonstrou sensibilidade de 85% e especificidade de 88%; já em laboratório, a sensibilidade foi de 92% e a especificidade foi de 94%, com aumento de valores preditivos frente ao diagnóstico parasitológico. GENARO e colaboradores[20],

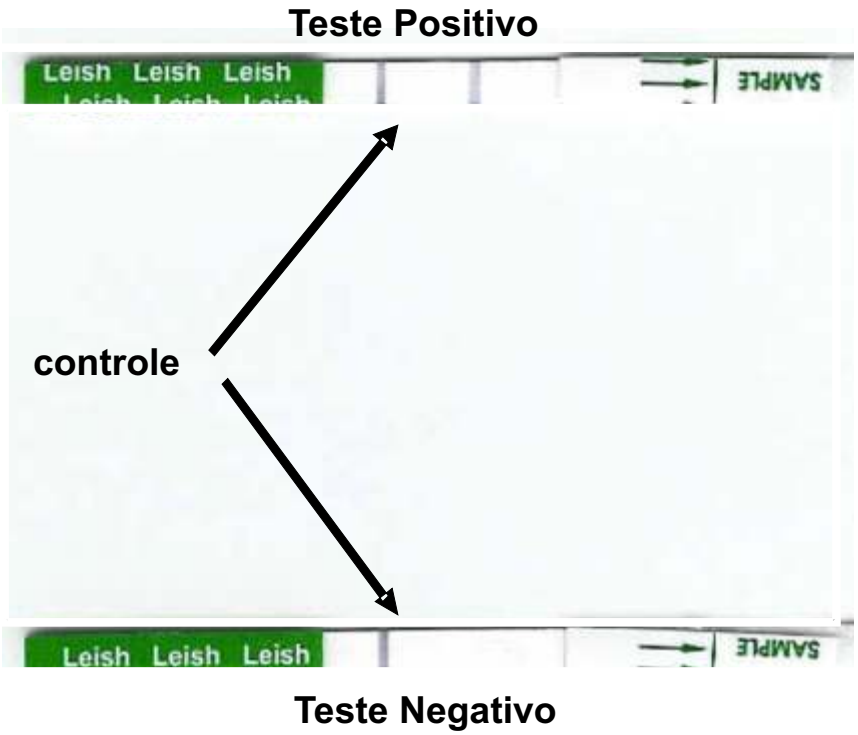

Figura 6. Imunocromatografia (Kalazar Detect Test) mostrando reação positiva e negativa para o antígeno rK39.

utilizando animais experimentalmente e naturalmente infectados por *L. (L.) chagasi*, mostraram que quando um animal é positivo para o TRALd, confirma o diagnóstico de infecção por *L. chagasi*, sendo que a sua utilização poderia gerar uma diminuição dos ani-mais sacrificados que apresentassem outras patologias.

Comparando-se a utilização do TRALd com o Elisa com antígeno bruto, concluiu-se que o teste cromatográfico anti-rK39 é capaz de detectar infecção ativa em cães com diferentes formas clínicas da doença, uma vez que a sensibilidade do TRALd foi de 83% com especificidade de 100%.[21]

ZANETTE[14] trabalhando com amostra de 50 soros de cães naturalmente acometidos por LVA, mostrou sensibilidade de 86% e especificidade de 91,1%. O teste imunocromatográfico apresentou uma boa concordância com o diagnóstico parasitológico (Kappa=0,769). Reações cruzadas foram observadas com erliquiose (7,7%), co-infecção por erliquiose e babesiose (50%), toxoplasmose (10%), neosporose (12,5%) e co-infecção toxoplasmose e neosporose (23%).

CONCLUSÃO

Depois de duas décadas de tentativas de controle da LVA no Brasil, o número de casos no País aumentou nitidamente e verifica-se a sua expansão para áreas urbanas.

Os programas brasileiros[3,4], iniciados há mais de 40 anos em algumas unidades federadas, são compostos pela integração de três medidas de saúde pública: diagnóstico precoce e tratamento, com a distribuição gratuita do medicamento específico; controle de reserva-

tórios domésticos; e controle vetorial. Como método diagnóstico da LVA canina os programas[3,4] adotam duas reações: Elisa e RIFI, produzidos por Biomanguinhos®. Estas são realizadas pelo Laboratório de Saúde Pública, em áreas de transmissão de LVA, a fim de detectar cães infectados, fonte de infecção para o vetor, para a realização da eutanásia e avaliação da prevalência da LVA canina.

Em relação aos métodos sorológicos empregados em inquéritos epidemiológicos, cujo objetivo é conhecer a prevalência da doença em áreas endêmicas ou com potencial de transmissão da LVA, os parâmetros de sensibilidade, especificidade e valores preditivos das técnicas sorológicas empregadas são de extrema importância para se evitar interpretações errôneas, com resultados falsos positivos ou negativos. Embora a sorologia seja apenas um método indireto de medir a infecção, não definindo o grau de parasitismo, a presença da doença ou ainda o potencial de transmissão que o cão possa ter para o vetor, diminuir o número de resultados falsos positivos e negativos seria muito importante para a eficiência do programa.

REFERÊNCIAS

1. Vieira JBF, Coelho GE. Leishmaniose visceral ou calazar: aspectos epidemiológicos e de controle. Rev Soc Bras Med Trop. 1988;31(II):85-92.
2. Camargo-Neves VLF, Katz G. Ações controle da leishmaniose visceral americana implementadas na região oeste do Estado de São Paulo. Rev Soc Bras Med Trop. 1999;32:63.
3. Camargo-Neves VLF, Glasser CM, Cruz LL, Almeida RG. Manual de Vigilância e Controle da Leishmaniose Visceral Americana do Estado de São Paulo. São Paulo: Secretaria de Estado da Saúde, 2006; 145p.
4. Ministério da Saúde. Manual de vigilância e controle da leishmaniose visceral 2003 [manual na internet]. Brasília: MS [acesso em junho 2006]. Disponível em: http://portal.saude.gov.br/portal/svs.
5. Braga MDM, Coelho ICB, Pompeu MML, Evans TG, Macaullife IT, Teixeira MJ et al. Controle do calazar canino: comparação dos resultados de um programa de eliminação rápida de cães sororreagentes por ensaio imuno-enzimático com outro de eliminação tardia de cães sororreagentes por teste de imunofluorescência indireta de eluato de papel filtro. Rev Soc Bras Med Trop. 1998;315 (5): 419-424.
6. Pinelli E, Killick-Kendrick R, Wagenaar J, Bernardina W, Del Real G, Ruitember GJ. Cellular and humoral Immune responsein dogs experimentally and naturally infected with *Leishmania infantum.* Infection and Immunity.1994;62:229-35.
7. Barata IR, Lima JA, Soares MG, Brandão JA, Pires RN, Corrêa ZC et al. The infectivity of dogs infected with *Leishmania chagasi* for *Lutzomyia longipalpis* is not related to clinical status or the humoral response of the animals. Third World

Congress on Leishmaniosis (Abstract Book), Palermo-Terrasini, Sicily, Italy; 2005, p.110.

8. Ferrer LM. Clinical aspects of canine leishmaniasis. In: Proceedings of the International Canine Leishmaniasis Forum. Barcelona, Spain. Canine Leishmaniasis: an update. Wiesbaden: Hoeschst Roussel Vet. 1999, p. 6-10.
9. Koutinas AF, Saridomichelakis MN, Mylonakis ME, Leontides L, Polizopoulou Z, Billinis C et al. A randomised, blinded, placebo-controlled clinical trial with allopurinol in canine leishmaniosis. Veterinary Parasitology. 2001;98:247-61.
10. Moreira MAB, Luvizotto MCR, Nunes CM, Silva TCC, Laurenti MD, Corbett CEP. Application of direct immunofluorescence technic for the diagnosis of canine visceral leishmaniaisis in lymph nodes aspierate. Braz J Vet Res Anim Sci. 2002;39(2):103-6.
11. Ferrer L, Aisa MJ, Roura X, Portús M. Serological diagnosis and treatment of canine leishmaniasis. Veterinary Record.1995;136:514-6.
12. Mancianti F, Falcone ML, Giannelli C, Poli A. Comparison between an enzyme-linked immunosorbent assay using a detergent-soluble *Leishmania infantum* antigen and indirect immunofluorescence for the diagnosis of canine leishmaniosis. Veterinary Parasitology. 1995;59:13-21.
13. Mancianti F, Pedonese F, Poli A. Evaluation of dot enzyme-linked immunosorbent assay (dot-ELISA) for the serodiagnosis of canine leishmaniosis as compared with indirect immunofluorescence assay. Veterinary Parasitology. 1996;65:1-9.
14. Zanette MF. Comparação entre os métodos de ELISA, imunofluorescência indireta e imunocromatografia para o diagnóstico da leishmaniose visceral canina [dissertação de mestrado]. Araçatuba (SP): Faculdade de Odontologia, Curso de Medicina Veterináriada Unesp; 2006.
15. Silva MR. Estudo comparativo entre os métodos de Elisa e IFI na análise de amostras de sangue de cães provenientes de municípios endêmicos e enzoóticos para LVC [tese de doutorado]. São Paulo: Faculdade de Saúde Pública da USP; 2005.
16. Jesus RCS, Corrêa ZC, Everdosa DR, Martins AP, Eliseu LS, Campos MB et al. Comparação das técnicas de RIFI (Ag.IEC X Ag. Biomanguinhos) e Elisa no sorodiagnóstico da leishmaniose visceral canina (LVC), estado do Pará, Brasil. Rev Soc Bras Med Trop. 2003;36(supl.I):323-4.
17. Scalone A, De Luna R, Oliva G, Baldi L, Satta G, Vesco G et al. Evaluation of the *Leishmania* recombinant k39 antigen as a diagnostic marker for canine leishmaniasis and validation of a standardized enzyme-linked immunosorbent assay. Veterinary Parasitology. 2002;104:275-85.
18. Moreira MAB, Luvizotto MCR, Garcia JF, Corbett CEP, Laurenti MD. Comparison of parasitological, immunological and molecular methods for the diagnosis of leishmaniasis in dogs with different clinical signs. Veterinary Parasitology. 2007;145(3-4)245-52.
19. Badaró R. Desenvolvimento e utilização de um antígeno recombinante específico de *Leishmania chagasi* (rK39) no diagnóstico sorológico da leishmaniose visceral [tese de doutorado]. São Paulo: Unifesp; 1996.
20. Genaro O, Costa RT, França Silva JC, Reis AB, Vieira EP, Arias JR. Evaluation of an

immunochromatographic assay for the diagnosis for dogs experimentally and naturally infected with *Leishmania chagasi* in Brazil. Acta Parasitologoca Turcica.1997;21(suppl.I): 93.

21. Laurenti MD, Lemos EM, Reis AB, Moreira MAB, Luvizotto MCR, Corbett CEP et al. Evaluation of Kalazar Detect™ Rapid Test for serodiagnosis of canine visceral leishmaniasis in Brazil. Third World Congress on Leishmaniosis (Abstract Book), Palermo-Terrasini, Sicily, Italy. 2005, p.160.

Recebido em: 15/03/2009
Aprovado em: 26/07/2009

Correspondência/correspondence to:
Márcia Dalastra Laurenti
Laboratório de Patologia de Moléstias Infecciosas.
Departamento de Patologia da Faculdade de Medicina da Universidade de São Paulo.
Av. Dr Arnaldo, 455; Cerqueira César CEP: 01246-903, São Paulo, SP, Brasil
Tel: 11- 3061-7426
mdlauren@usp.br

Resumo de palestra proferida no II Fórum de Discussão da Sociedade Paulista de Parasitologia: "Leishmaniose visceral americana, situação atual e perspectivas futuras". Organizado por Regina M. B. Franco, da Sociedade Paulista de Parasitologia, por Vera L. F. de Camargo-Neves e Cecília Abdalla, da Coordenadoria de Controle de Doenças da Secretaria de Estado da Saúde de São Paulo (CCD/SES-SP), realizado em 3 de julho de 2007, no auditório Luiz Mussolino/SES-SP.